

4. Epaissements tissulaires

- Epaissement diffus
 - DD bénin vs malin possible
 - DD malin primitif vs secondaire difficile

- Epaissement nodulaire isolé
 - DD bénin vs malin difficile

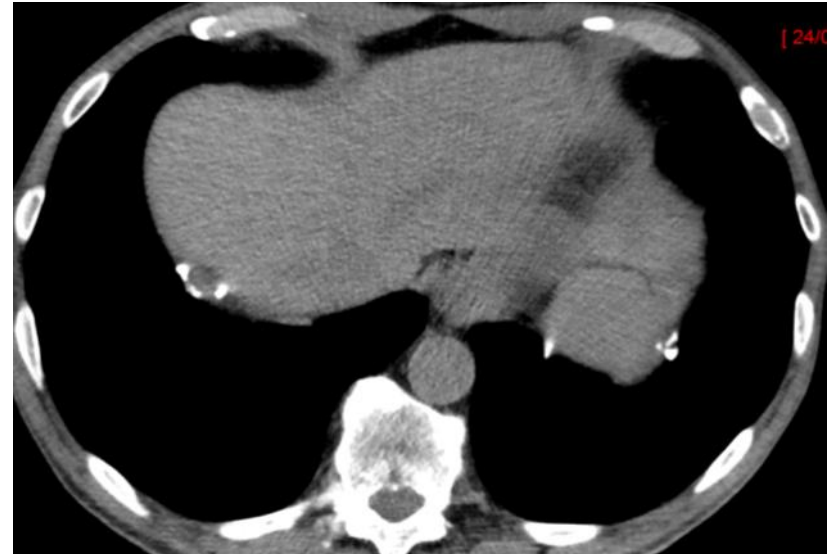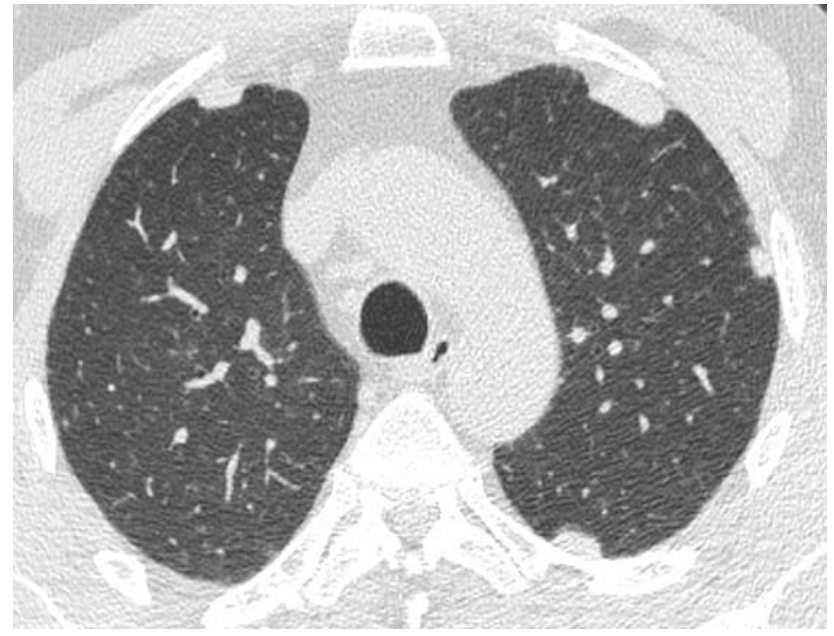
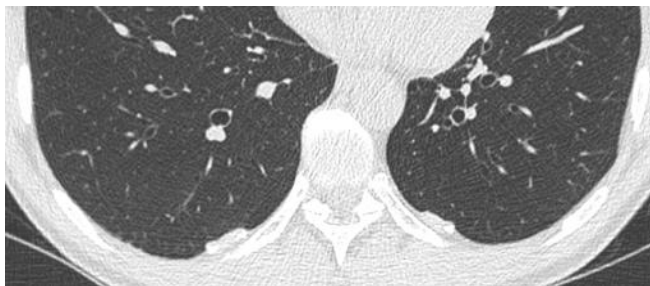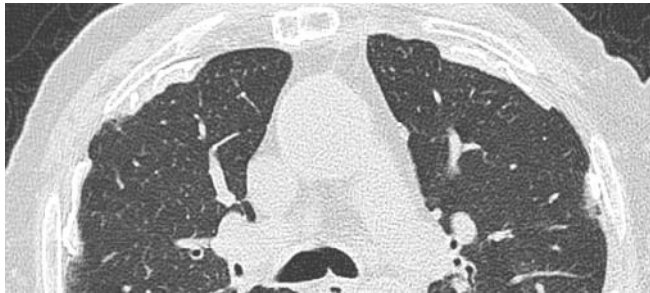
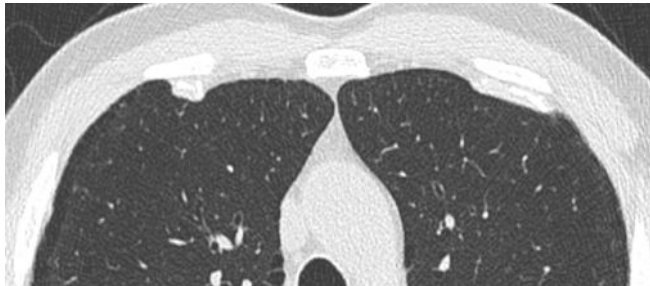
4A1. Epaissements tissulaires diffus bénins

Calcifications = bénin (99%)

- Discrètes ou extensives (os de seiche)
- Etiologies :
 - Séquelle d'hémothorax
 - Séquelle de pleurésie tuberculeuse
 - Exposition à l'amiante
 - Plaques pleurales
 - Séquelles de pleurésie asbestosique

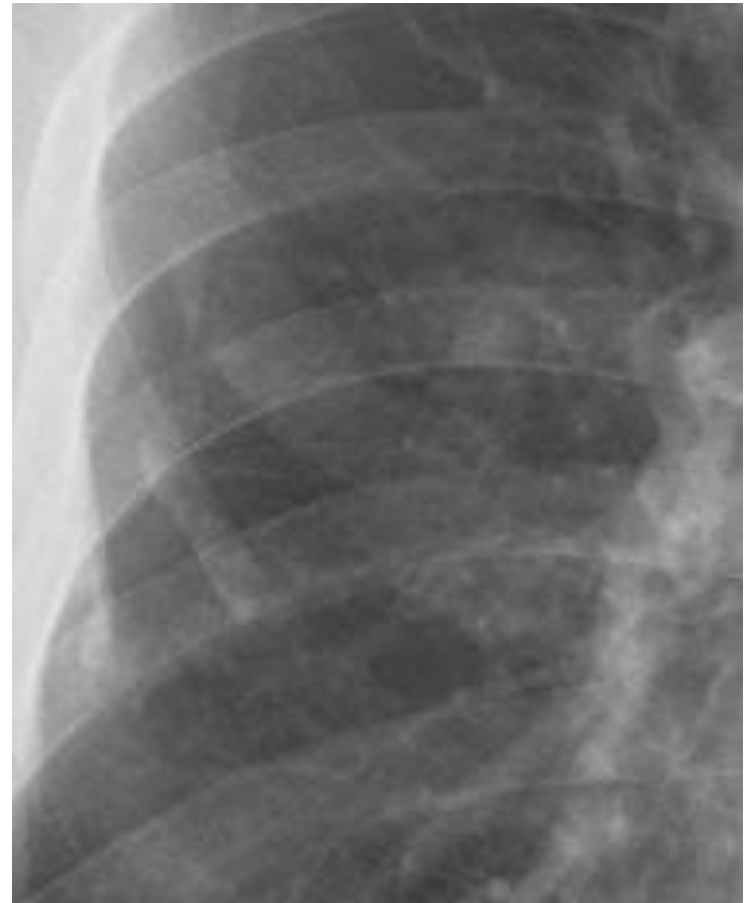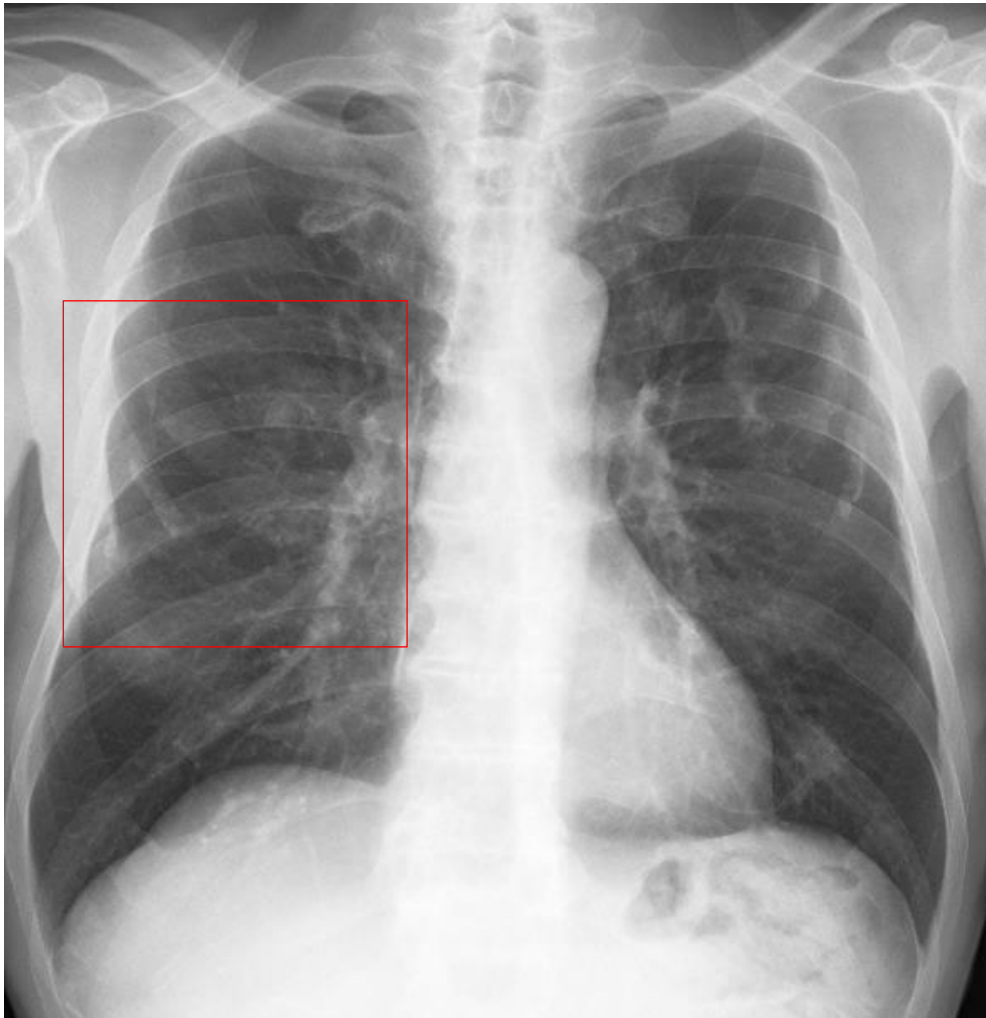
4A1. Epaissements tissulaires diffus bénins

Plaques pleurales (amiante)



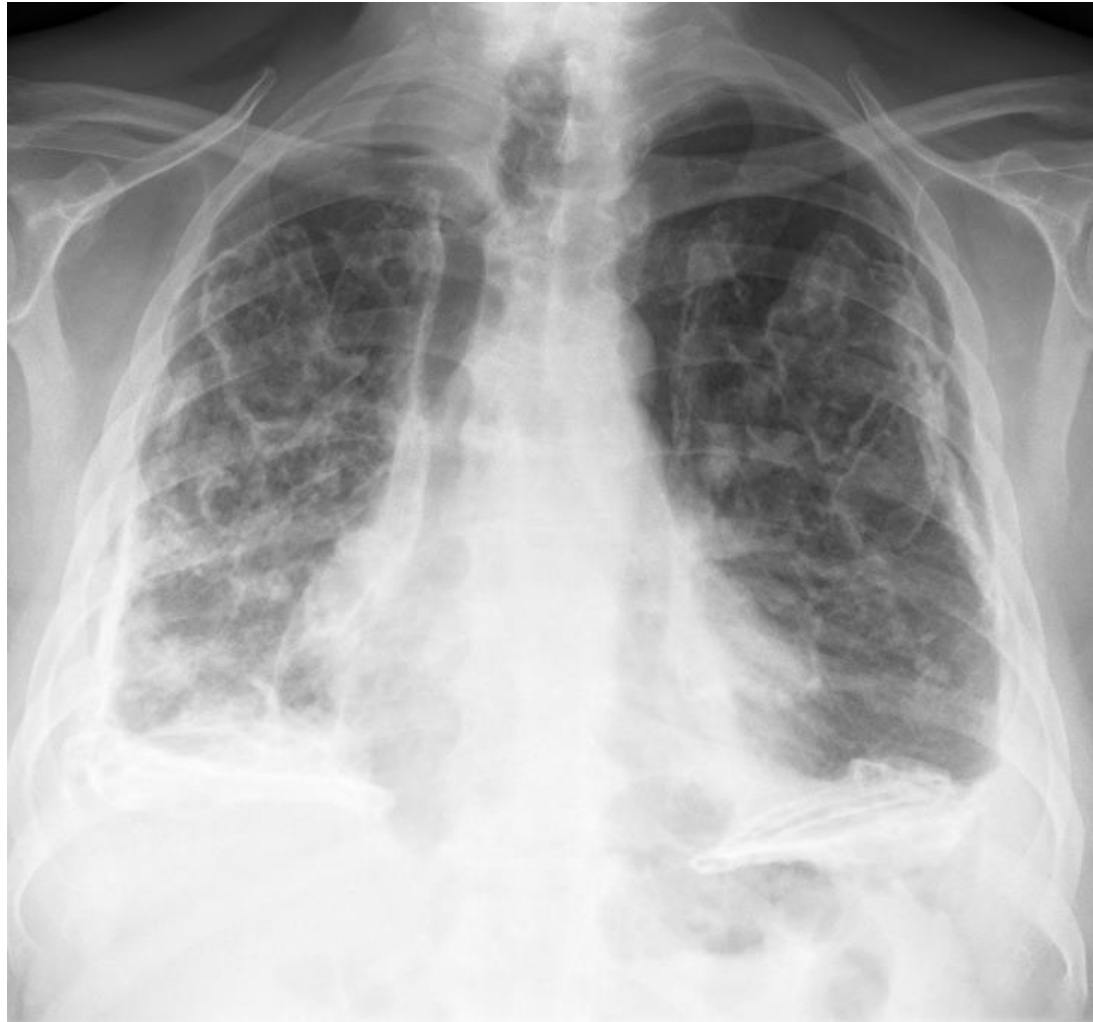4A1. Epaissements tissulaires diffus bénins

Plaques pleurales (amiante)



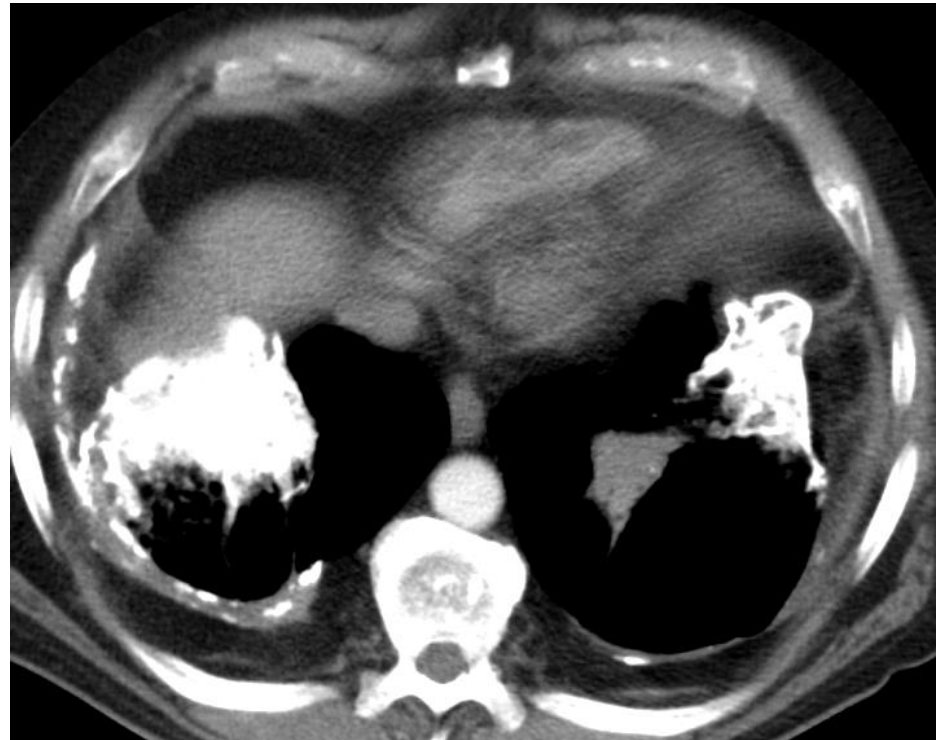
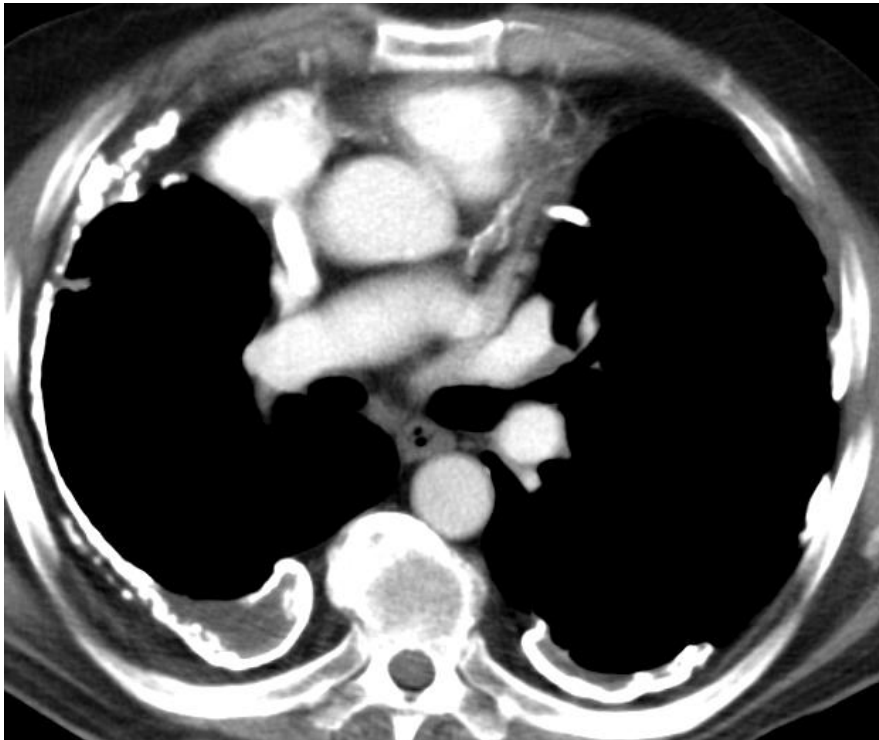
4A1. Epaissements tissulaires diffus bénins

Séquelles calcifiées extensives (fibrothorax) de TB



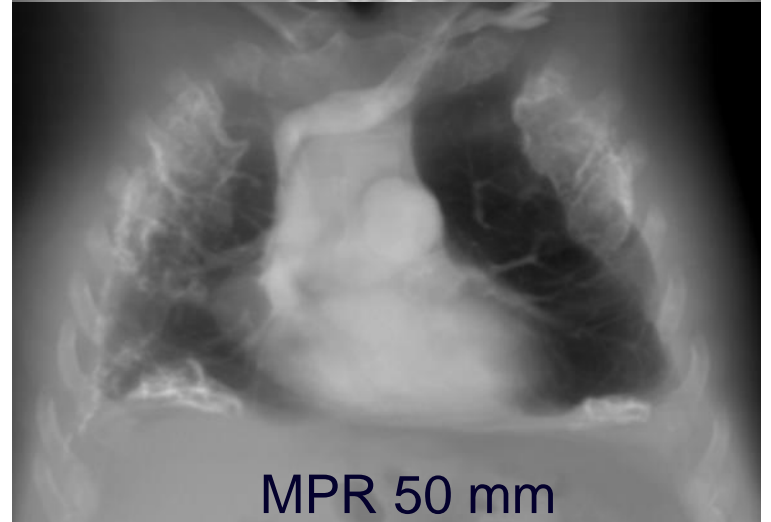
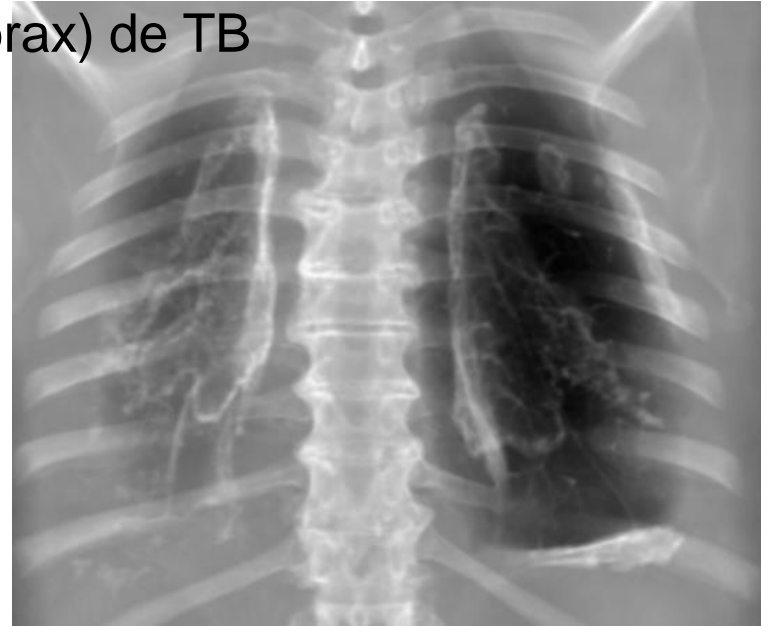
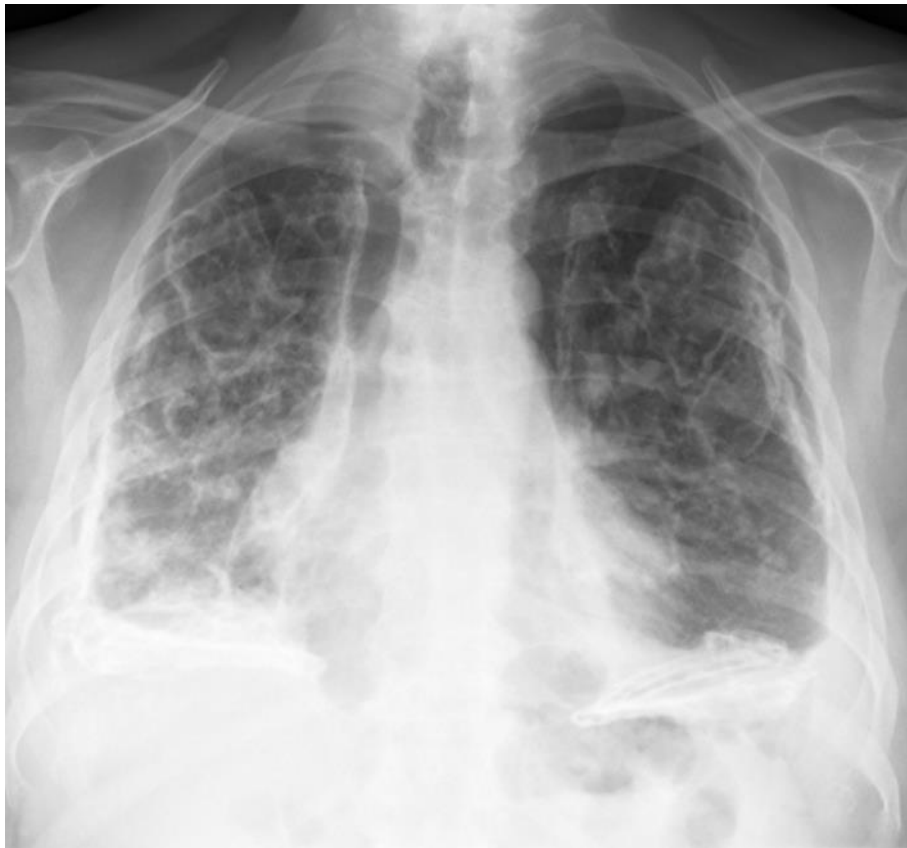4A1. Epaissements tissulaires diffus bénins

Séquelles calcifiées extensives (fibrothorax) de TB



4A1. Epaissements tissulaires diffus bénins

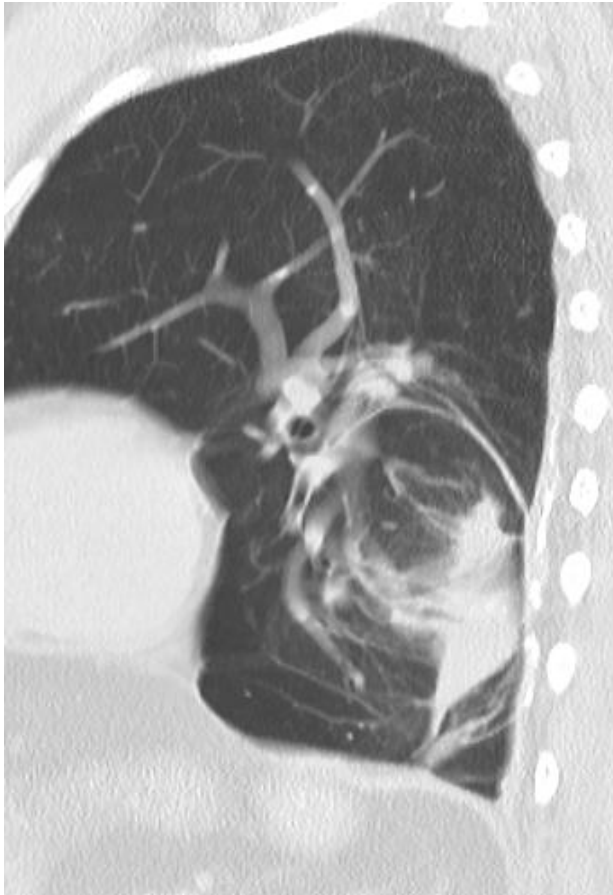Séquelles calcifiées extensives (fibrothorax) de TB



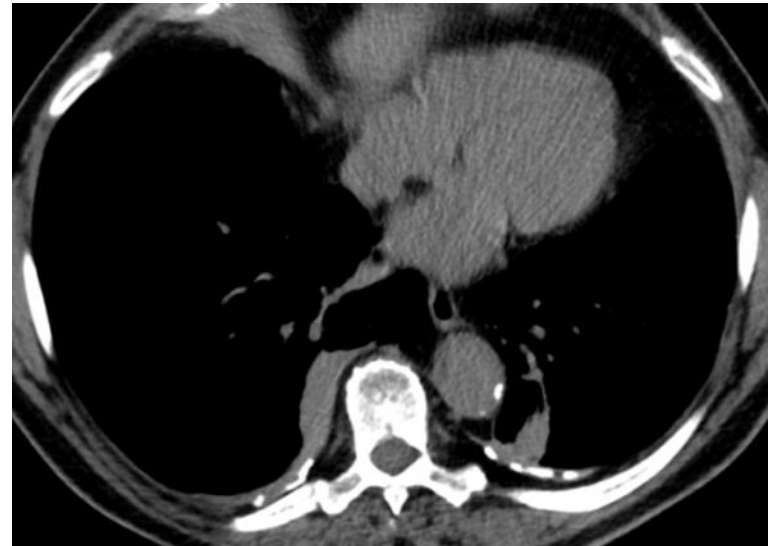
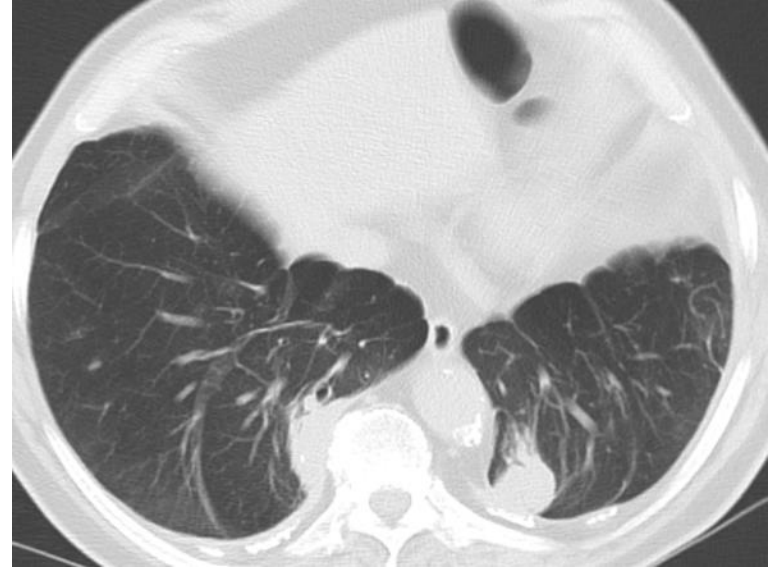MPR 50 mm

4A1. Epaissements tissulaires diffus bénins

Séquelles de pleurésie asbestosique

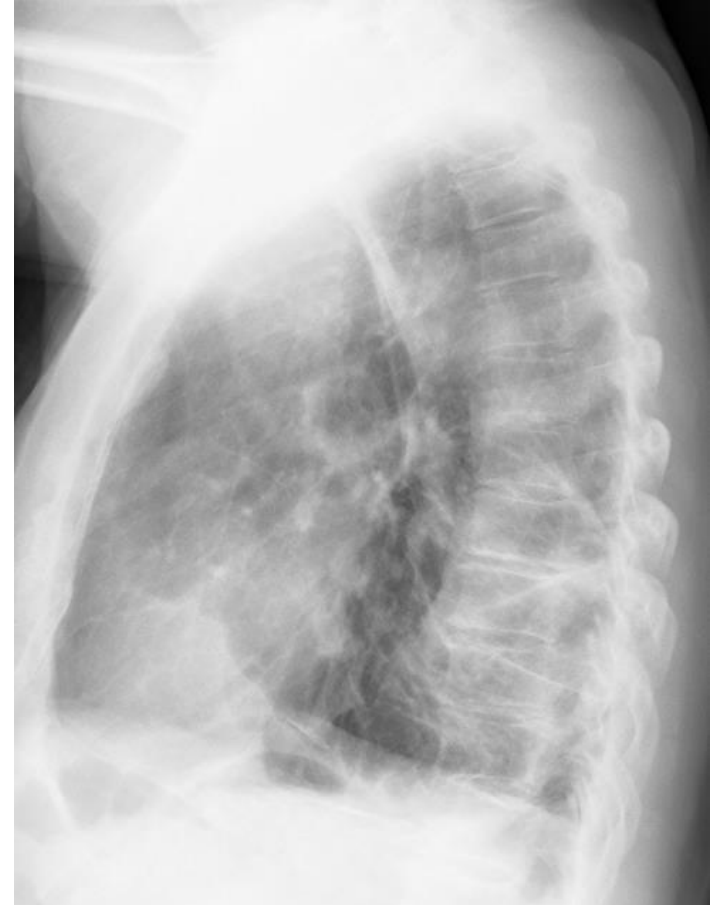
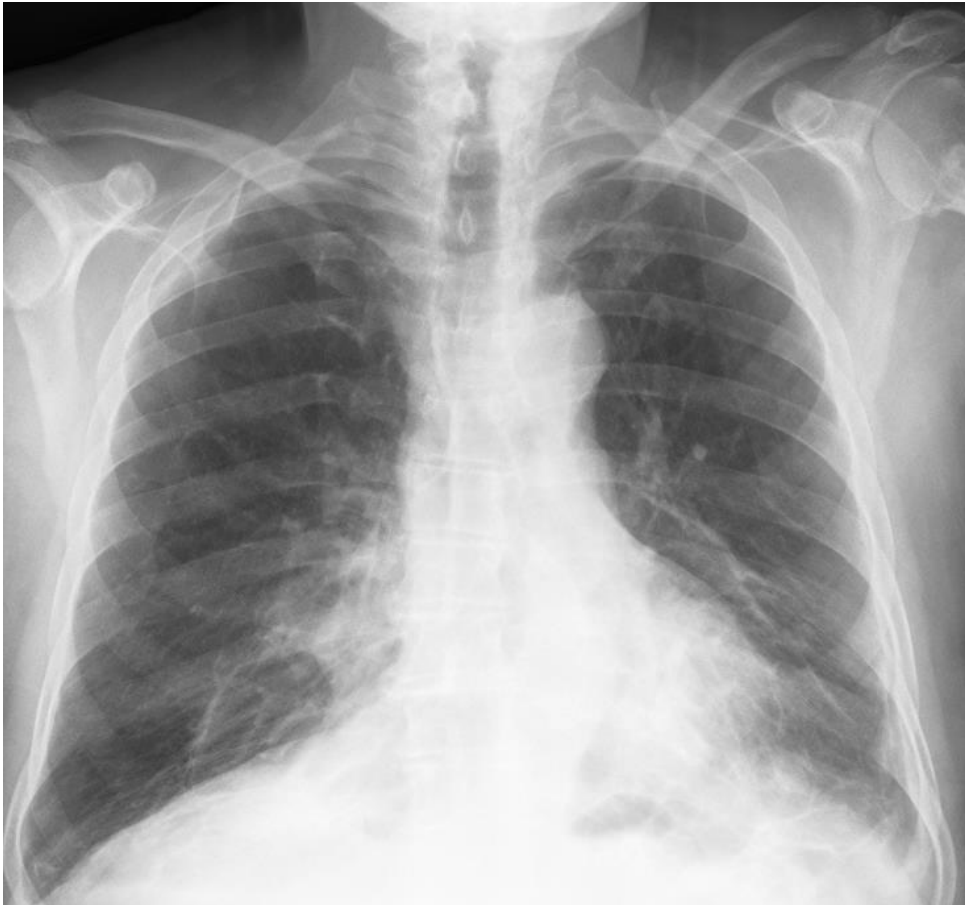
Atélectasie ronde



4A1. Epaissements tissulaires diffus bénins

Séquelles de pleurésie asbestosique

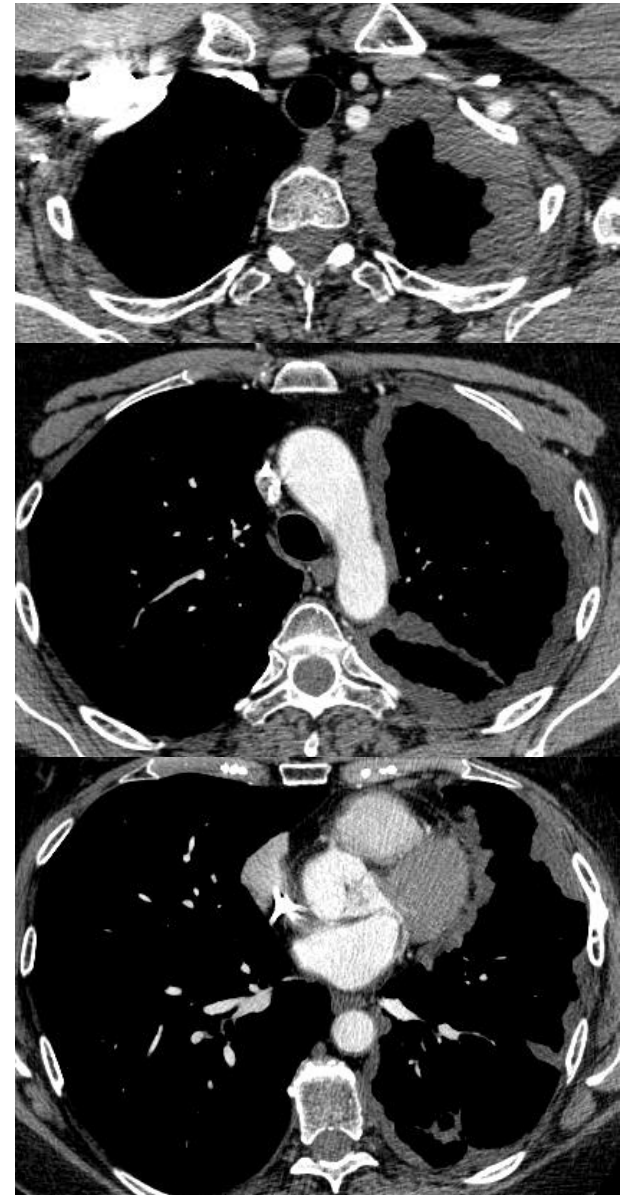
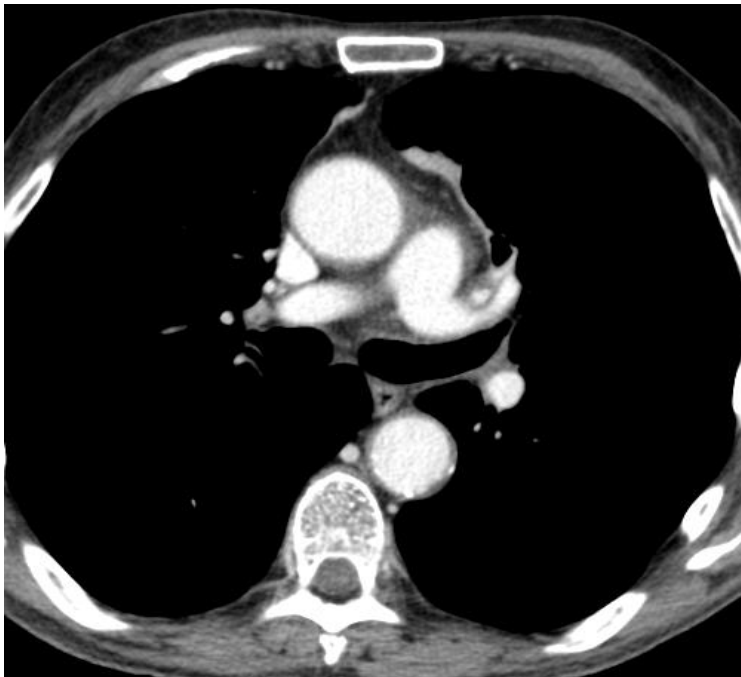

Atélectasie ronde

4A2. Epaissements tissulaires diffus malins

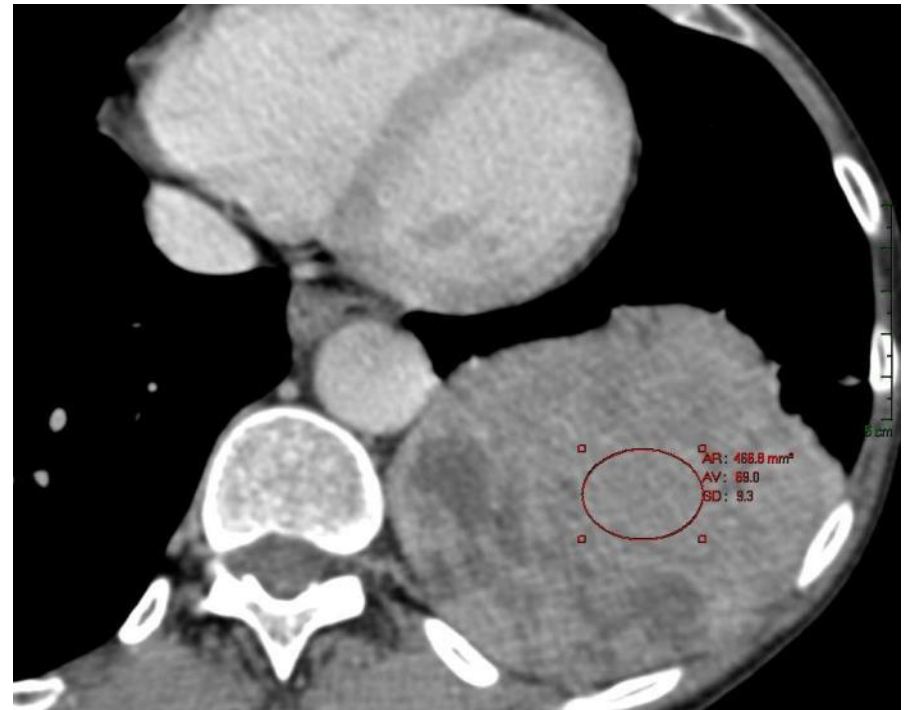
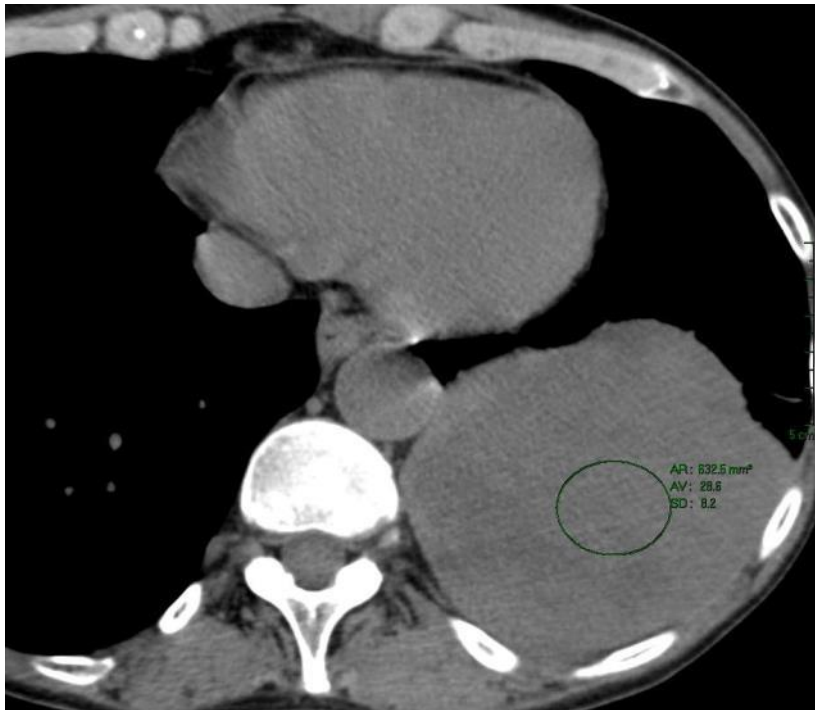
Signes diagnostiques : épaissement

- nodulaire
- circonférentiel
- >1 cm
- plèvre médiastinale



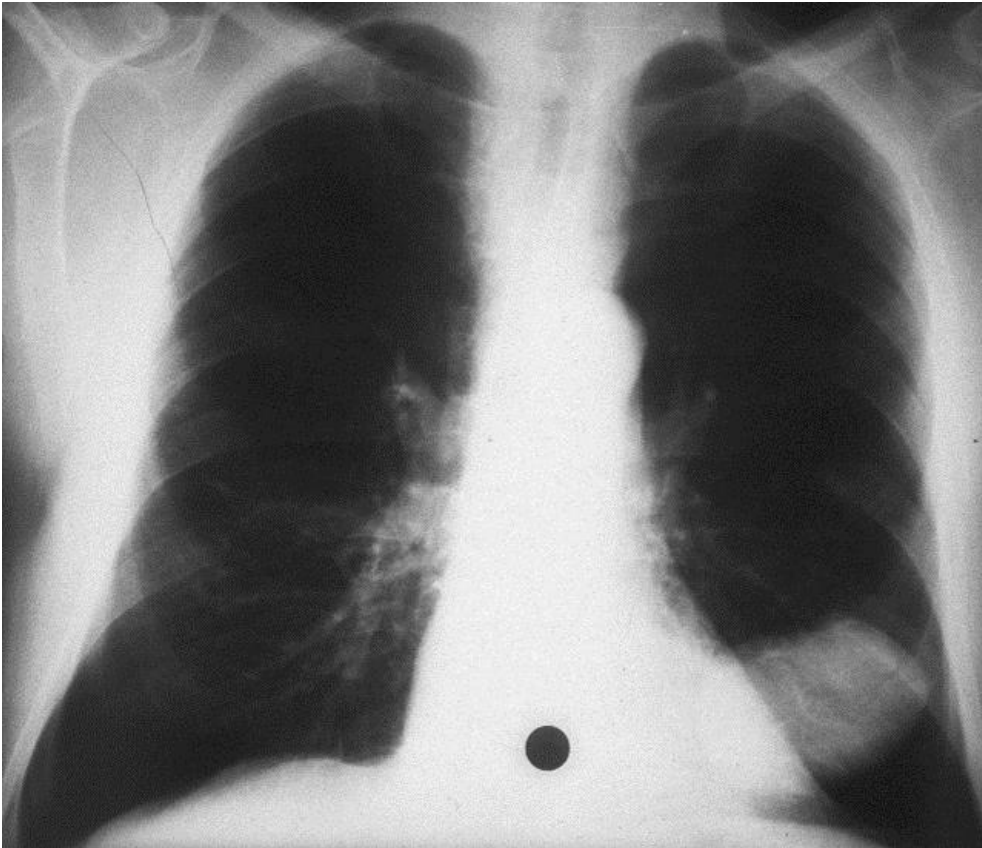
4B. Epaissements tissulaires isolés

Tumeur fibreuse pleurale

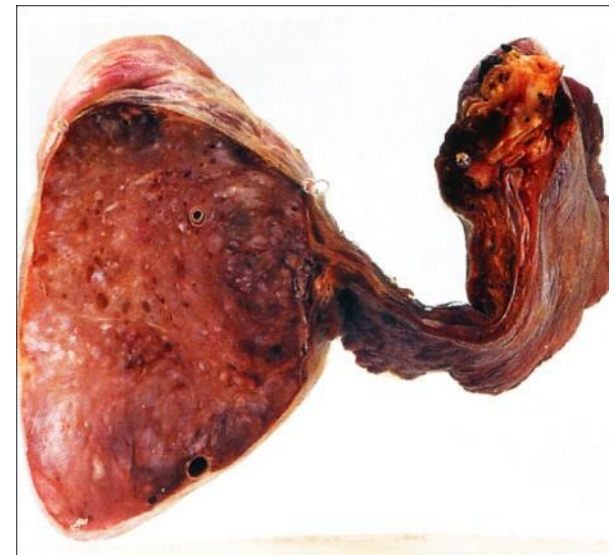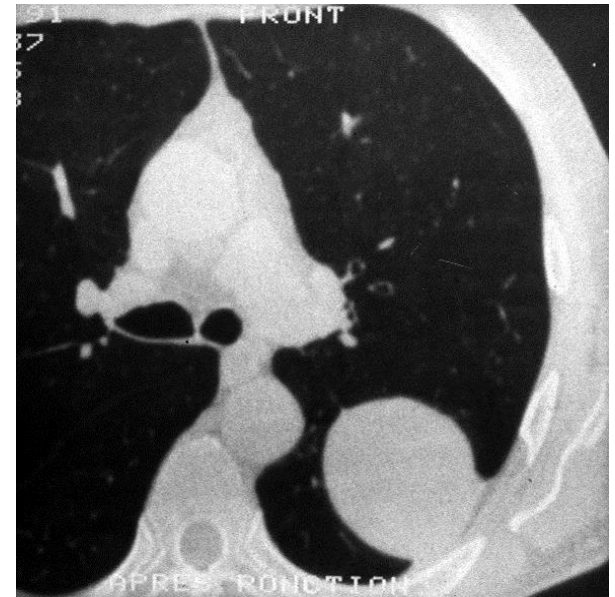


4B. Epaissements tissulaires isolés

Tumeur fibreuse pleurale

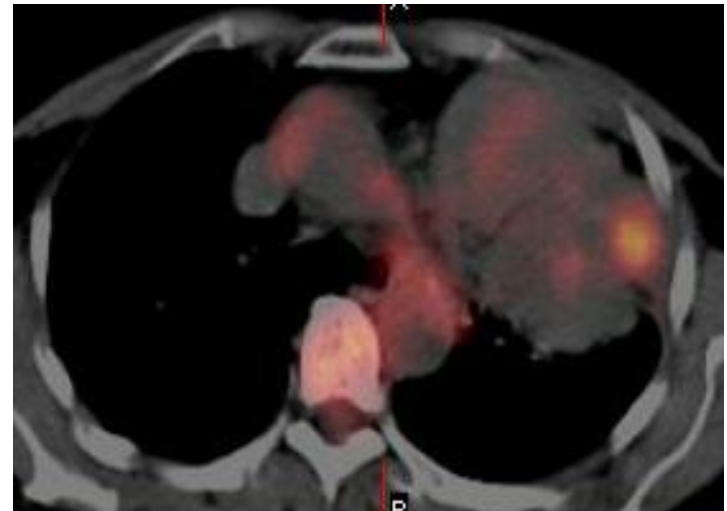
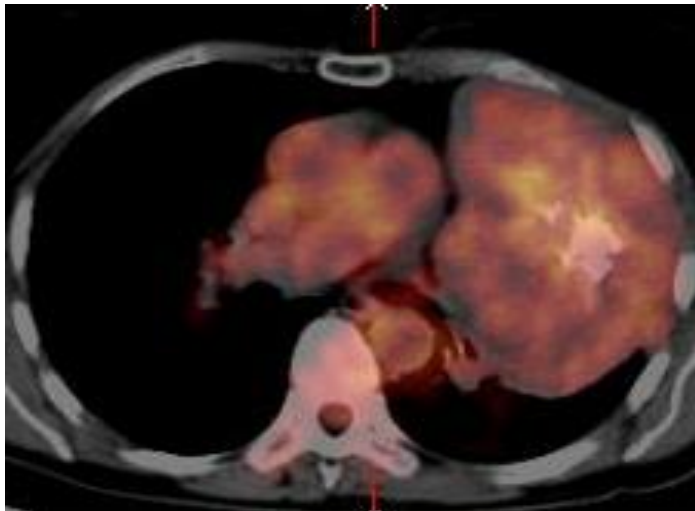
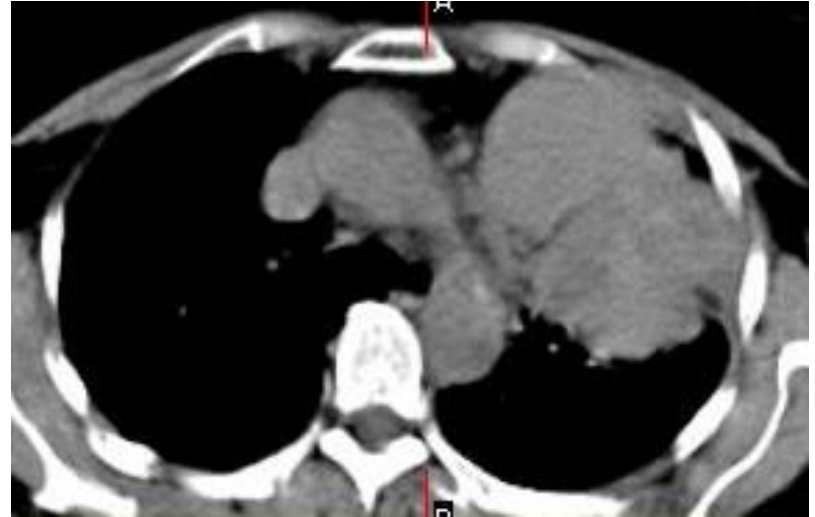
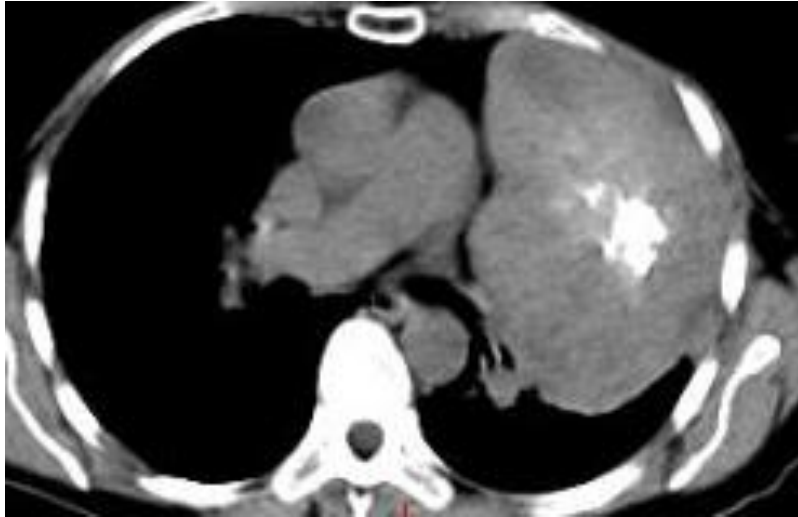


pédiculée et mobile dans la scissure

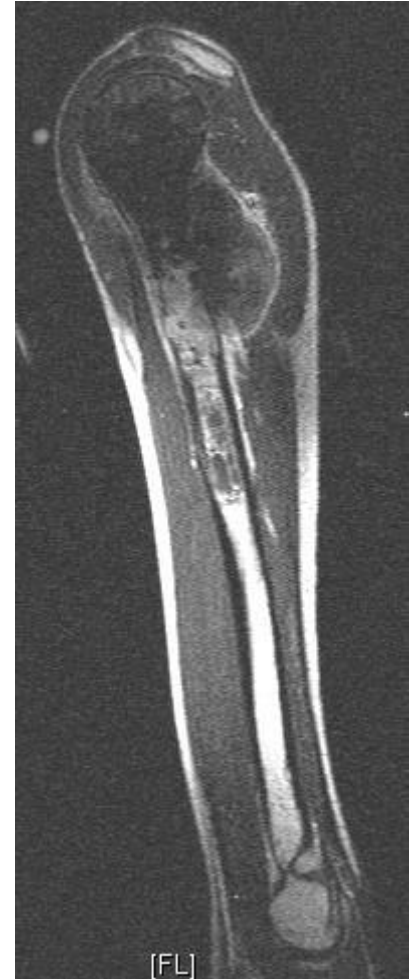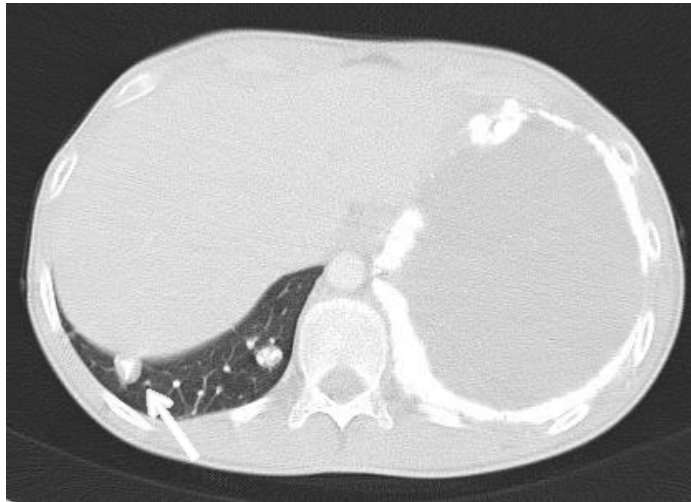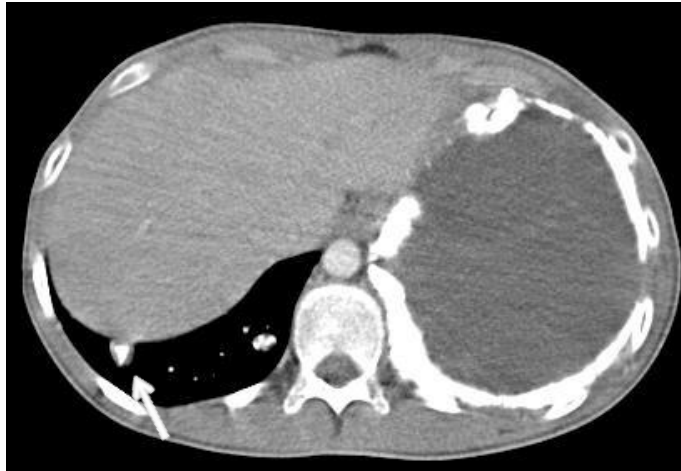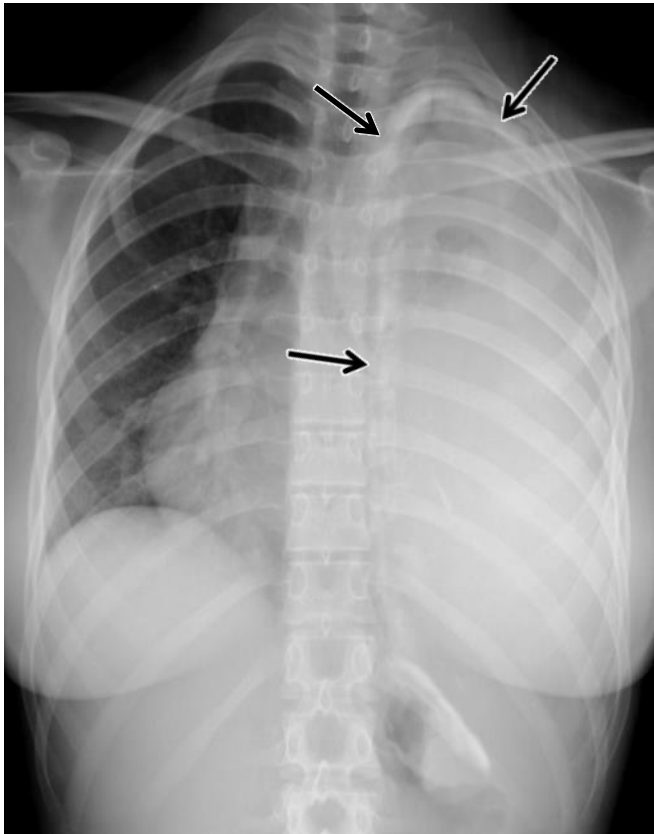


4B. Epaissements tissulaires isolés

Mésothéliome à cellules fusiformes de haut grade



4. Epaissements tissulaires

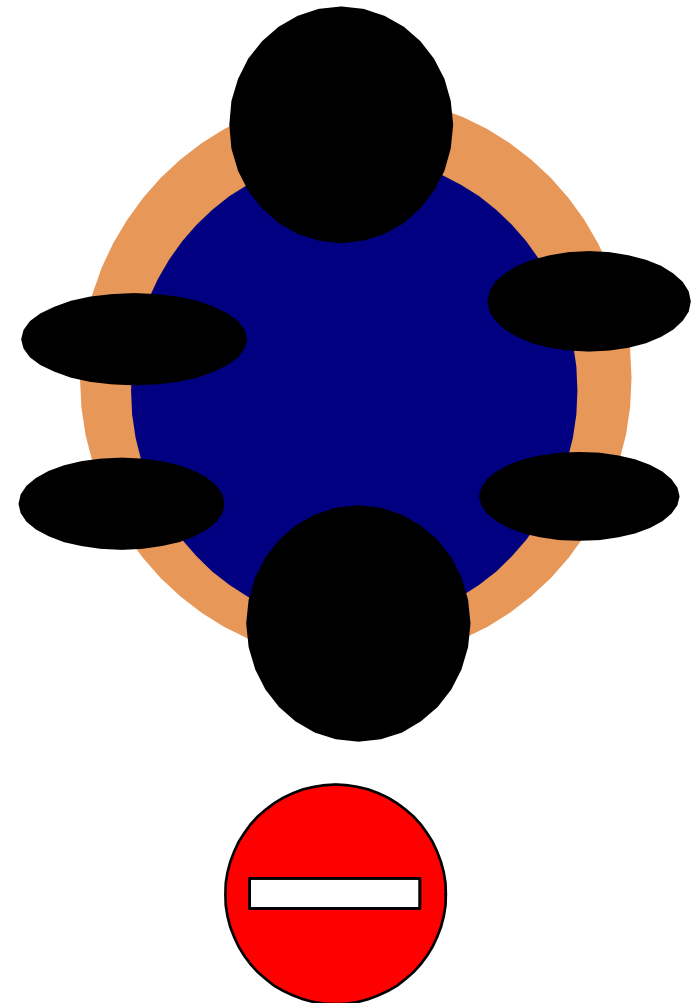
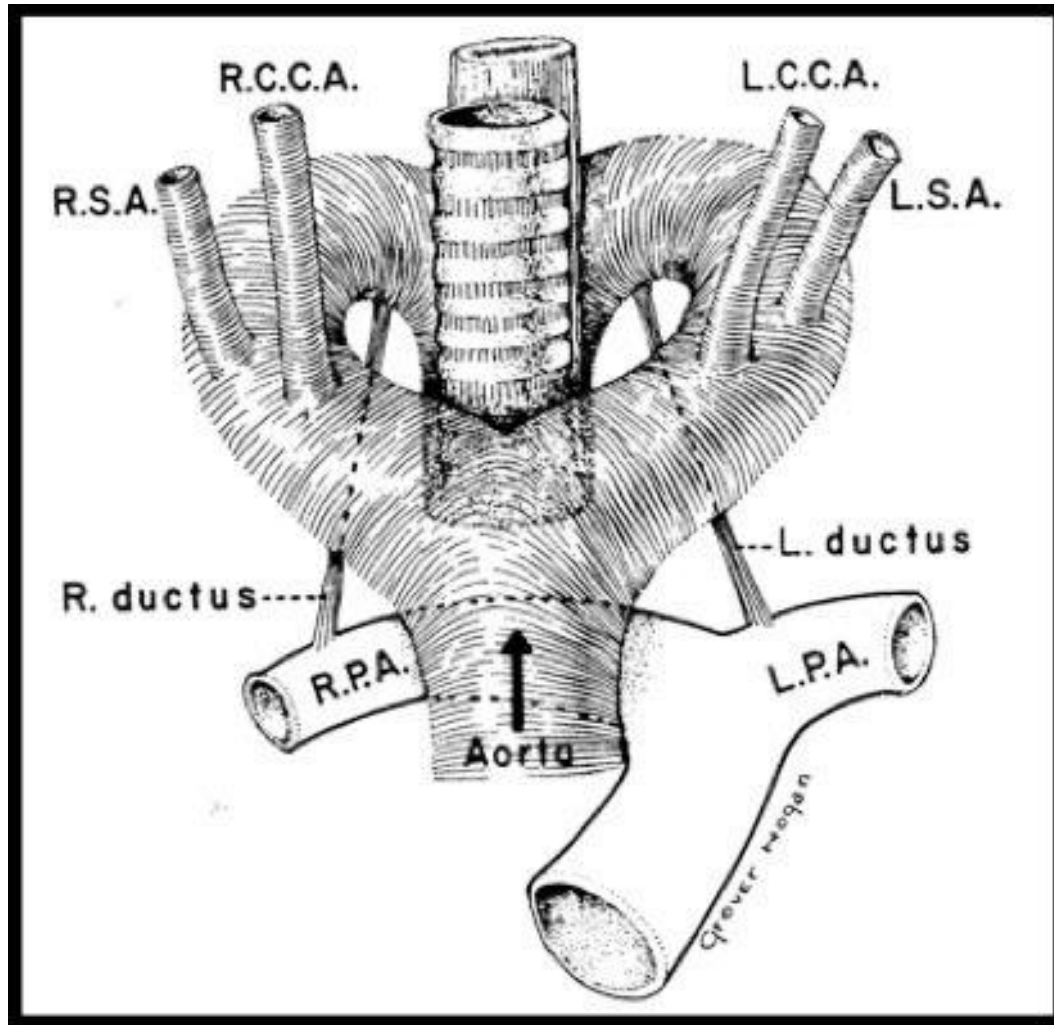


Métastase d'un ostéosarcome

3. Aorte

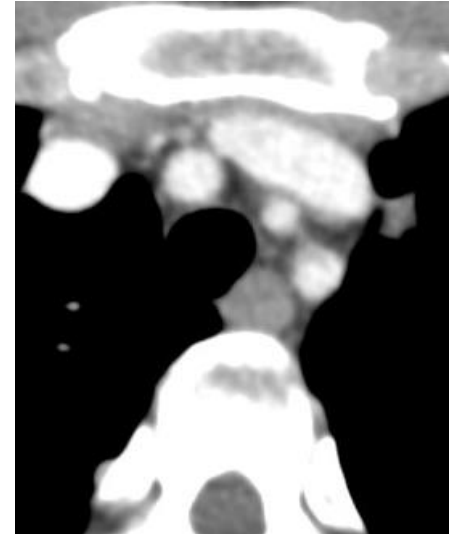
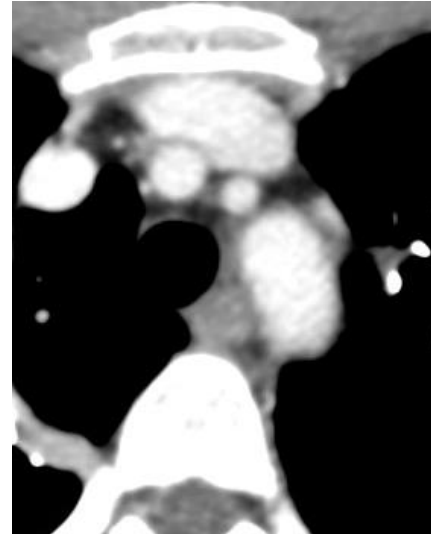
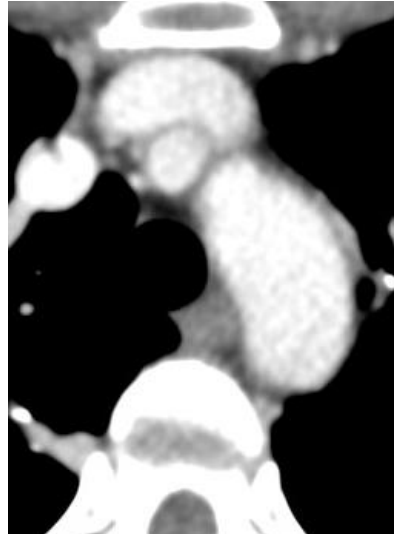
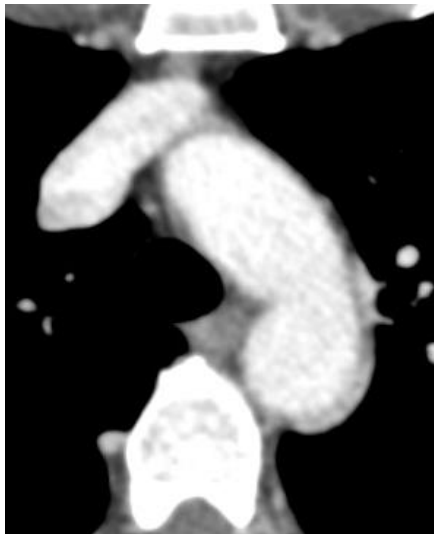
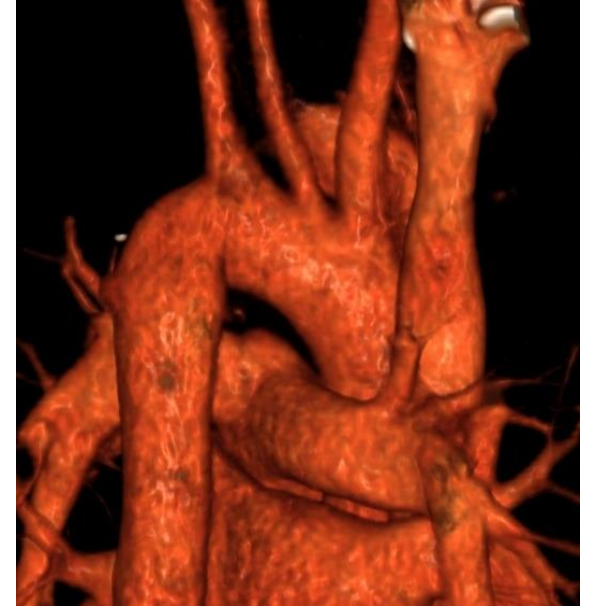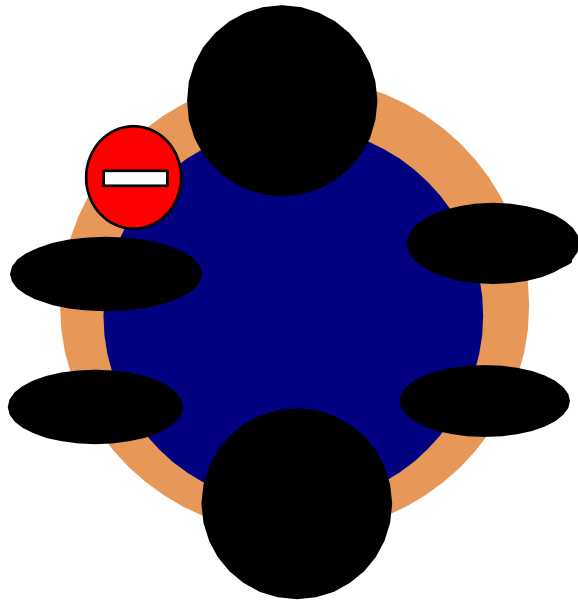
- 3A. Syndrome aortique aigu
- 3B. Anévrisme aortique
- 3C. Rupture traumatique de l'aorte
- 3D. Anomalies congénitales
 - Anomalies des arcs aortiques
 - Coarctation aortique

3C1. Anomalies des arcs aortiques



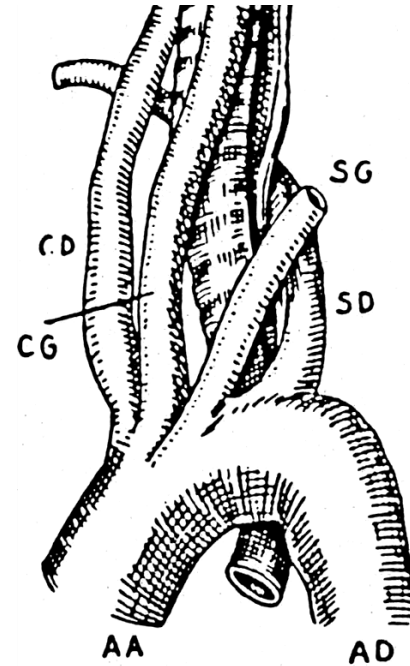
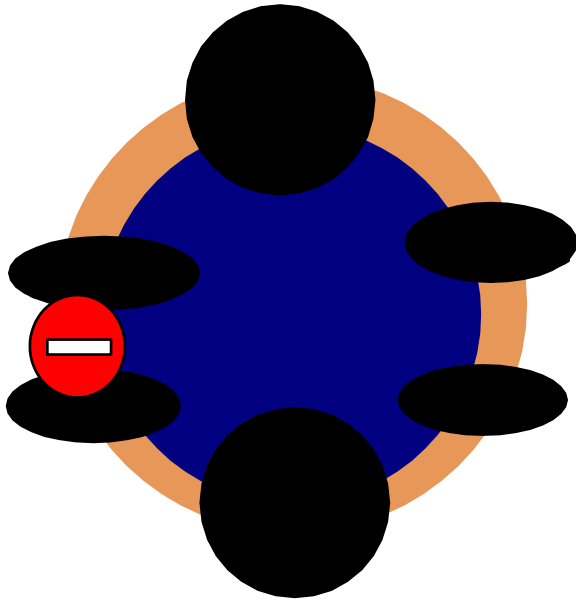
3C1. Anomalies des arcs aortiques

Arc G normal



3C1. Anomalies des arcs aortiques

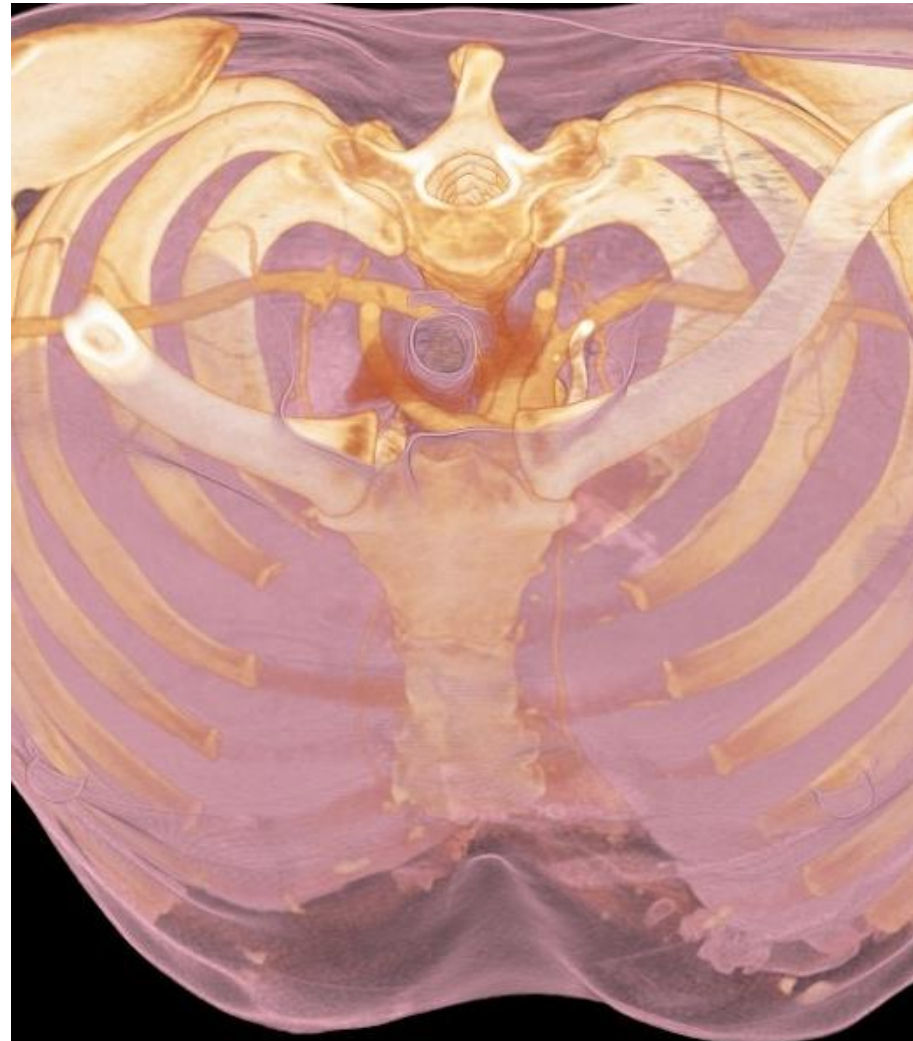
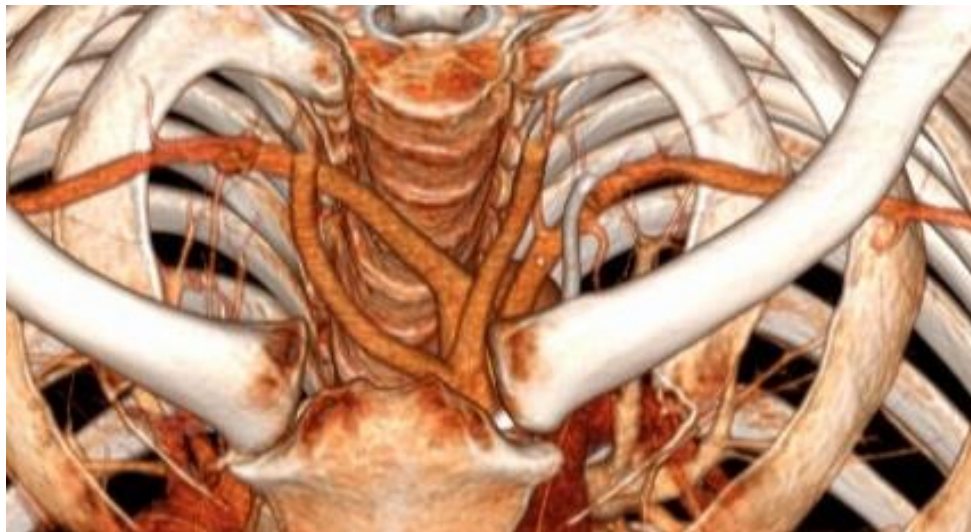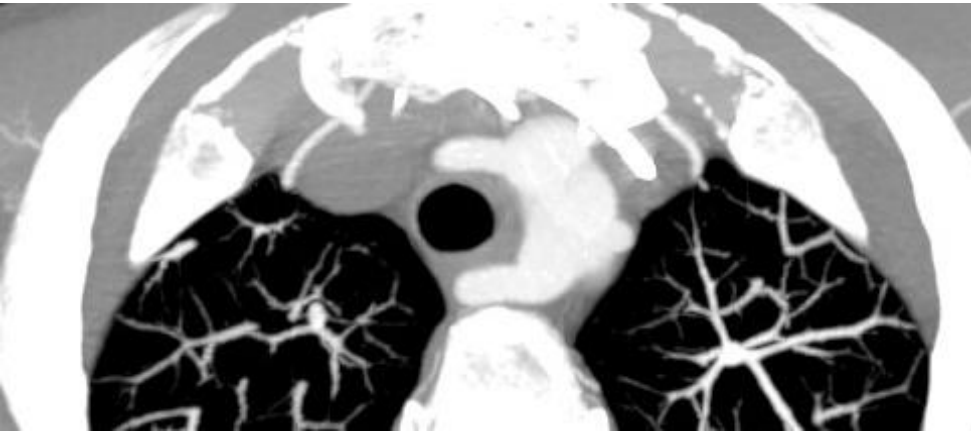
Arteria lusoria



- Artère sous-clavière D aberrante
- Passe en arrière de la trachée et de l'oesophage
- Souvent de découverte asymptotique (1%)
- Dysphagia lusoria

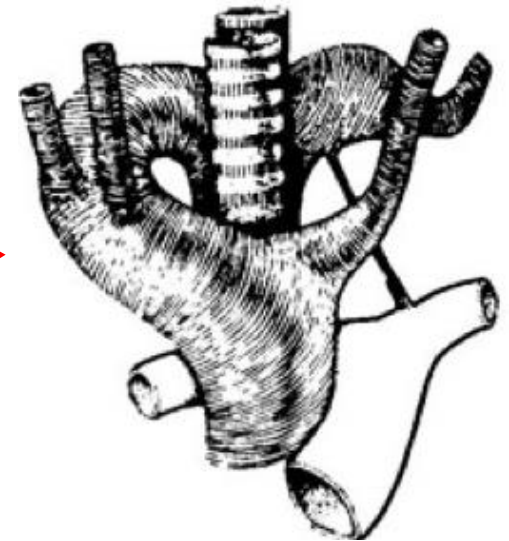
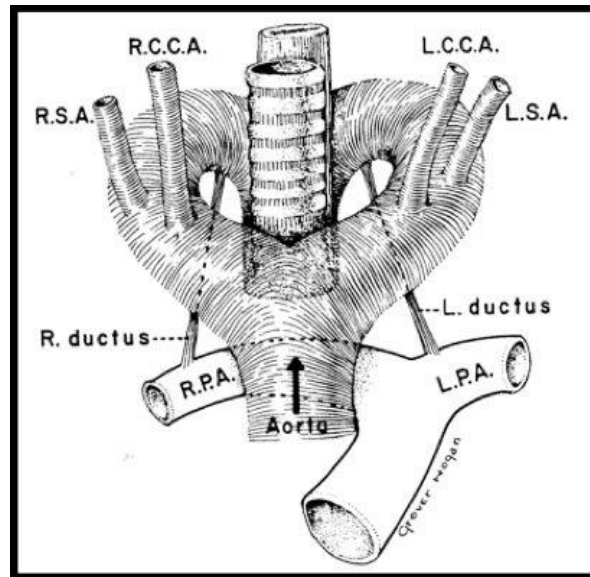
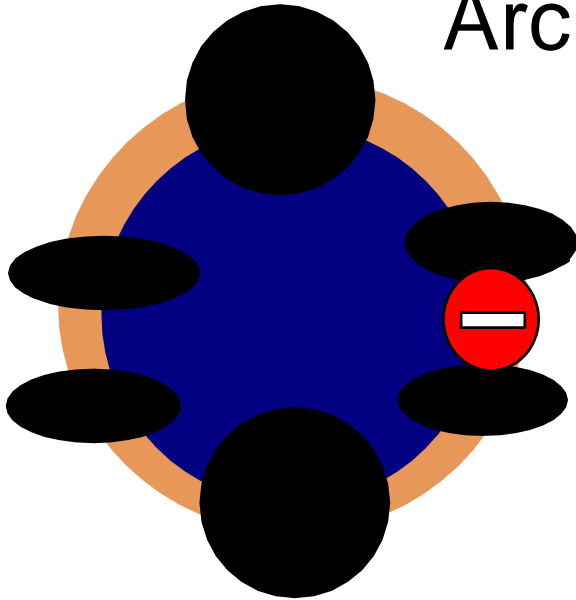
3C1. Anomalies des arcs aortiques

Arteria lusoria



3C1. Anomalies des arcs aortiques

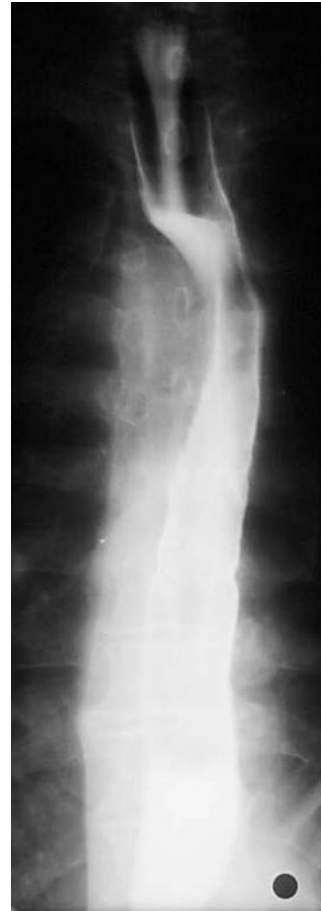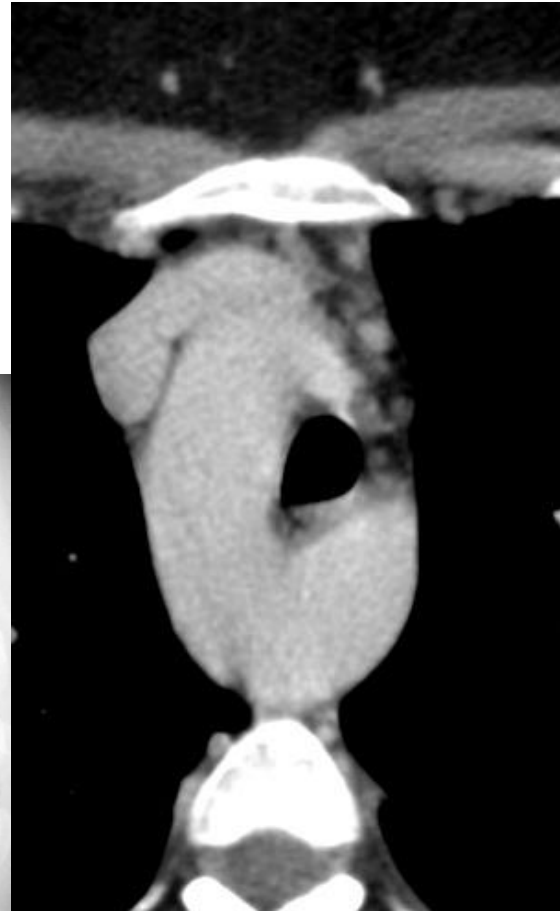
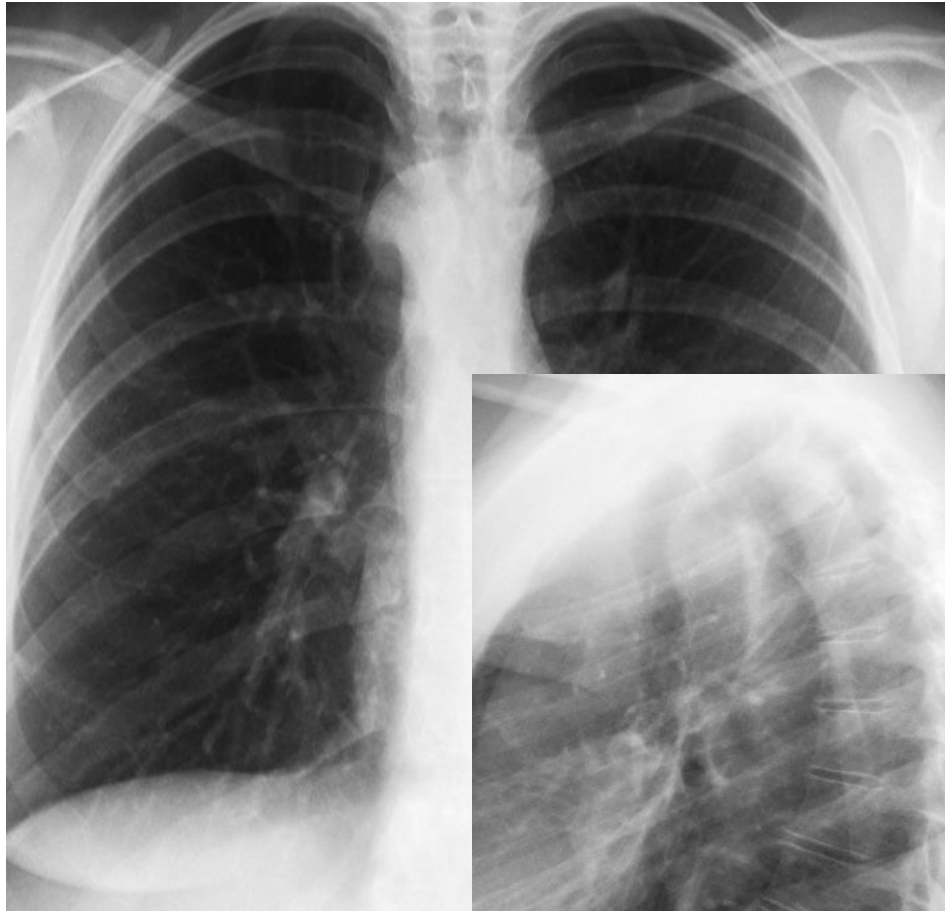Arc aortique D avec A lusoria G



- Avec A sous-clavière G aberrante (0.1 %)
- 5 % d'anomalies cardiaques associées

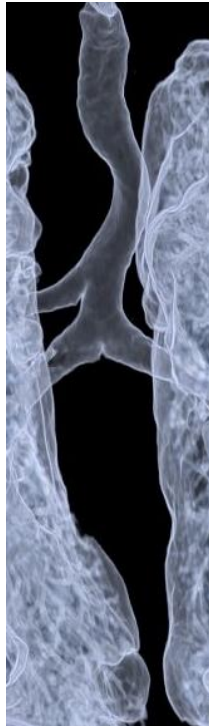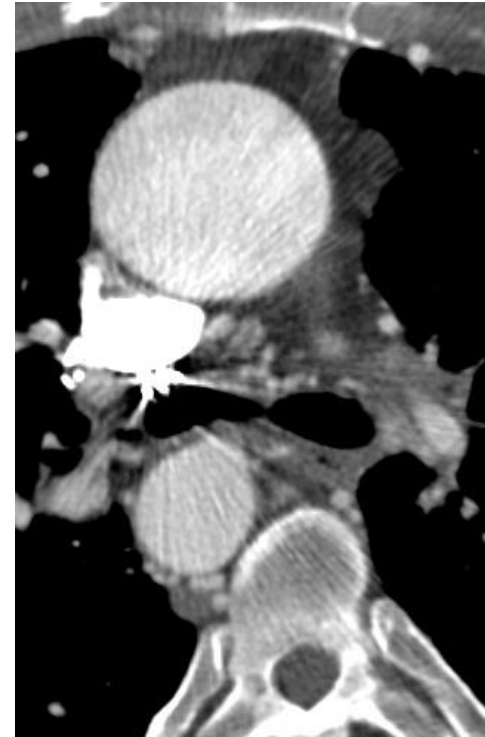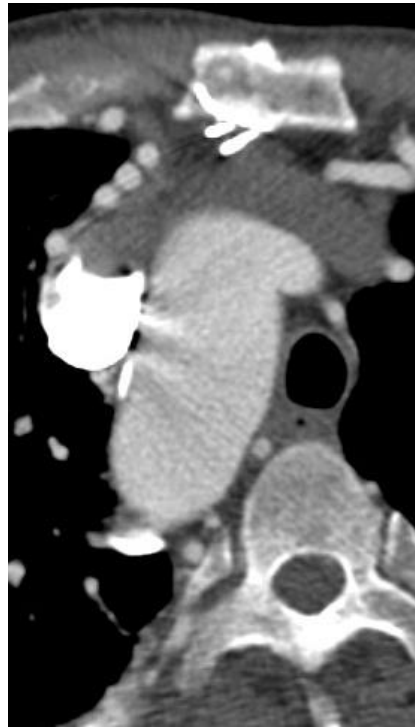
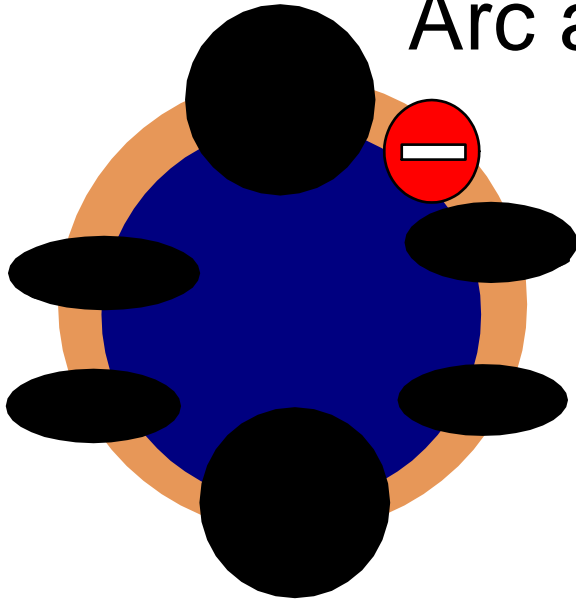
3C1. Anomalies des arcs aortiques

Arc aortique D avec A lusoria G



3C1. Anomalies des arcs aortiques

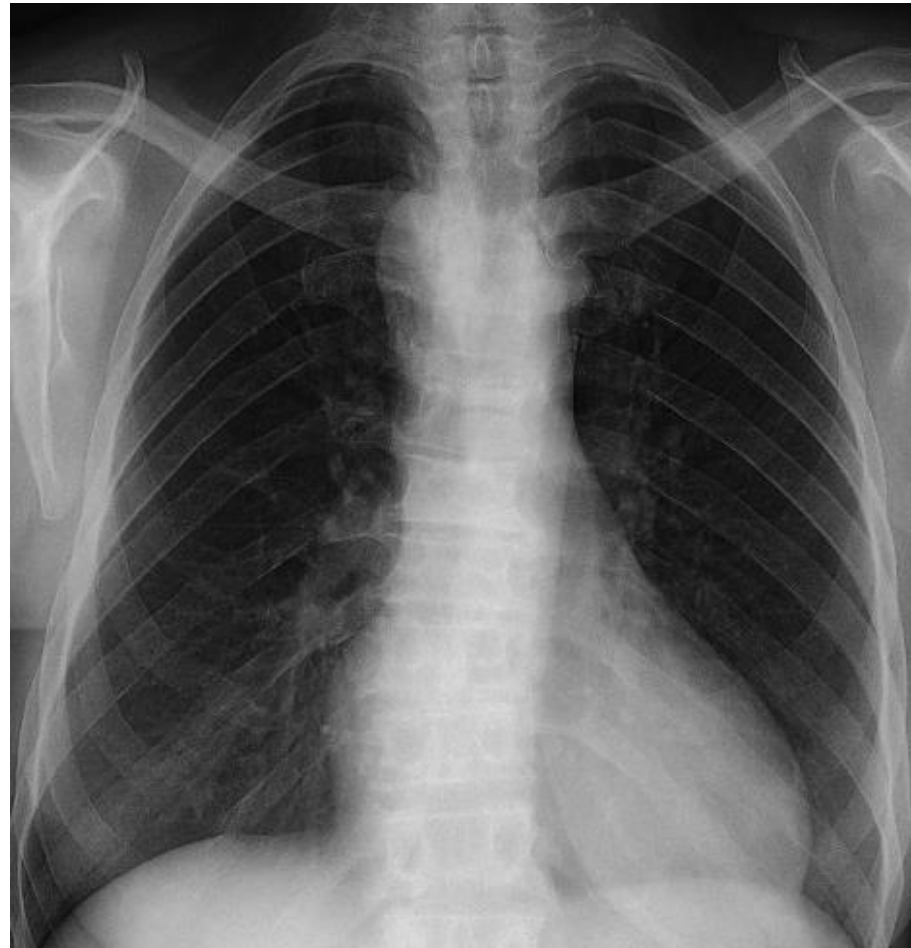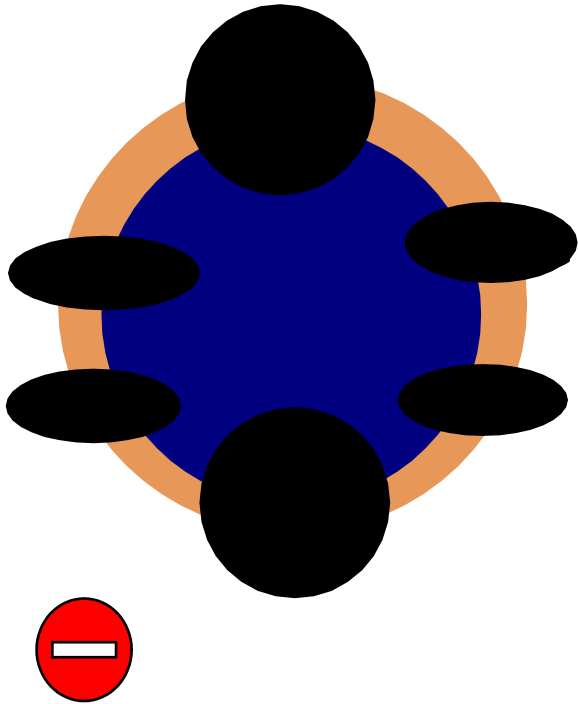
Arc aortique D « en miroir »



- Avec image en miroir de la gerbe aortique (rare)
 - 90 % d'anomalies cardiaques associées

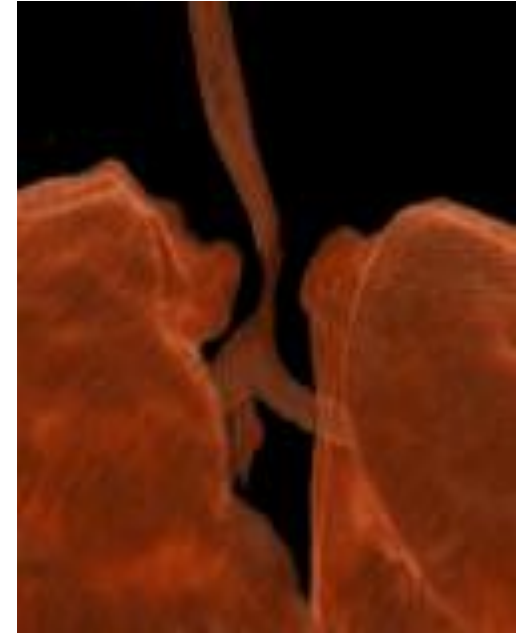
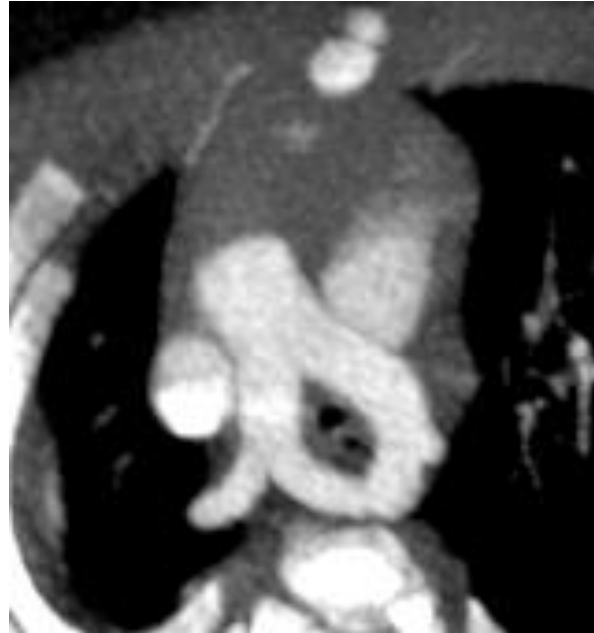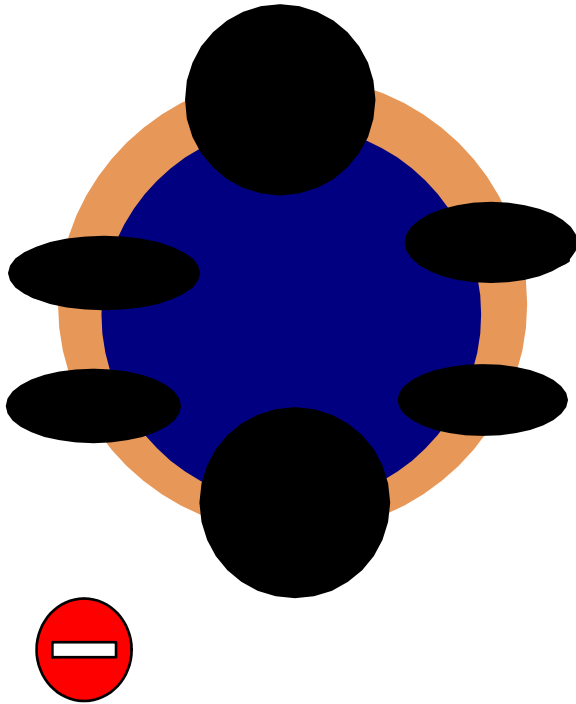
3C1. Anomalies des arcs aortiques

Double arc aortique



3C1. Anomalies des arcs aortiques

Double arc aortique



- 0.3 % des cas
- rare anomalie cardiaque associée
- anneau vasculaire complet
 - trachéomalacie
 - dysphagie

3C1. Coarctation de l'aorte

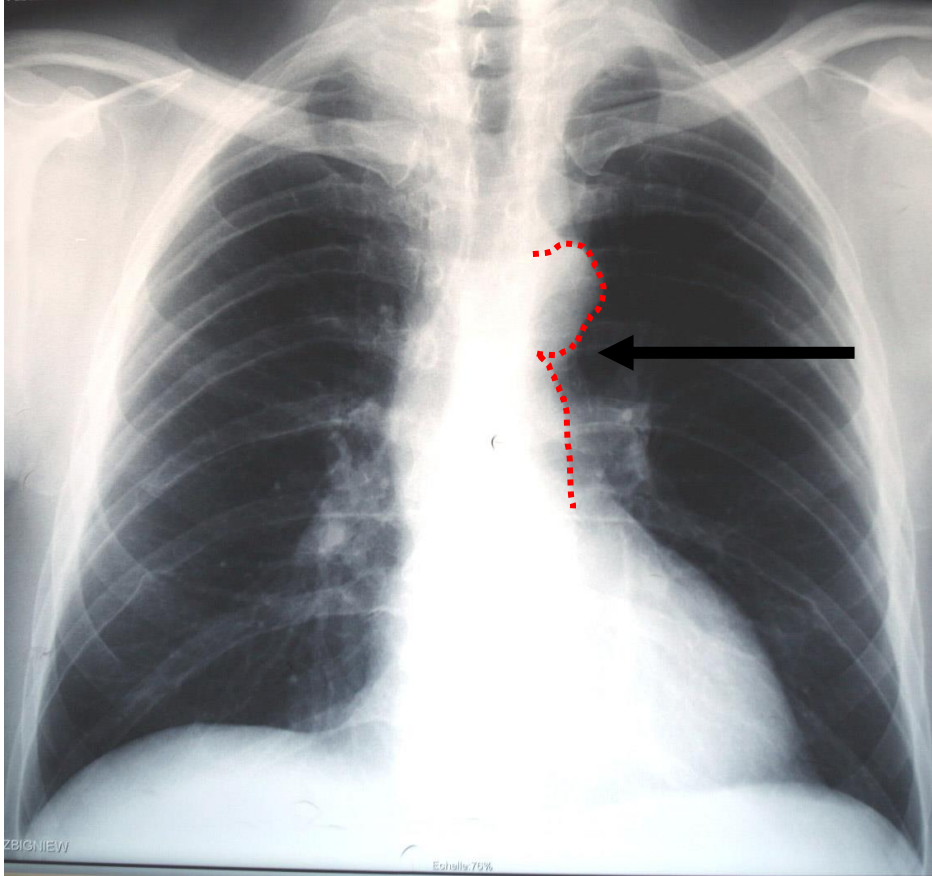
- rétrécissement serré de l'aorte à hauteur de l'isthme avec dilatation post-sténotique
 - prévalence: 1/5.000
 - lésions cardiaques associées dans 50 % des cas (bicuspidie aortique)
- conséquence hémodynamique :
 - hypertension d'amont (avec HVG) et hypotension d'aval
 - risque d'anévrisme intracérébral (et de rupture)
 - risque de dissection aortique
 - entre les 2: circulation collatérale (intercostales)
- Cliniquement : HTA aux membres supérieurs avec abolition des pouls fémoraux

3C1. Coarctation de l'aorte

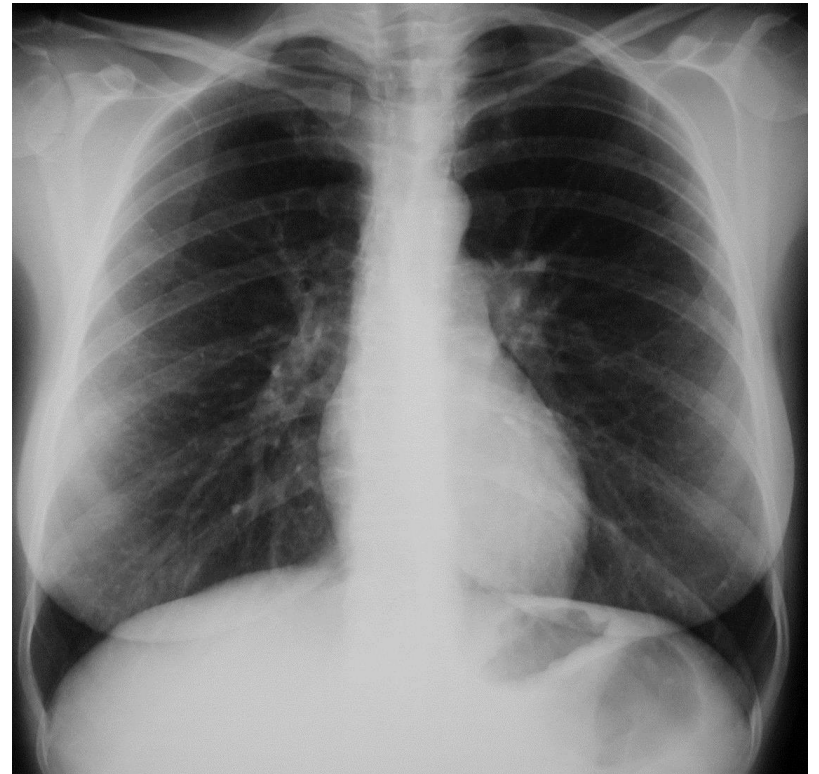
- Rx standard
 - morphologie en 3 du bord gauche de l'aorte
 - boucle supérieure du 3: bouton aortique
 - le retrait du 3: sténose isthmique
 - (boucle inférieure: dilatation post-sténotique)
 - cardiomégalie associée (HVG)
 - érosions costales, par hypertrophie des intercostales
- L'anomalie est bilantée par TDM ou IRM
- L'angiographie permet à titre préopératoire de mesurer le gradient trans-sténotique

3

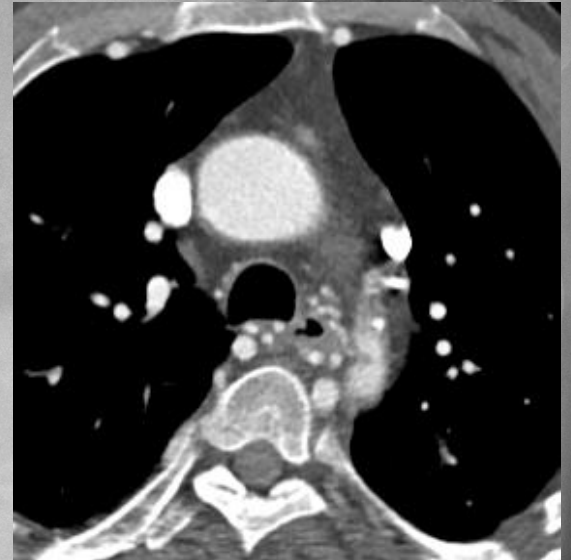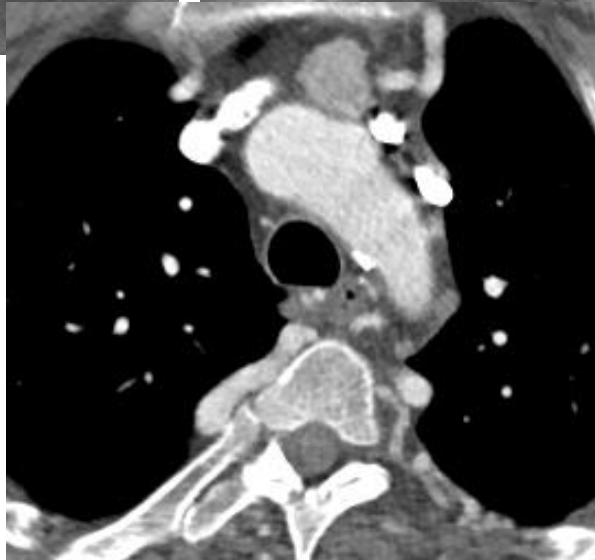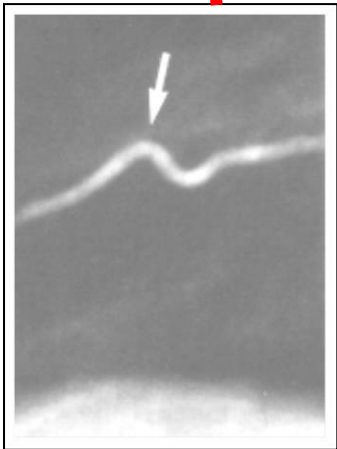
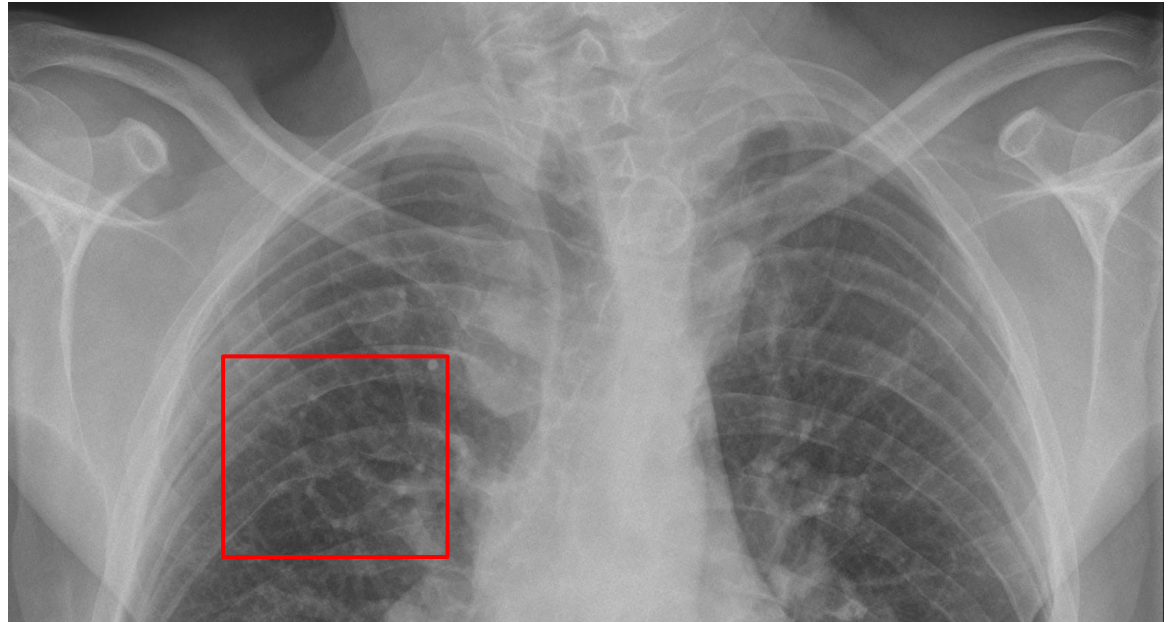
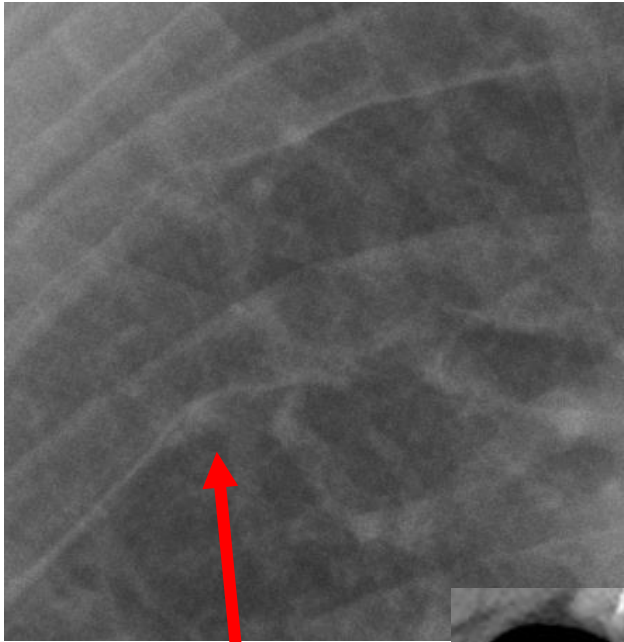
3C1. Coarctation de l'aorte



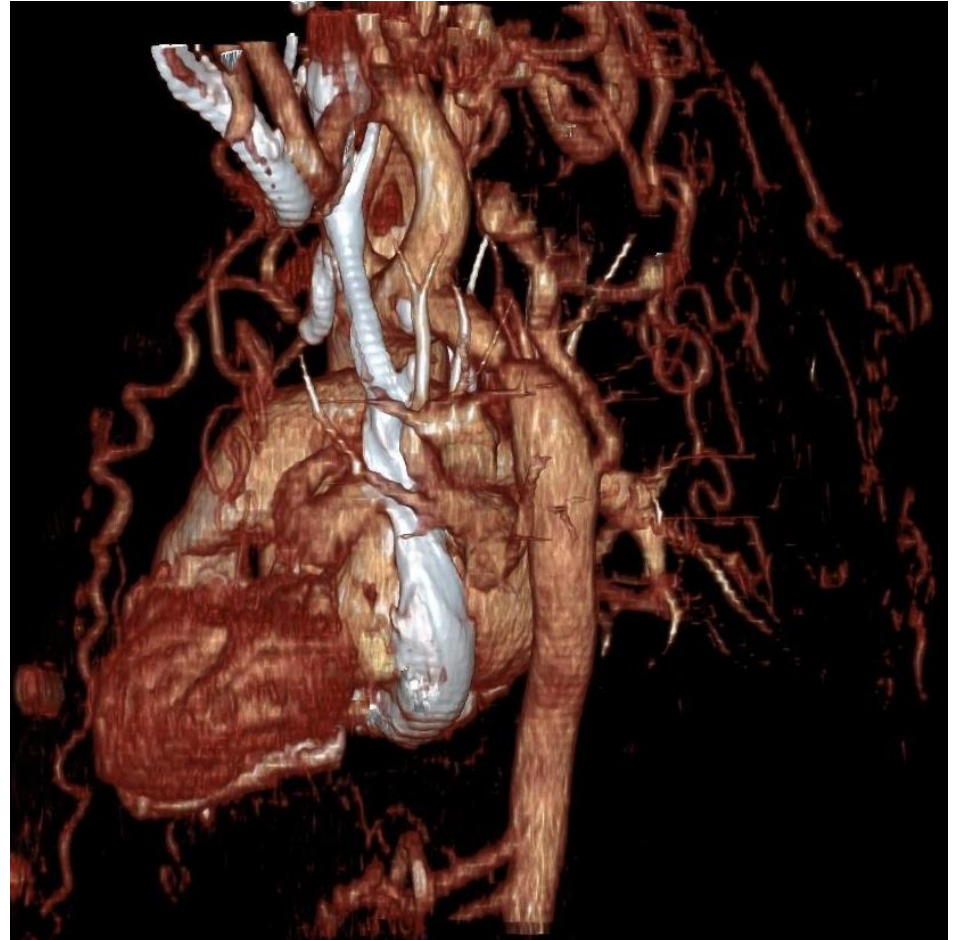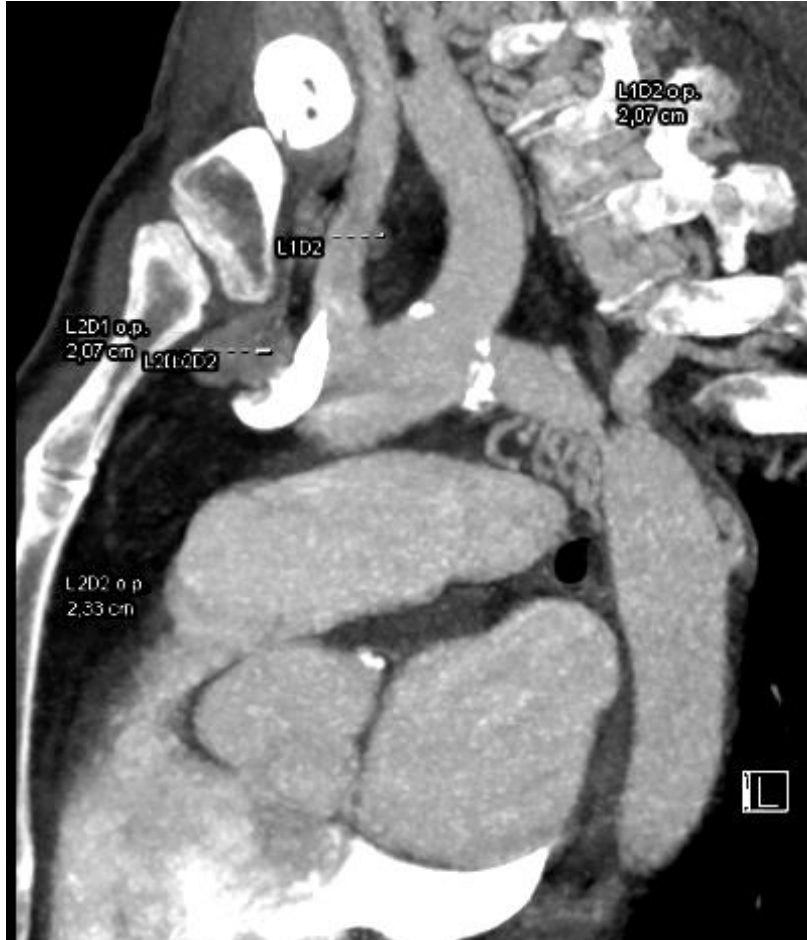
3



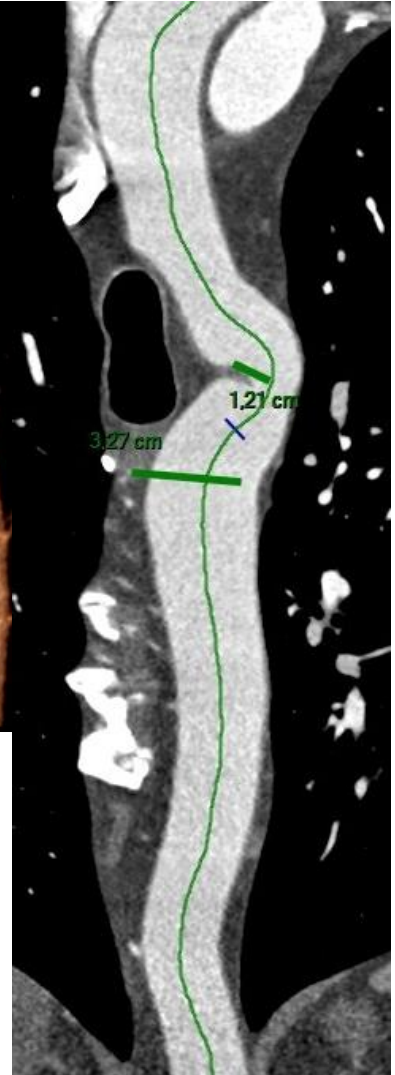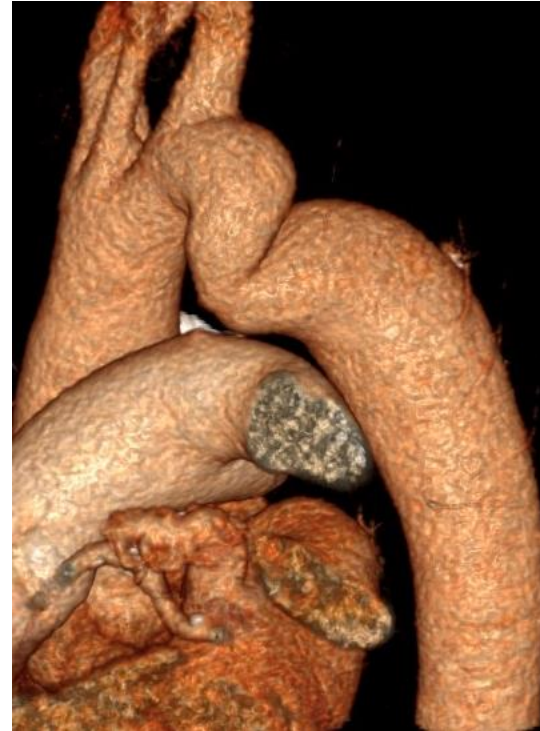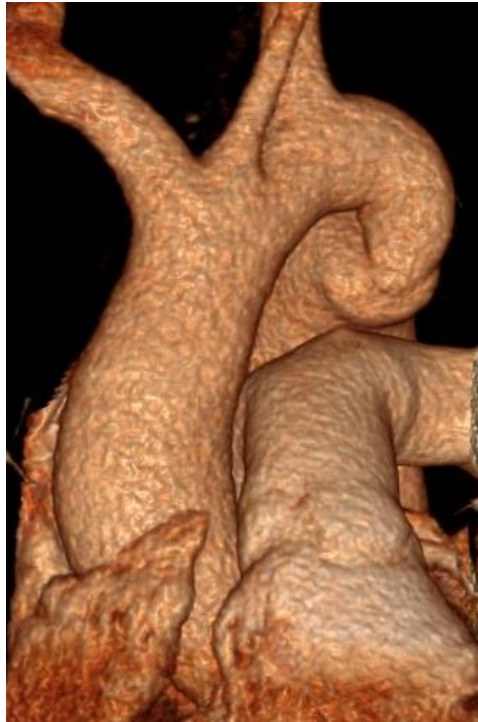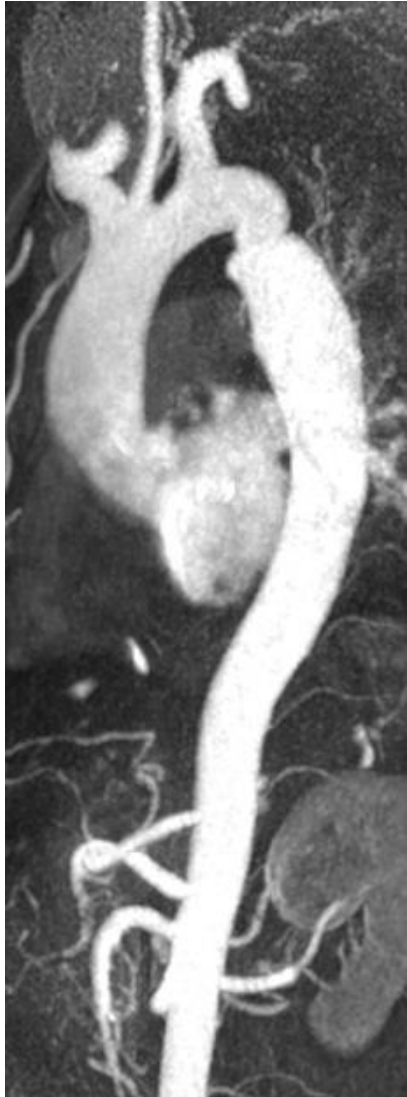3C1. Coarctation de l'aorte



3C1. Coarctation de l'aorte



3C1. Coarctation de l'aorte



- DD : pseudocoarctation
aspect similaire mais pas de rétrécissement

**Imagerie thoracique du patient
en position couchée
Soins intensifs
Cathéters, drains, etc...**

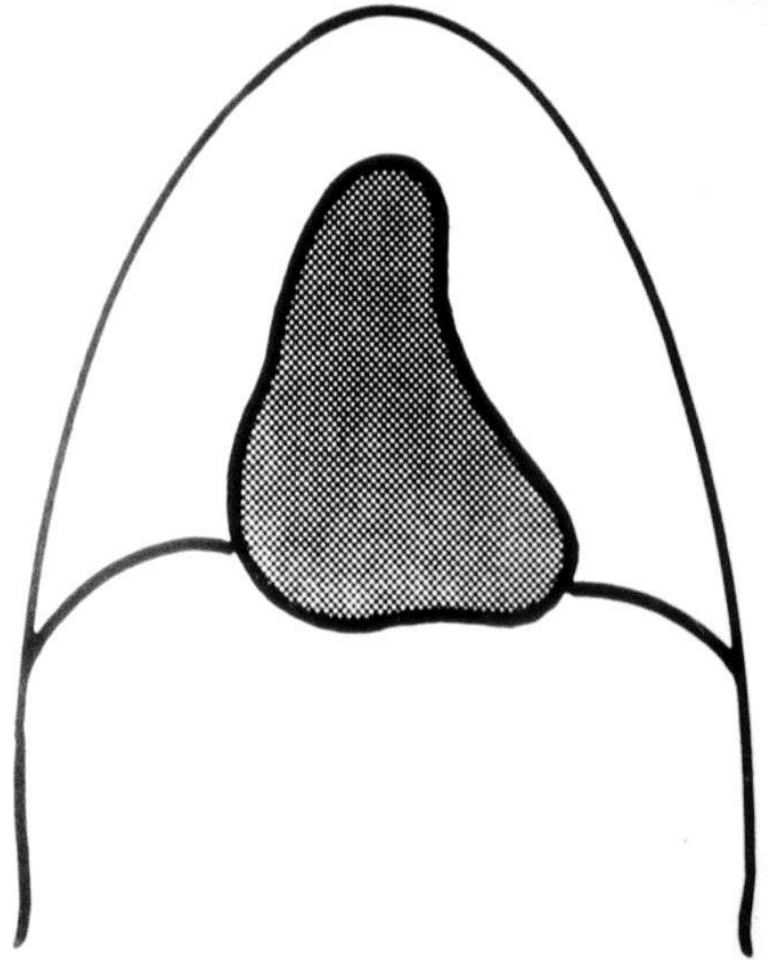
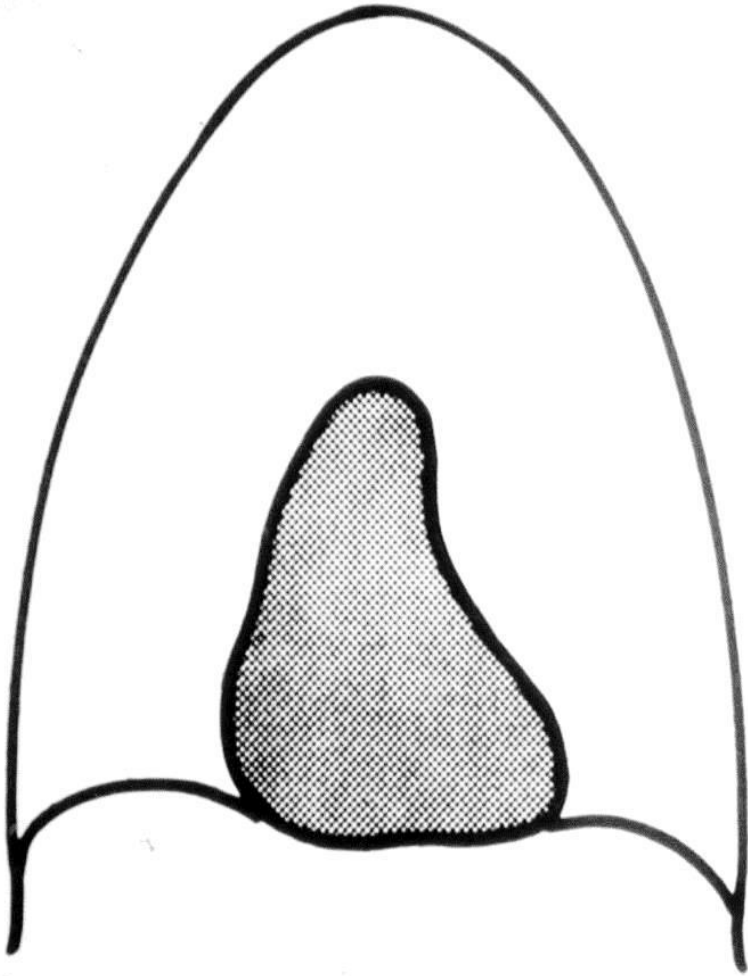
Prof. Benoît Ghaye

Service de Radiologie
Cliniques Universitaires St-Luc
Université Catholique de Louvain
Avenue Hippocrate 10 - 1200 Bruxelles benoit.ghaye@uclouvain.be

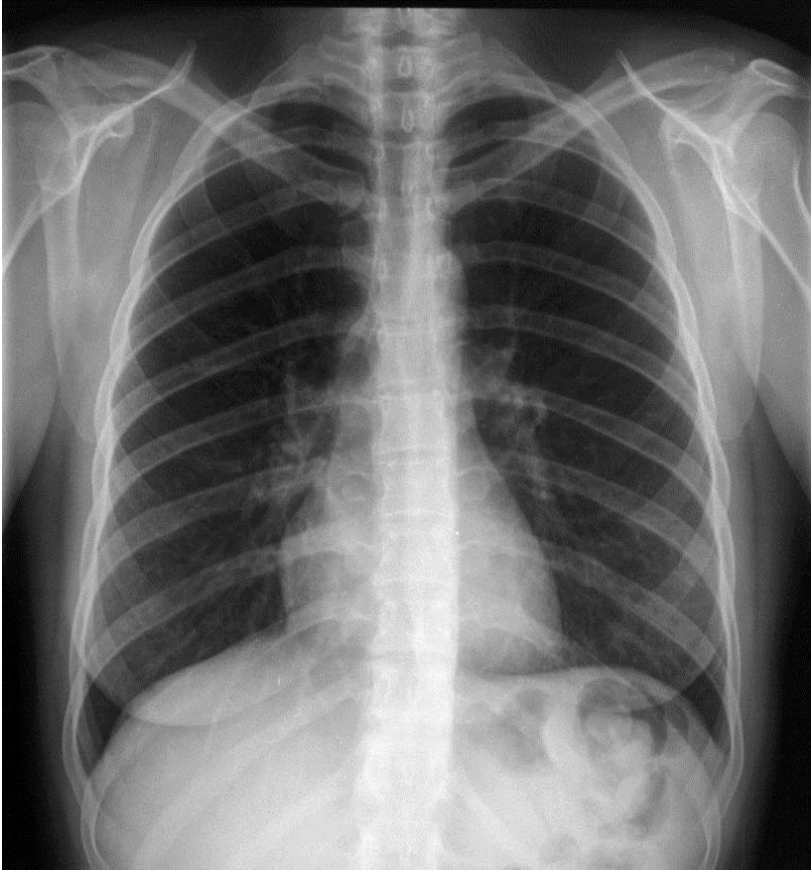
Différences Debout vs Couché

- Paroi -
- Médiastin +
- Parenchyme +
- Cœur +
- Plèvre +++

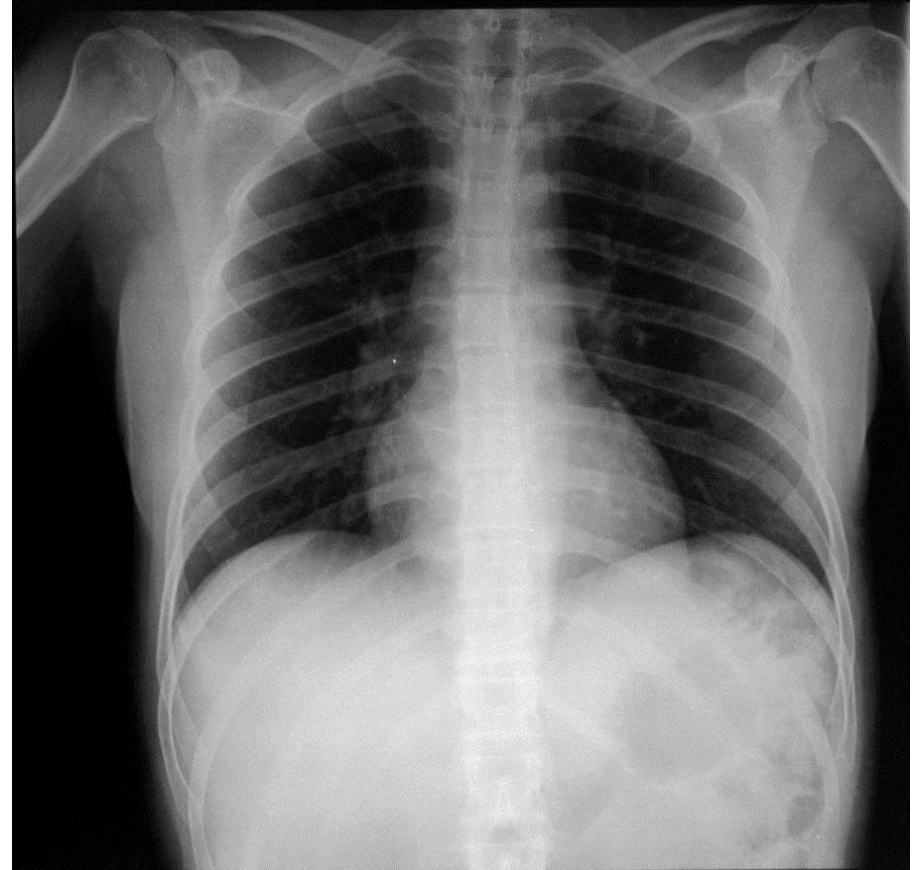Coeur



Coeur



DEBOUT



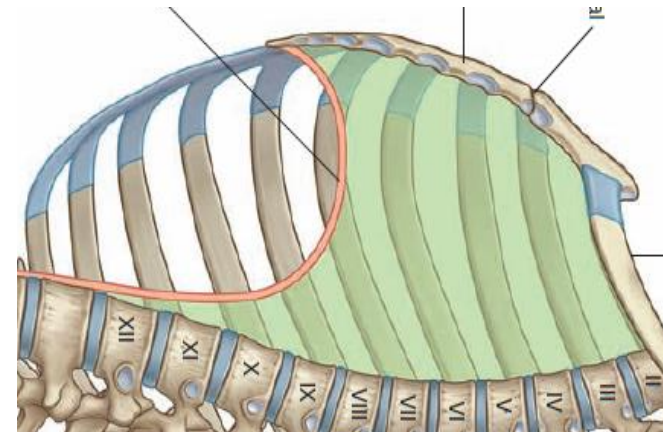
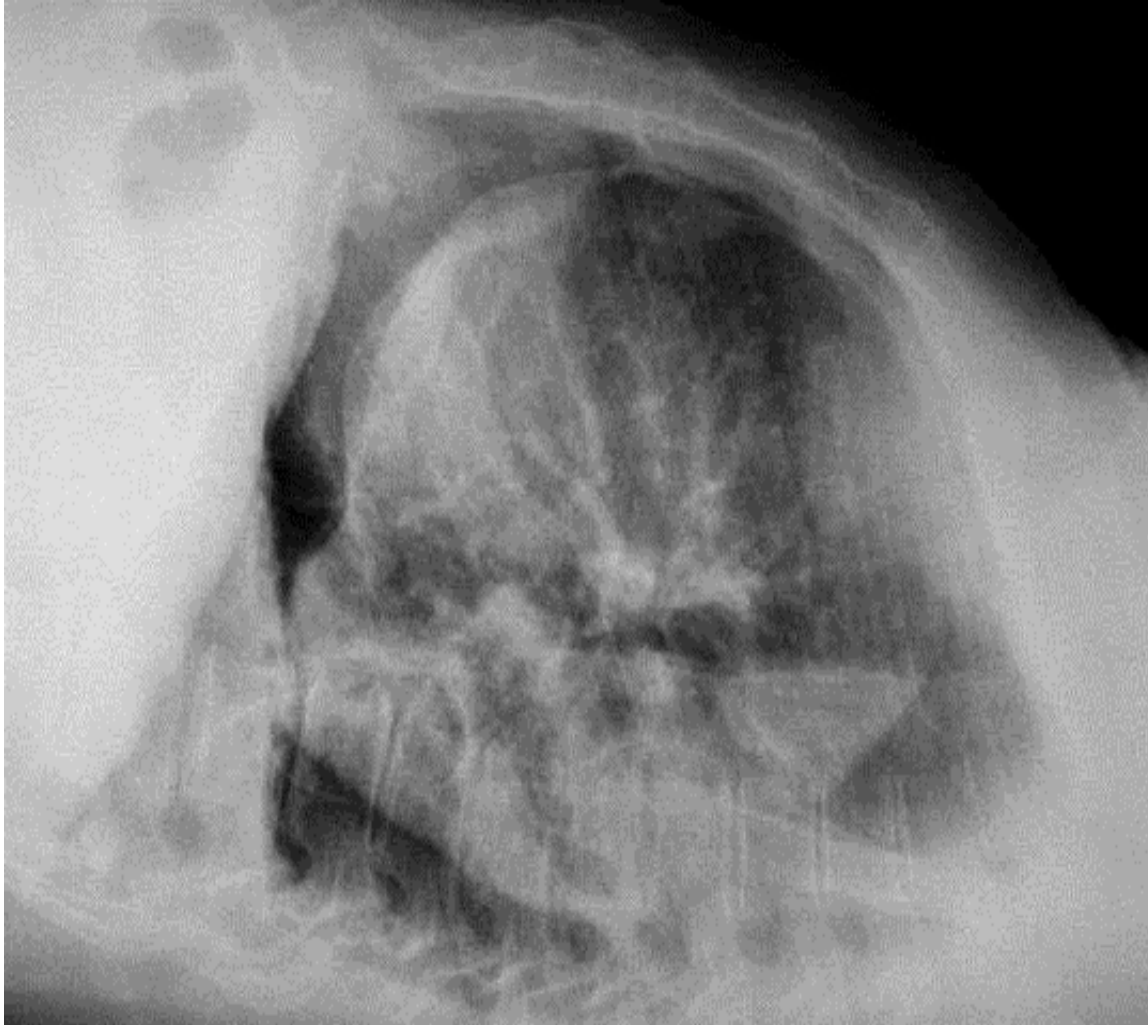COUCHE

Cœur

- Thorax + petit : expiratoire vs faible compliance des poumons
 - Distance focale de 1 m vs 1.5 m
 - Projections A/P vs P/A
- } Variations de -10 à 12,5%
ex : ICT de 0.57 en AP à 1m
= 0.50 sur un film PA à 1.5 m
- Debout vs décubitus :
 - coeur normal : aucun changement
 - coeur anormal : élargissement
 - Systole ventriculaire vs diastole

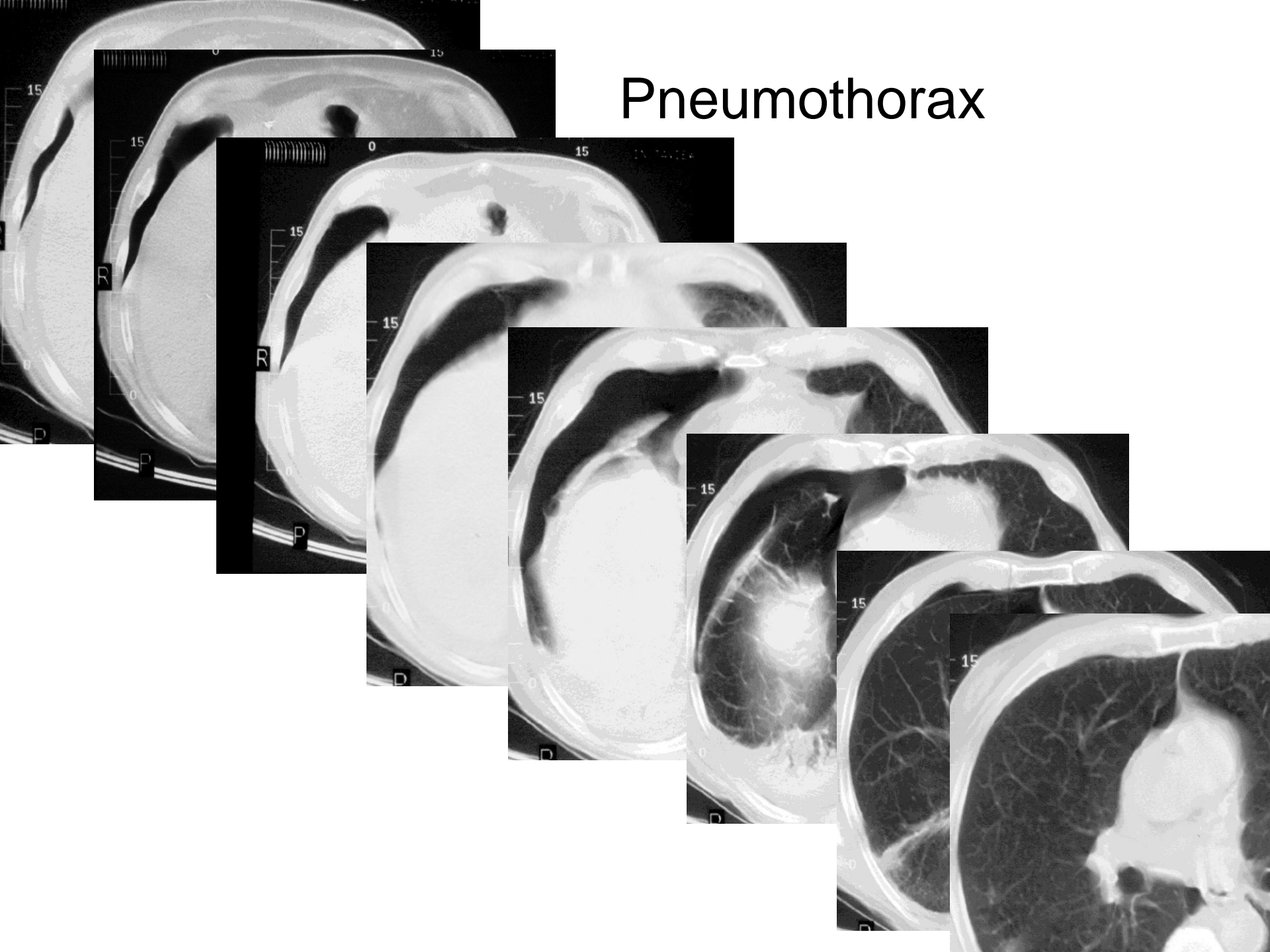Plèvre

Pneumothorax



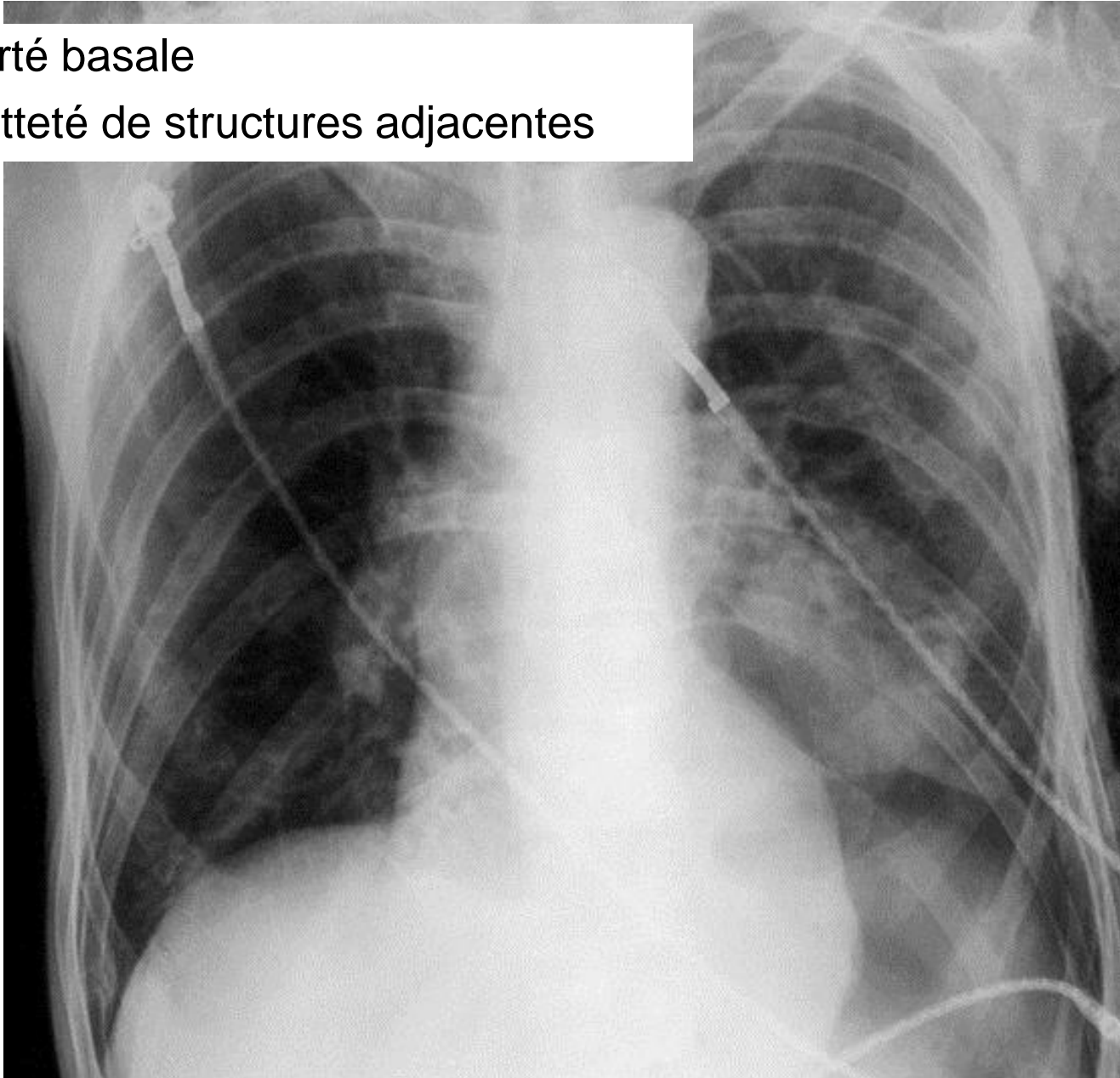
L'air se positionne dans la région la plus anti-déclive :
récessus sous-pulmonaire et antéromédiaux

Pneumothorax



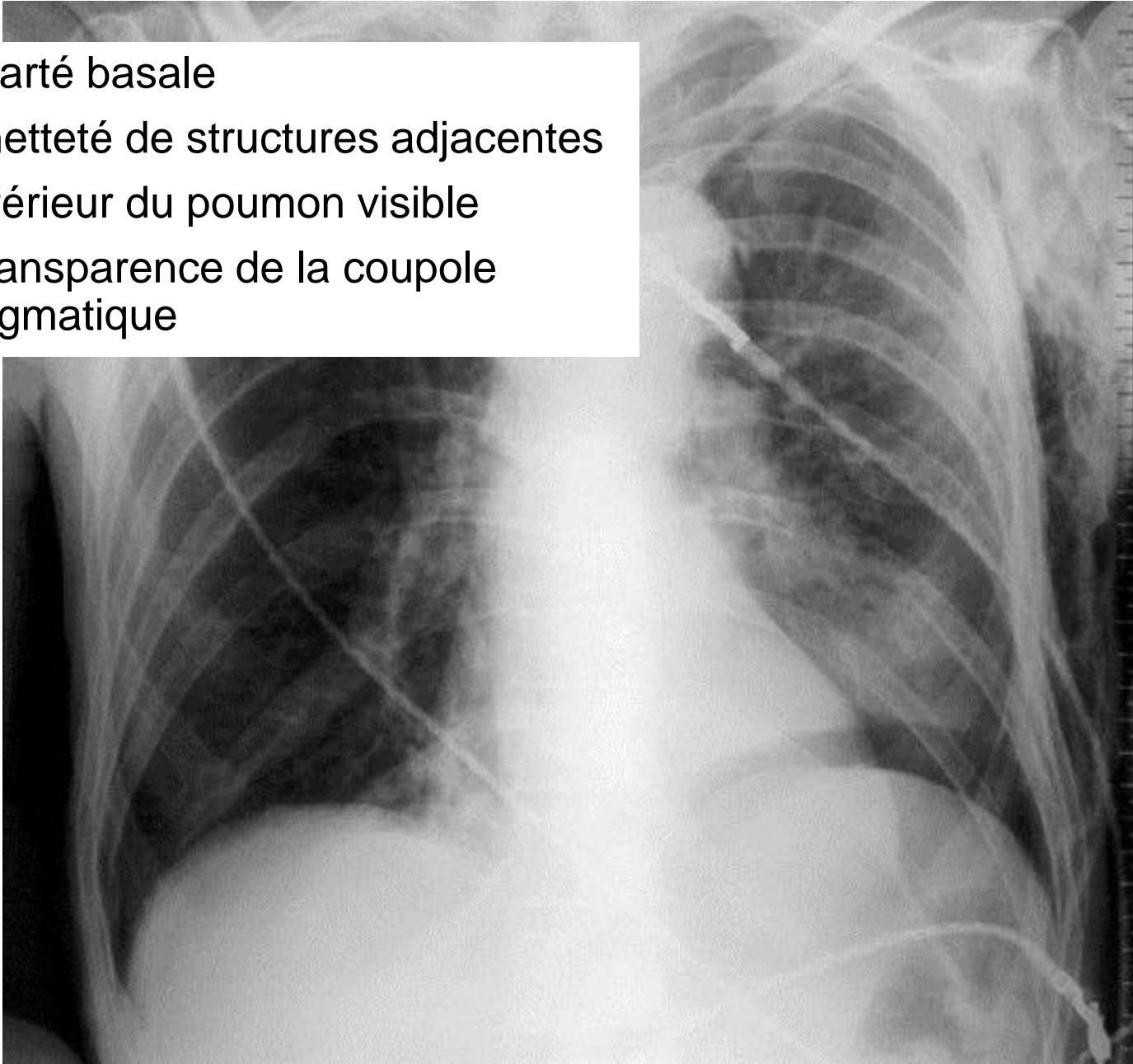
Pneumothorax

- ✓ Hyperclarté basale
- ✓ Hyper netteté de structures adjacentes



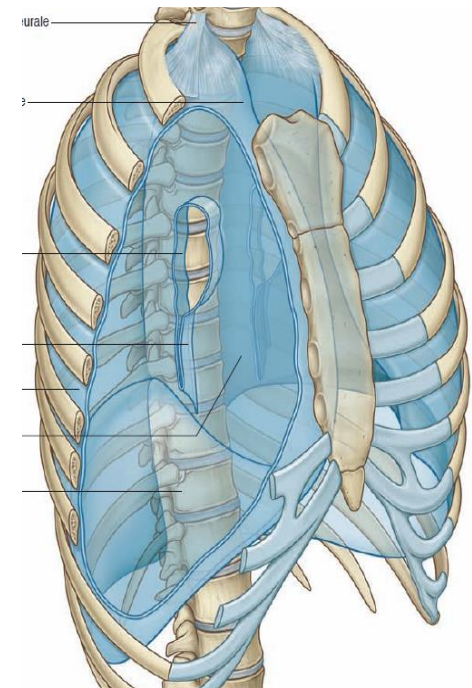
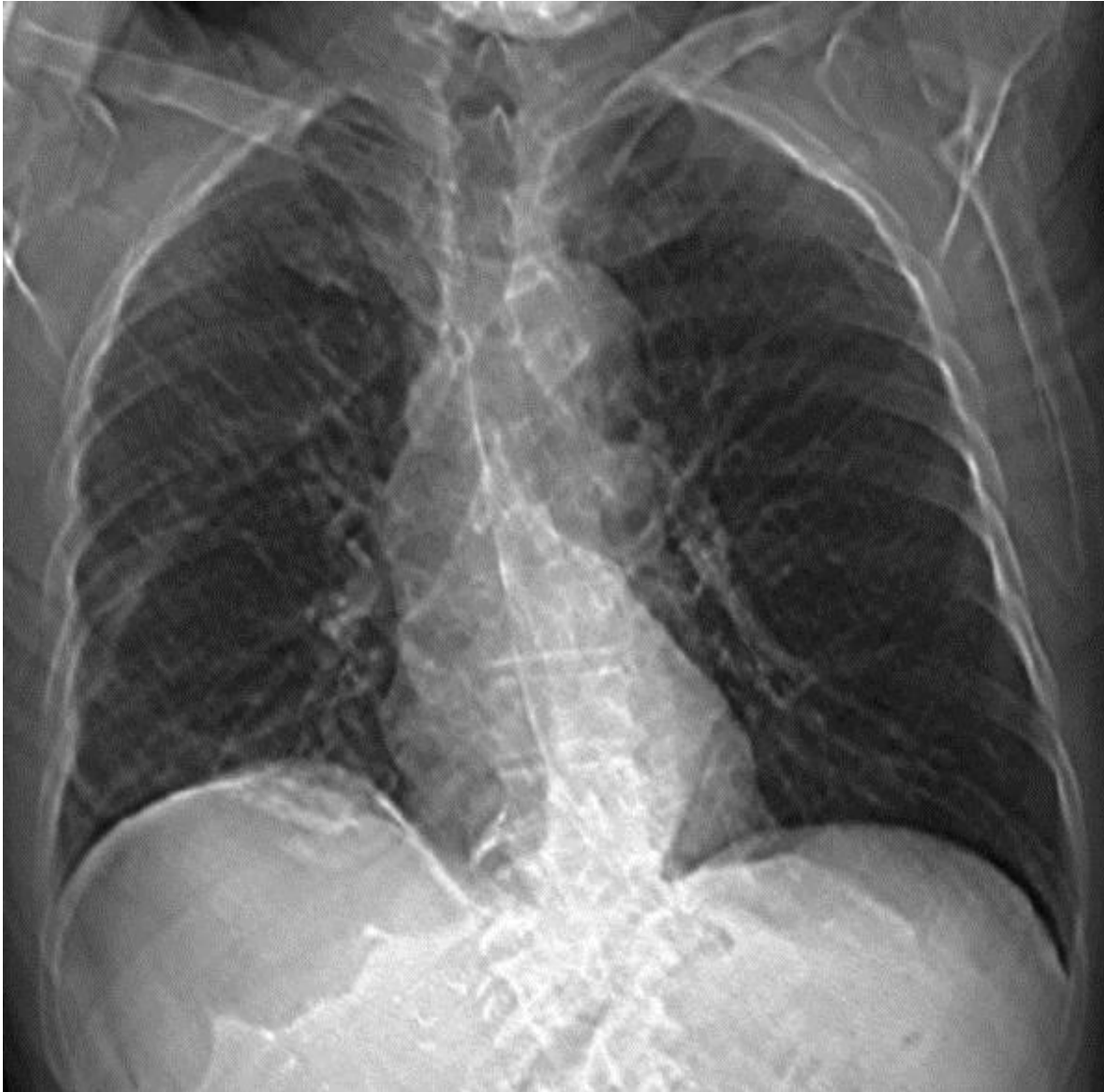Pneumothorax

- ✓ Hyperclarté basale
- ✓ Hyper netteté de structures adjacentes
- ✓ Bord inférieur du poumon visible
- ✓ Hypertransparence de la coupole diaphragmatique

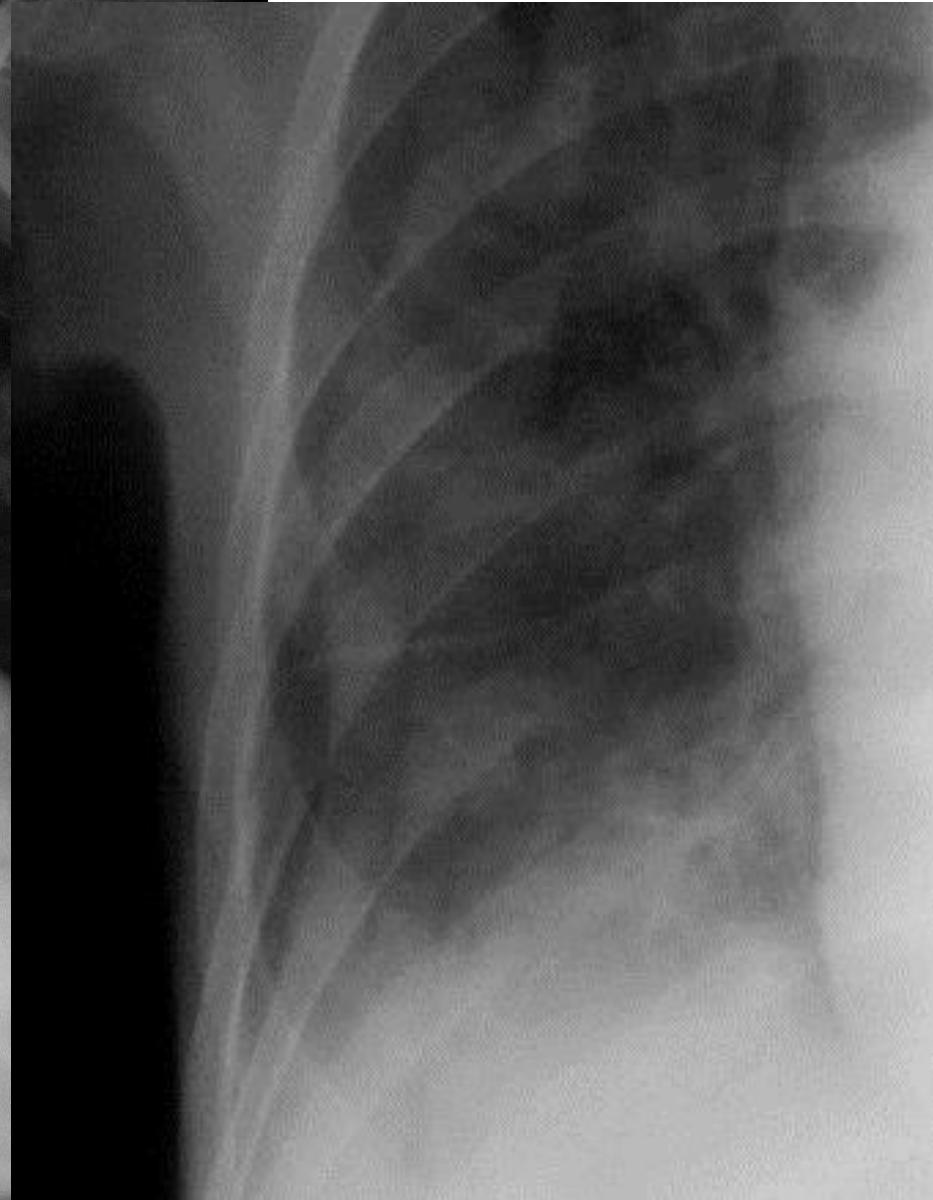
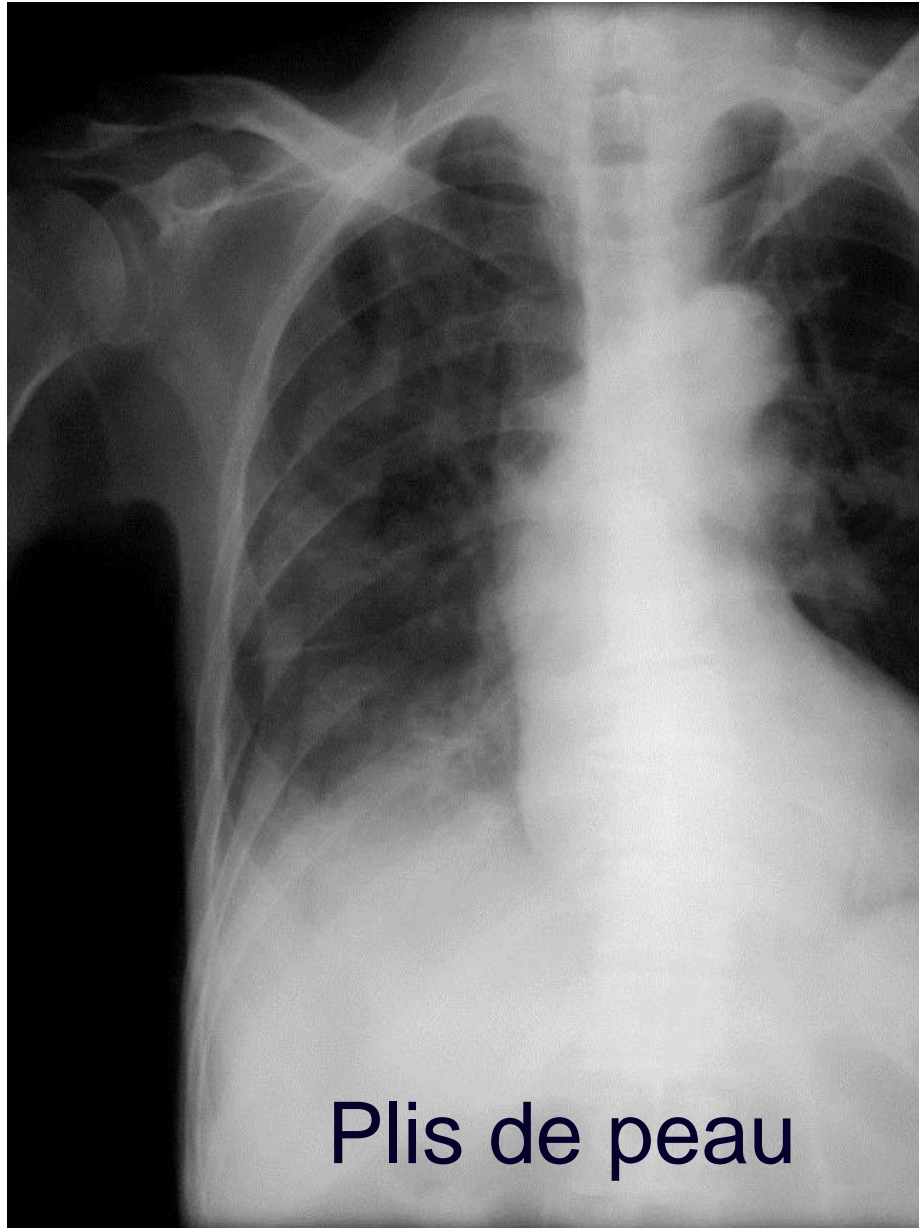


Pneumothorax

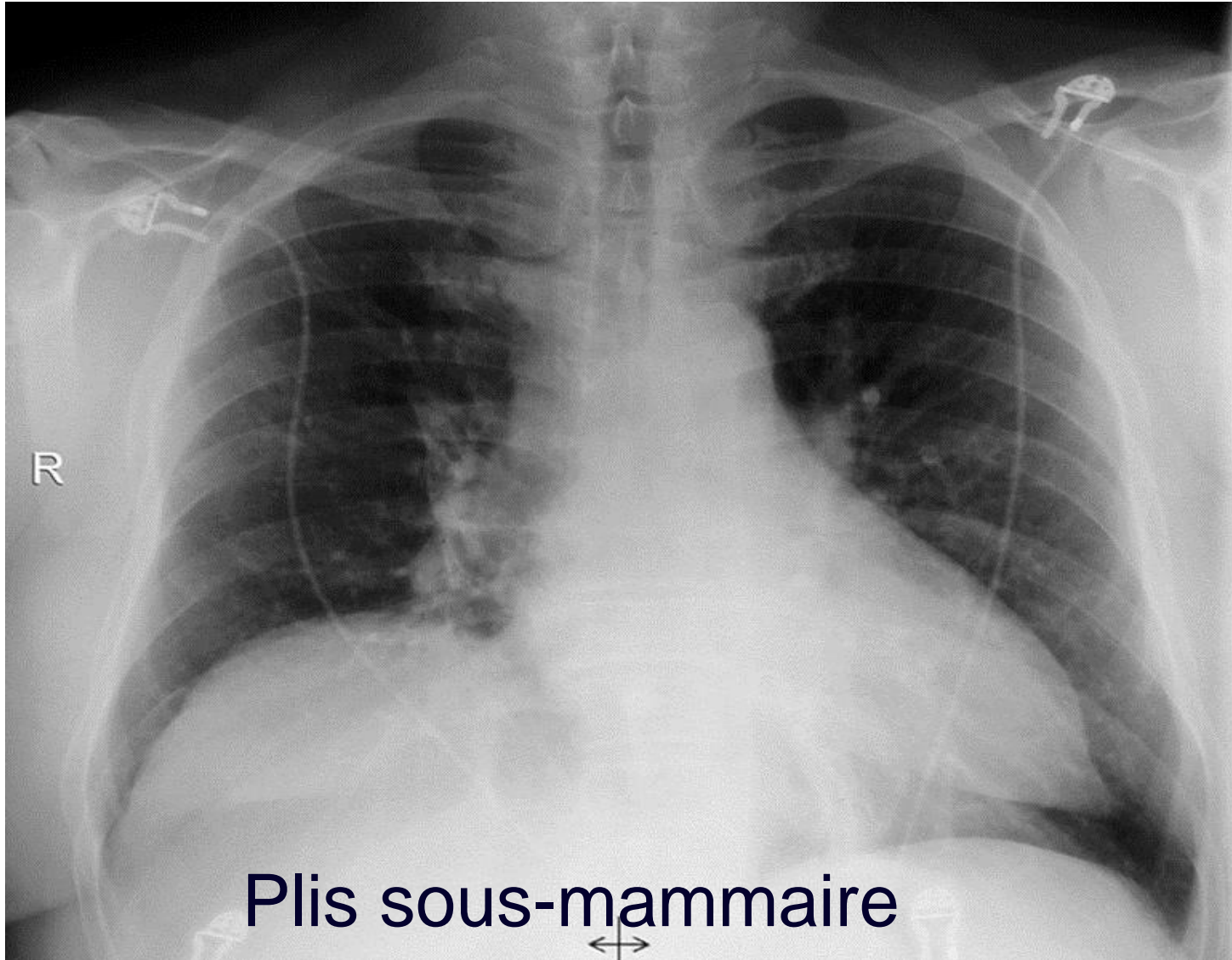
- ✓ Hypertransparence de la coupole diaphragmatique
- ✓ Visibilité de la ligne de réflexion pleurale antérieure



Pneumothorax : pièges !!!!

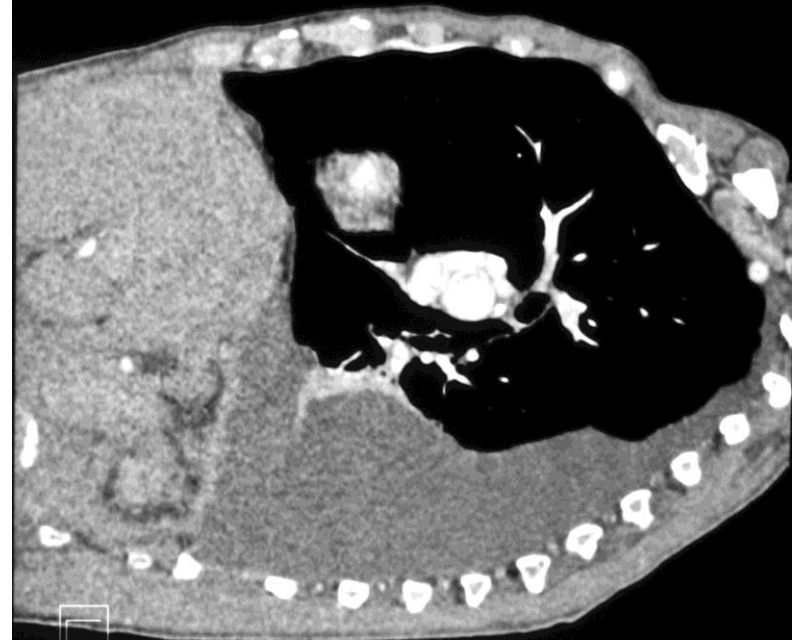

Pneumothorax : pièges !!!!



Epanchement pleural

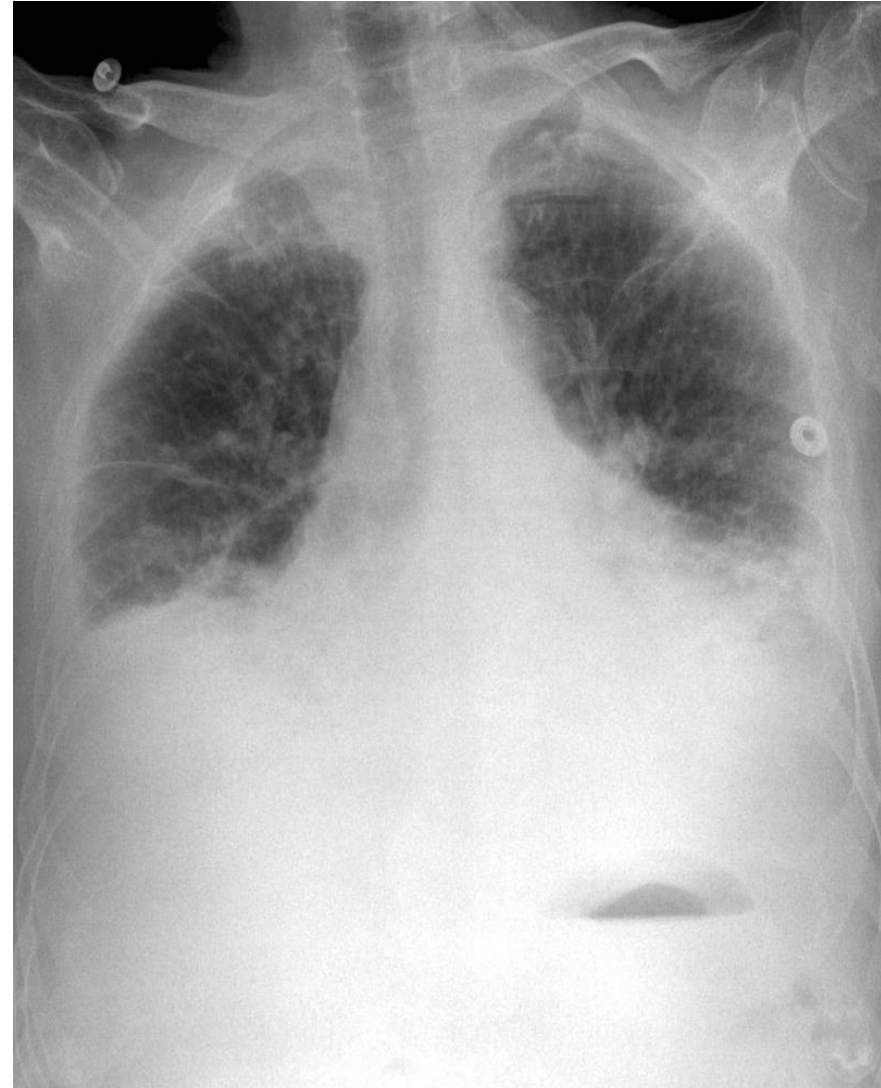
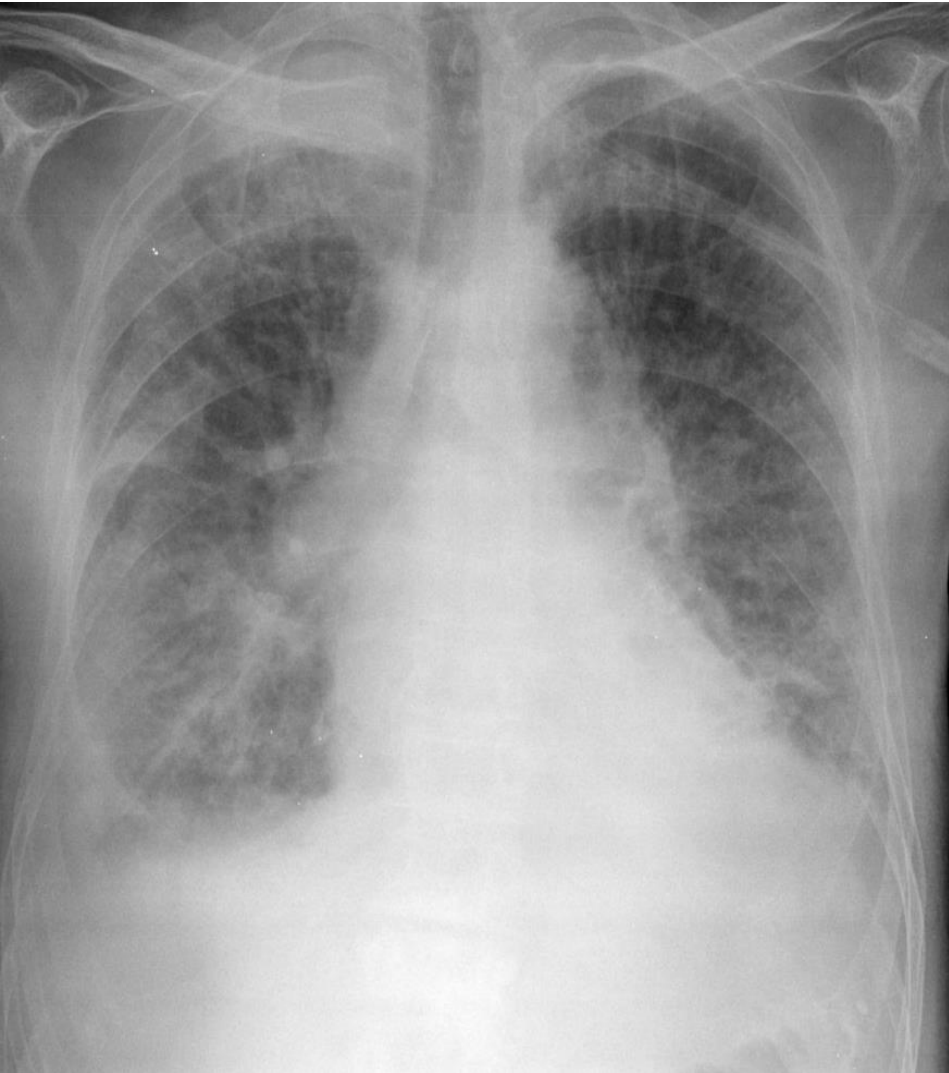
- Liquide → zone la plus déclive



→ position couchée → région postérieure

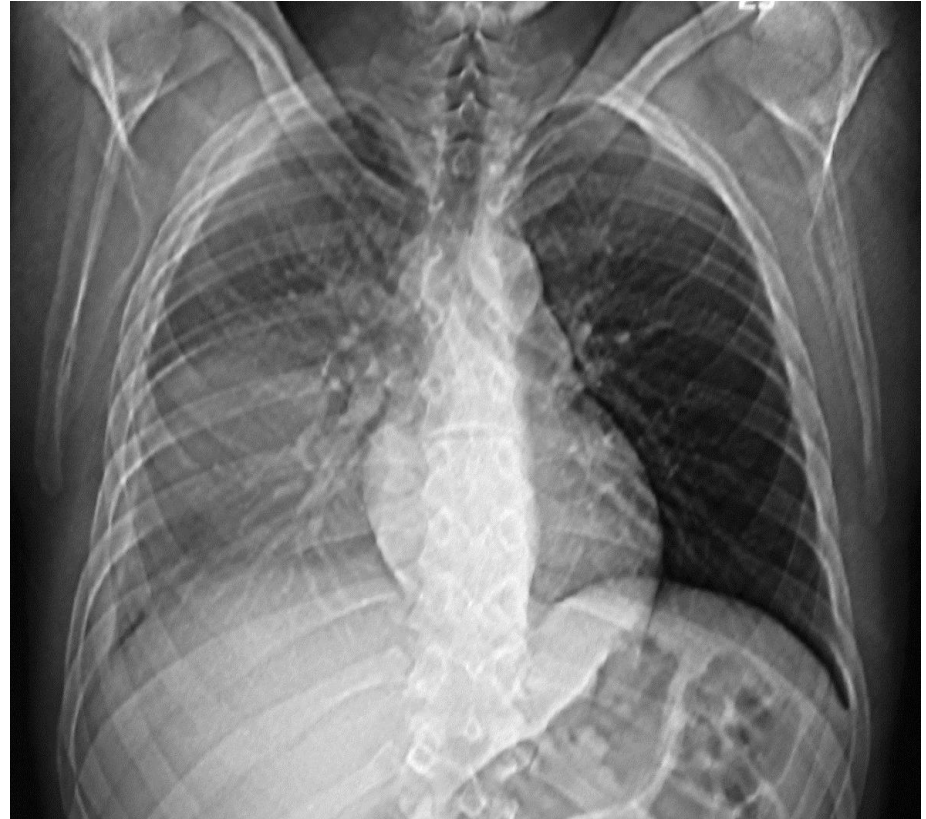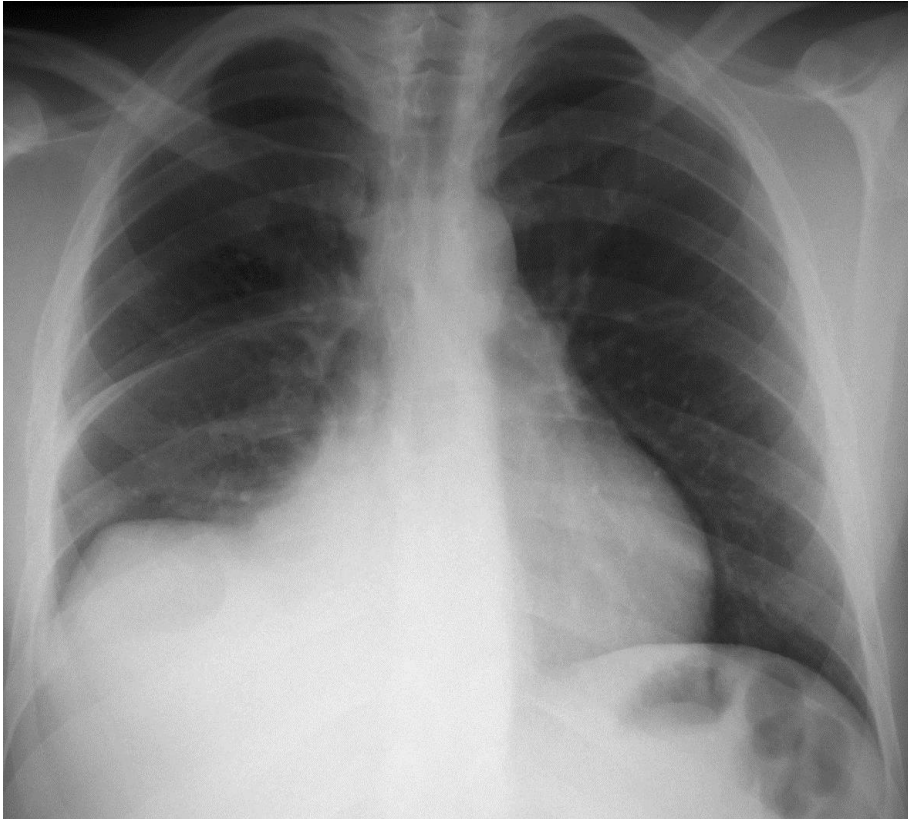
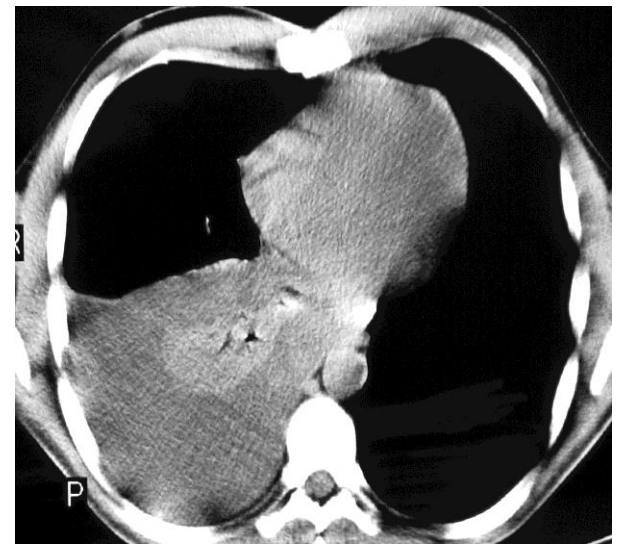
- ◆ Opacité accrue de l'hémithorax
- ◆ Visibilité préservée des vaisseaux
- ◆ Perte des limites de la coupole
- ◆ Coiffe apicale
- ◆ Liquide dans les scissures

Epanchement pleural Couché - assis

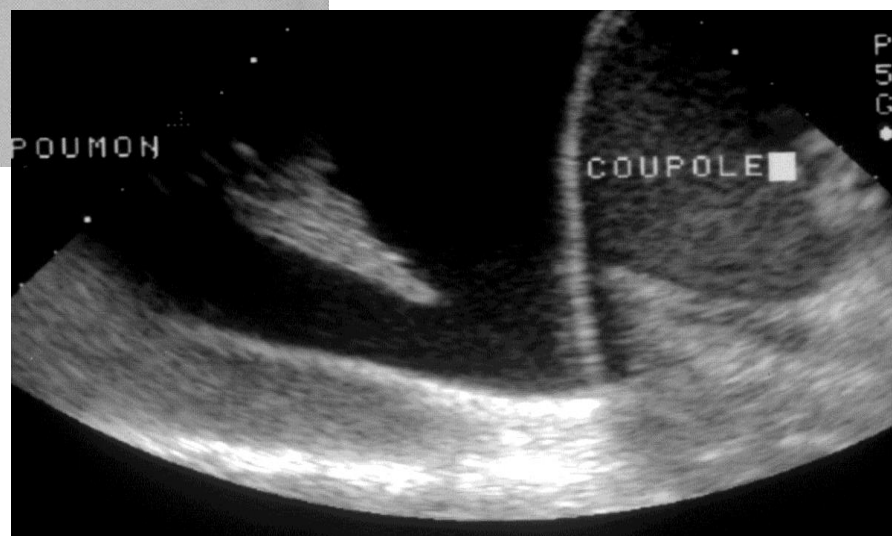
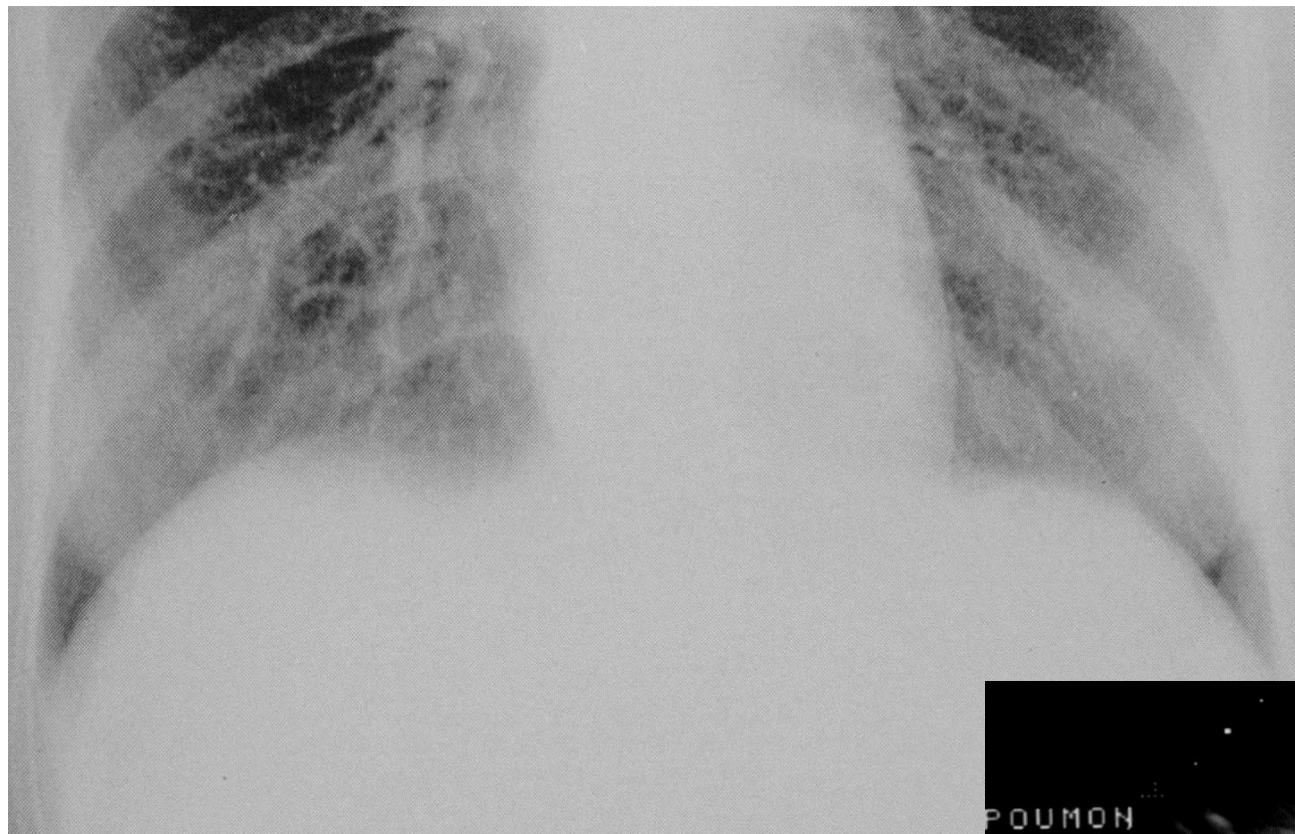


Epanchement pleural Debout - couché

Epanchement sous-pulmonaire

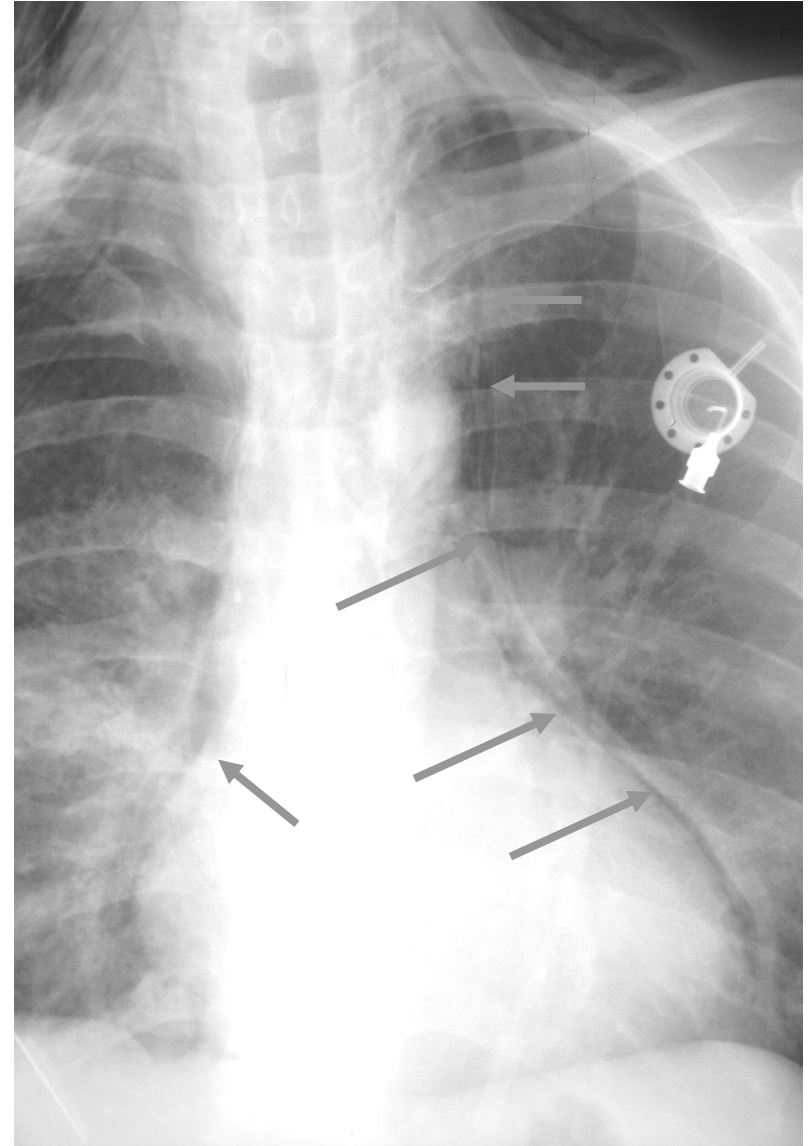


Epanchement pleural

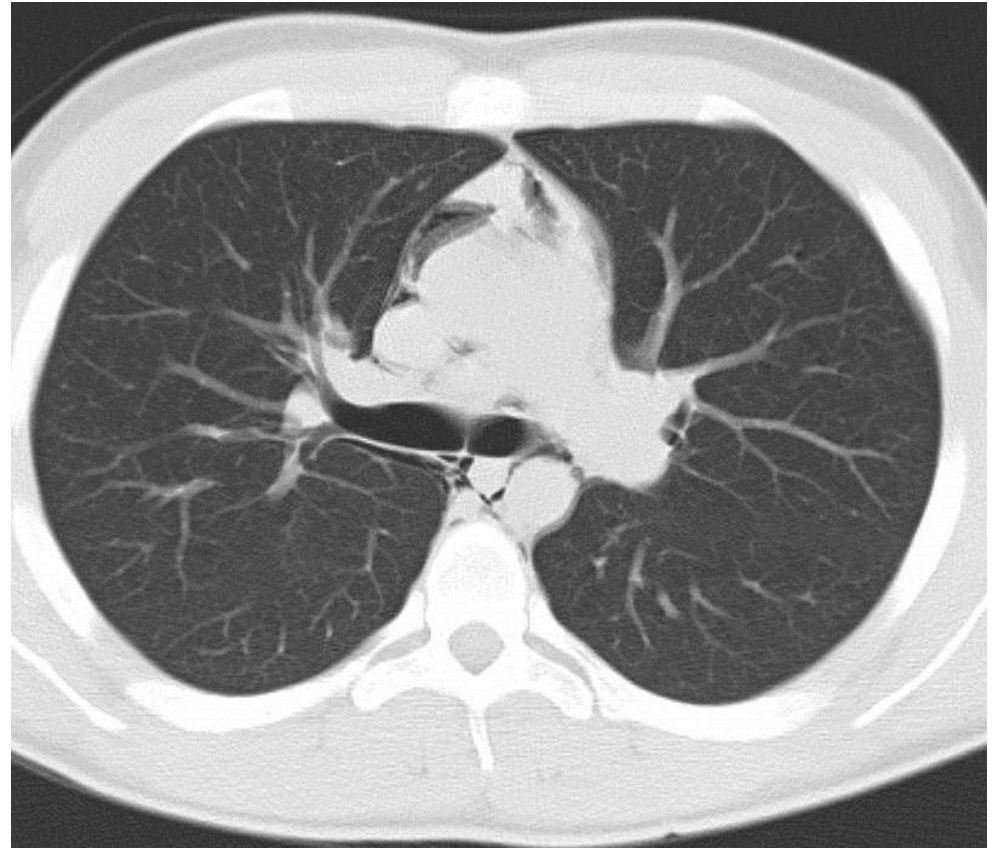
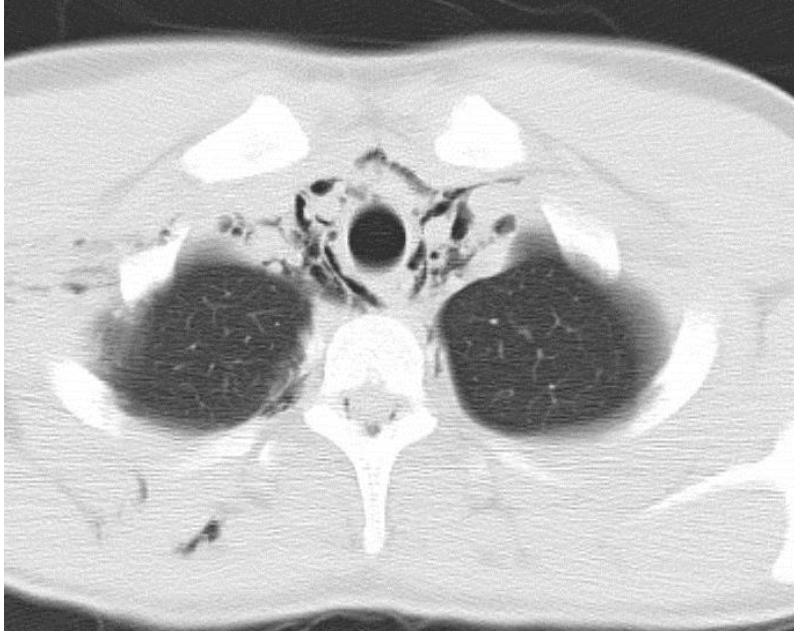

Pneumomédiastin

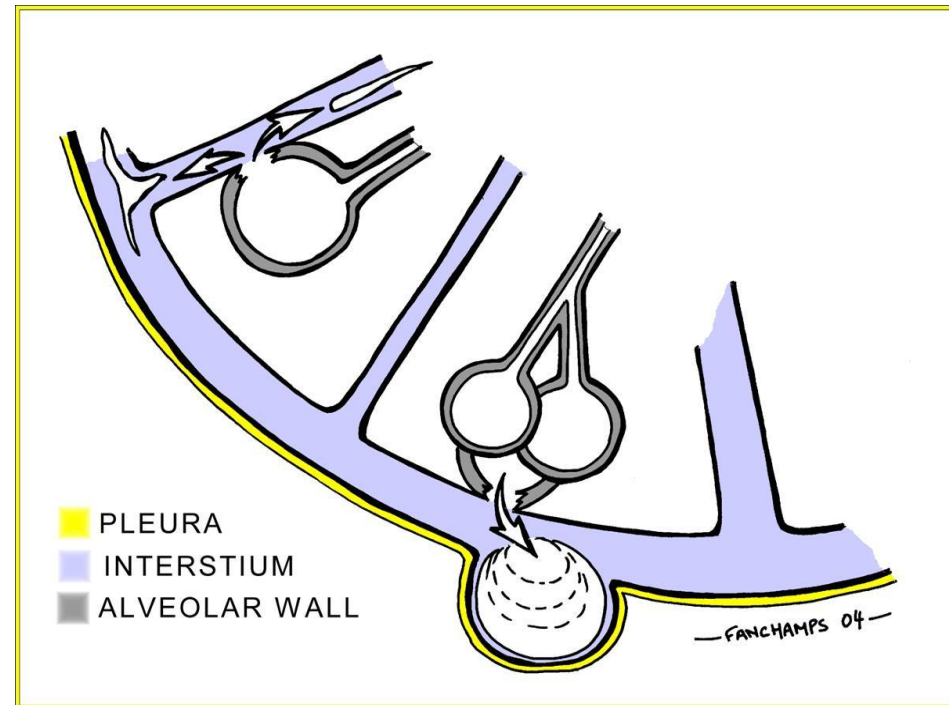
Air intramédiastinal se présentant sous la forme de fines hyperclartés linéaires verticales, disséquant la graisse médiastinale



Pneumomédiastin

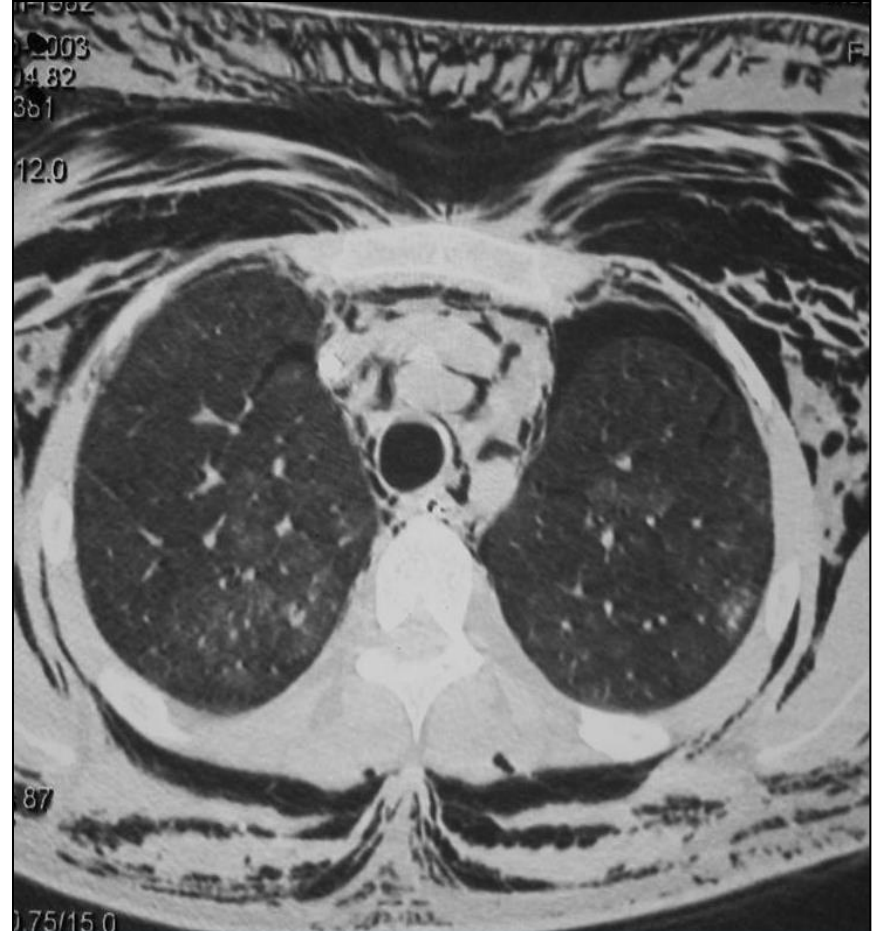
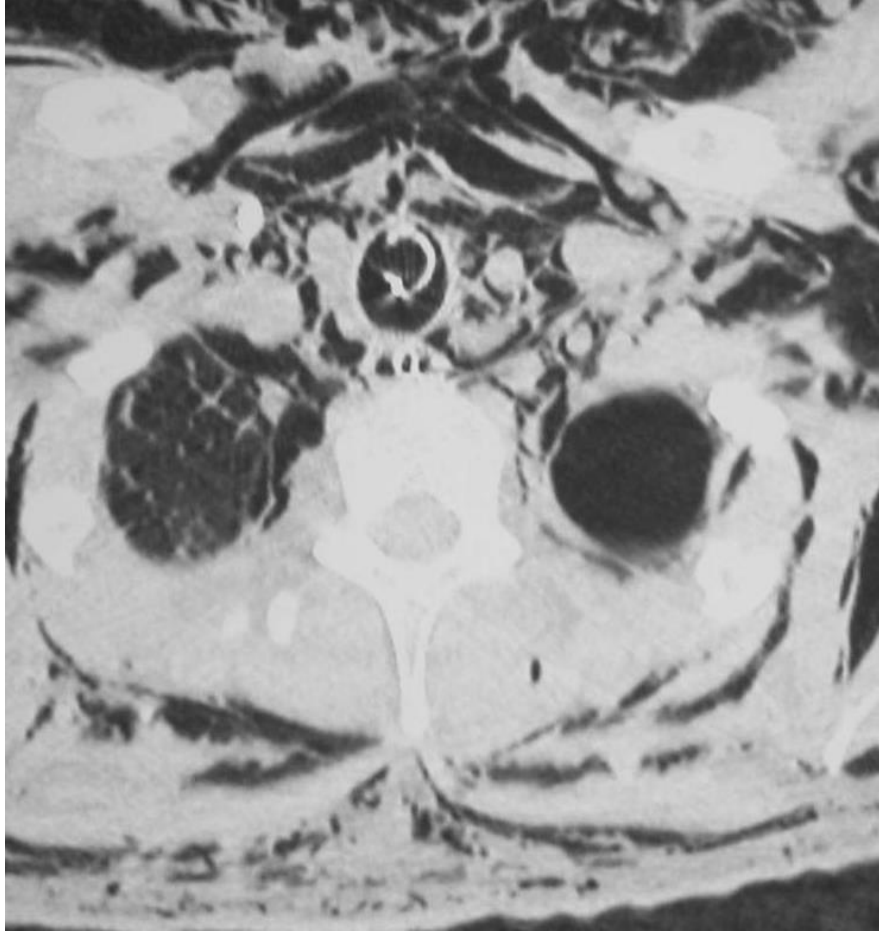


Pneumomédiastin



- < 2 % résultent de lésions oesophagiennes ou trachéobronchiques
- Extension d'un emphysème cervical ou abdominal
- > 95% : effet Macklin

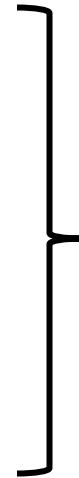Pneumomédiastin



Pneumomédiastin

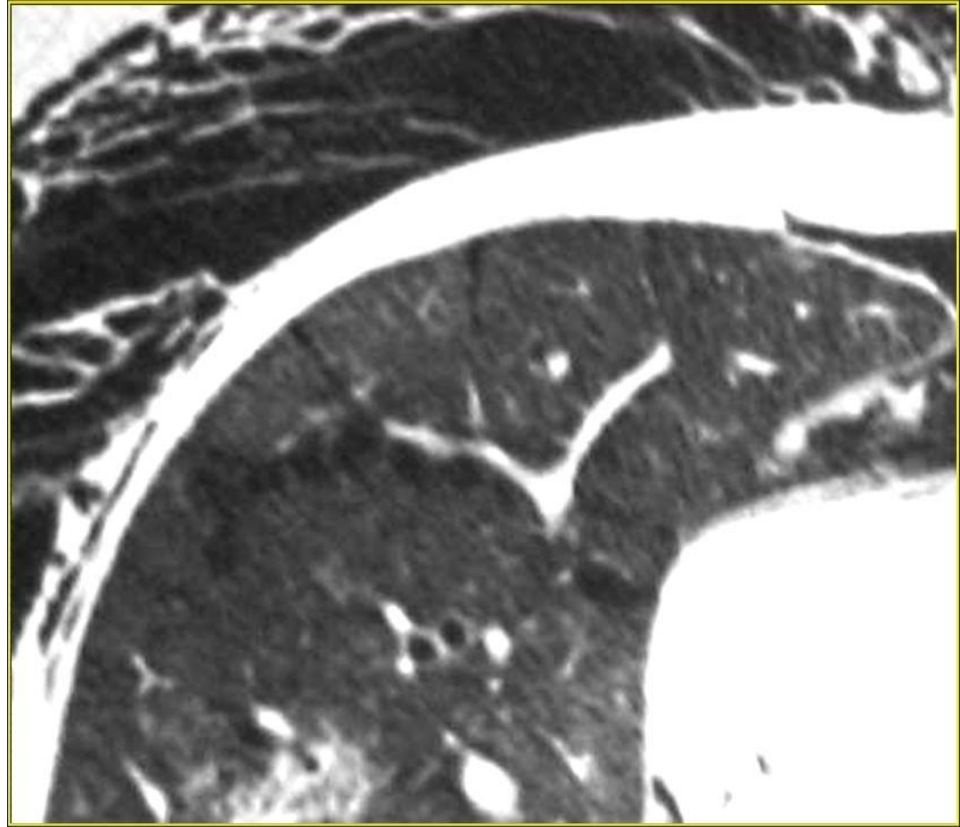
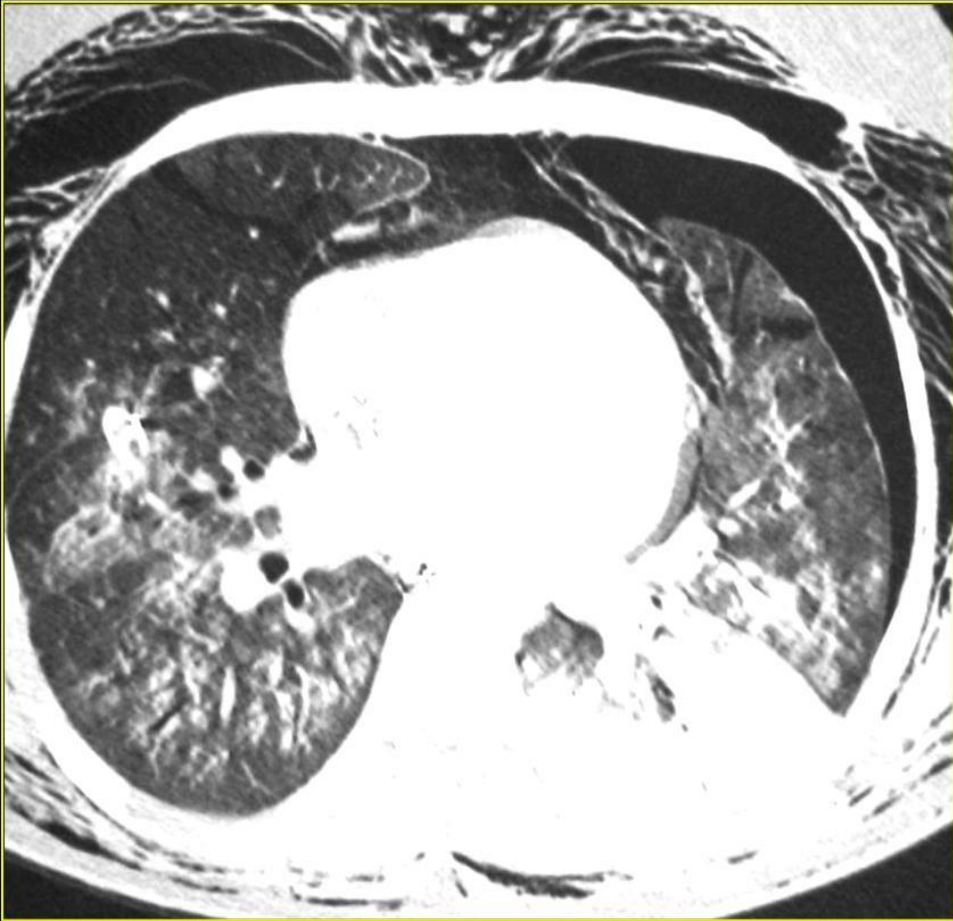
Complications de l'effet Macklin et de la ventilation mécanique

- pneumomediastinum
- pneumothorax
- pneumopericardium
- pneumoperitoneum
- rarement embolie gazeuse

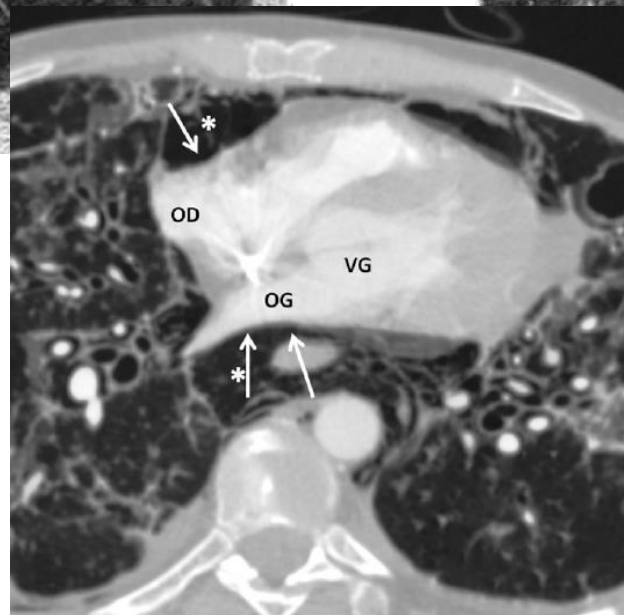
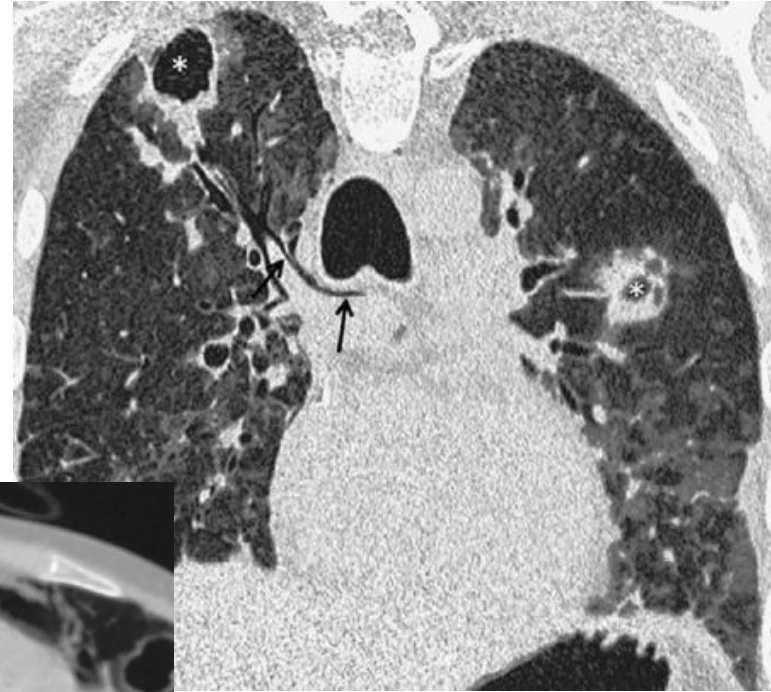
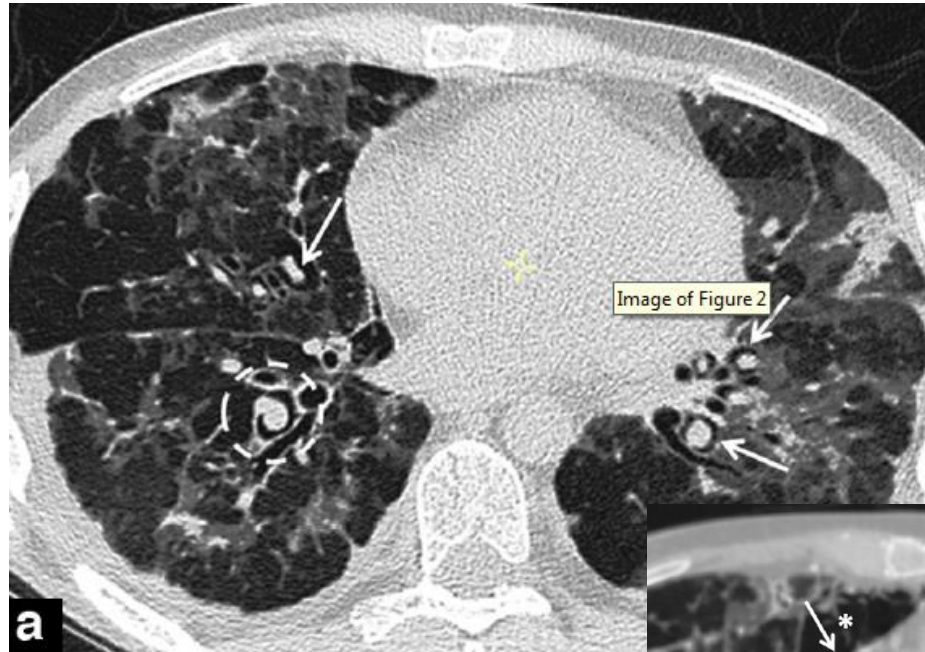

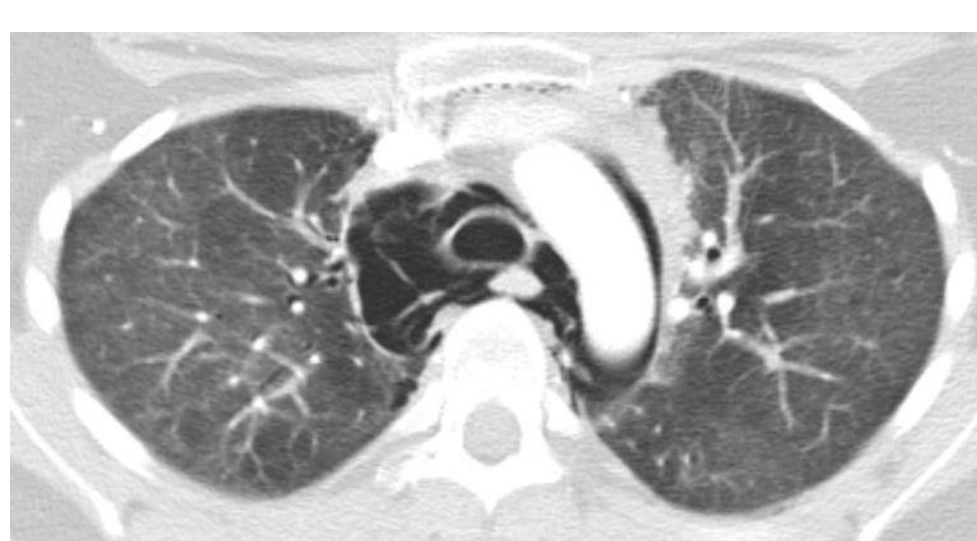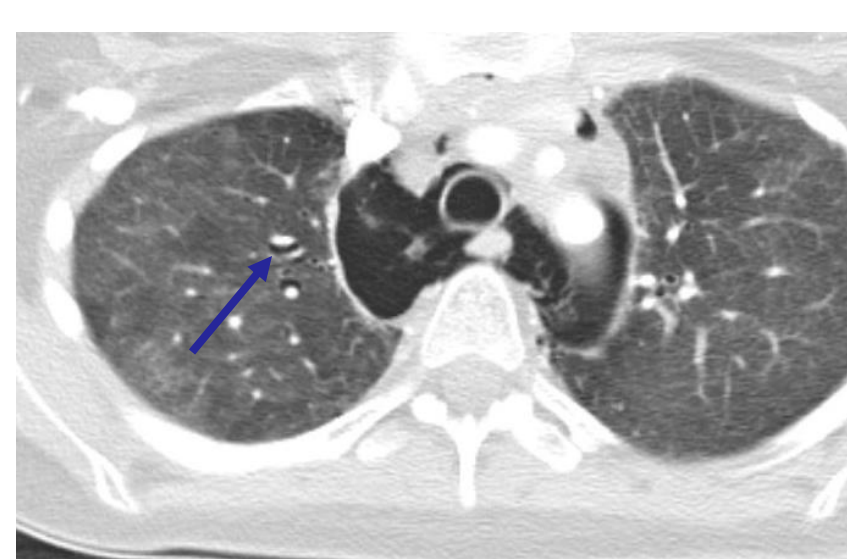
Sous tension

Pneumomédiastin sous tension

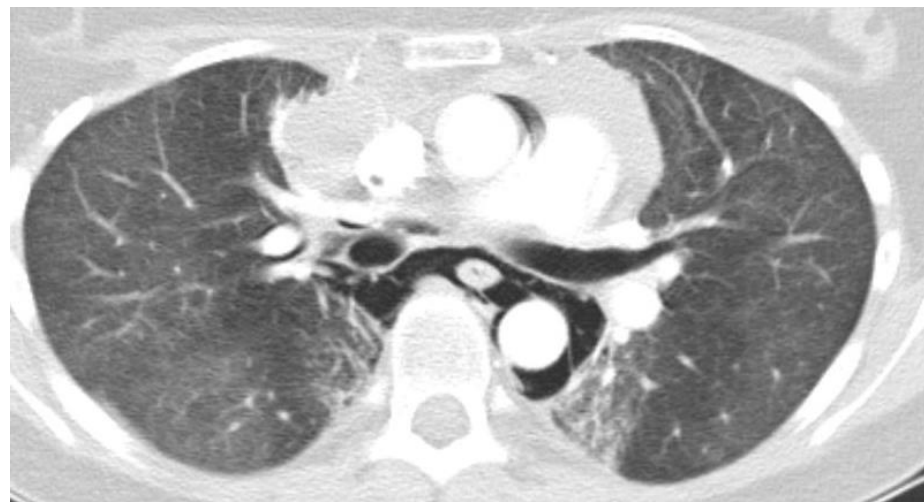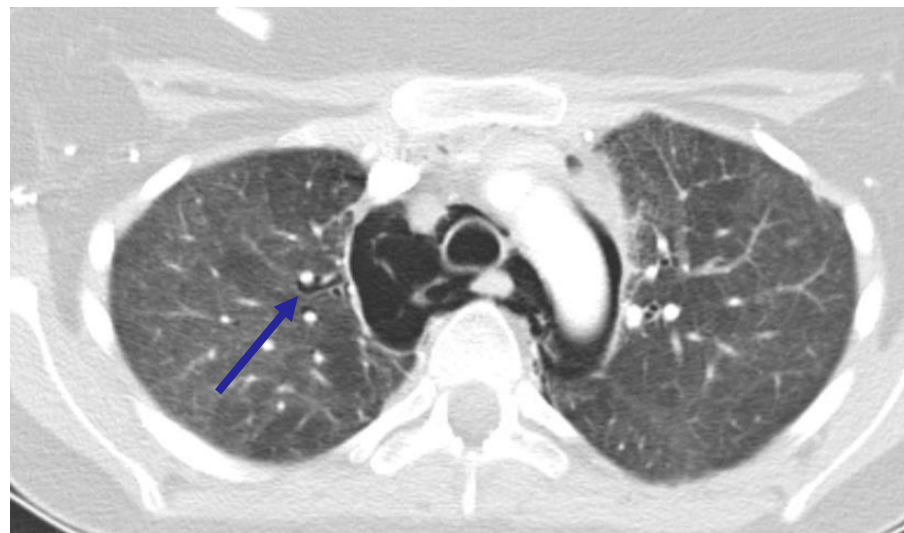


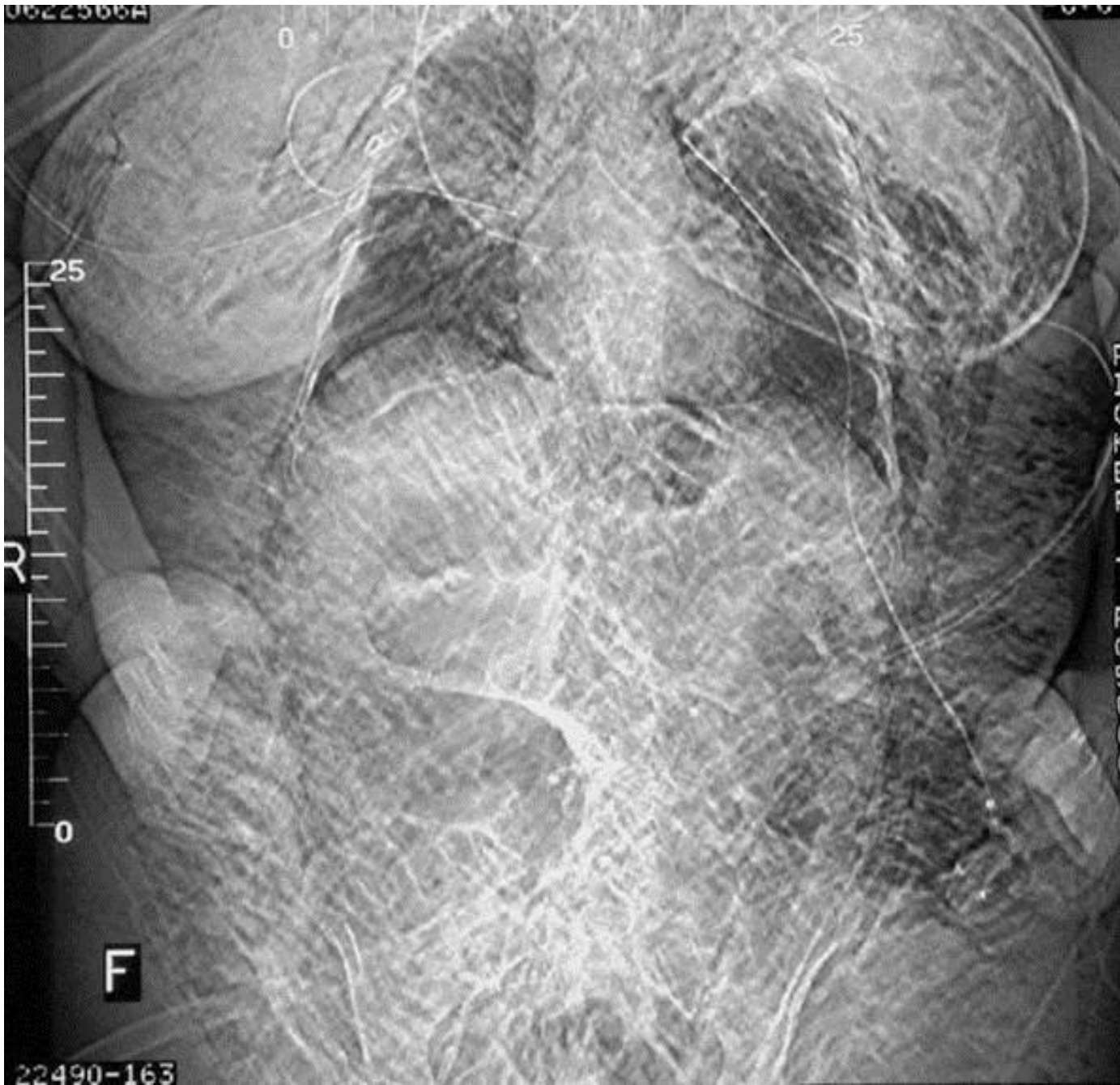
Pneumomédiastin sous tension





Pneumomédiastin dû à un effet Macklin





0022306A

0

25

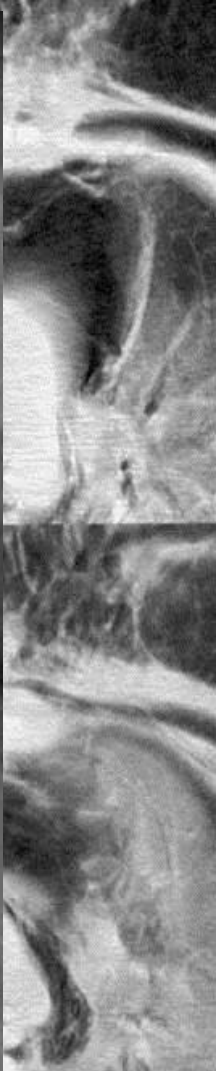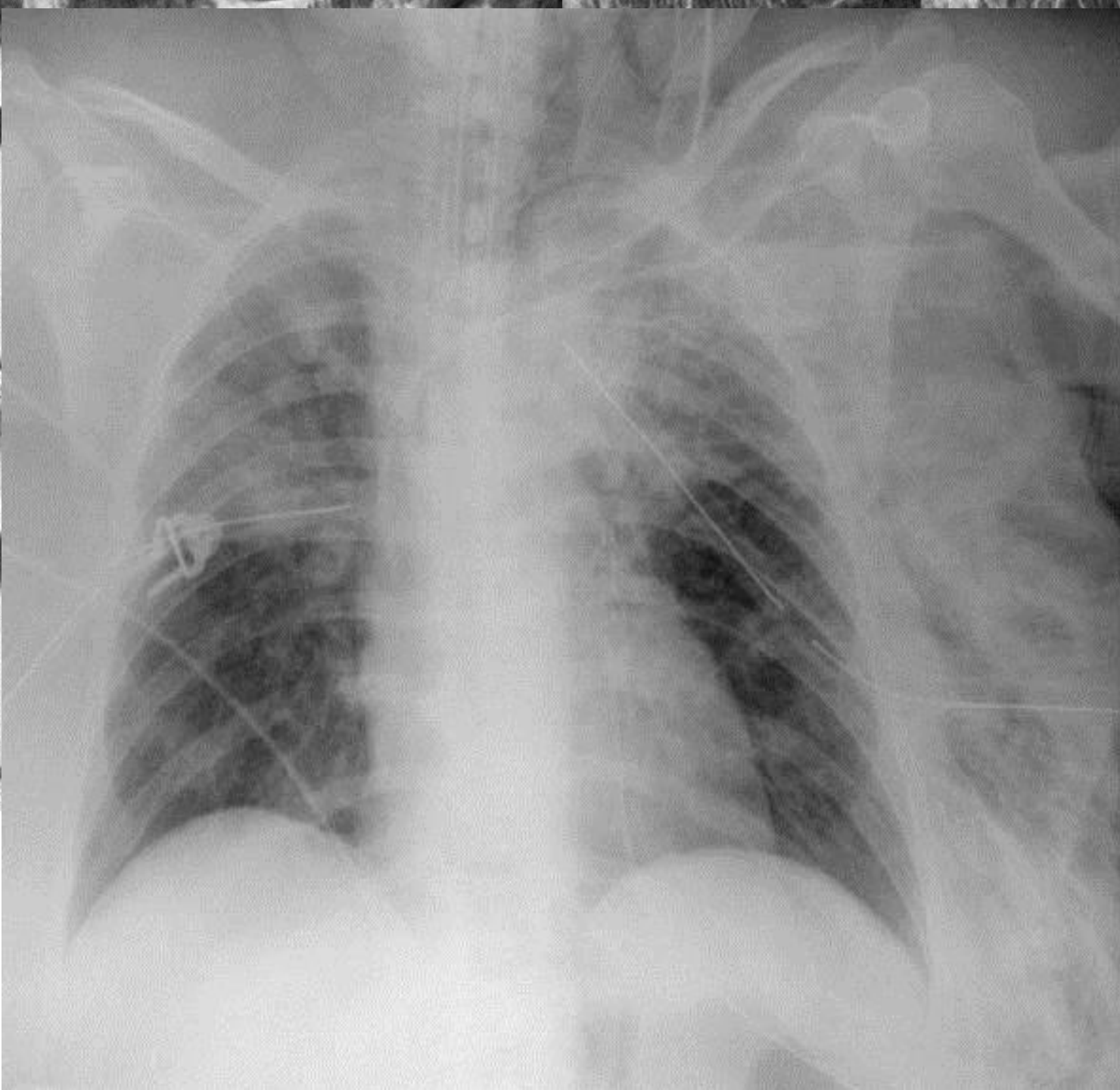
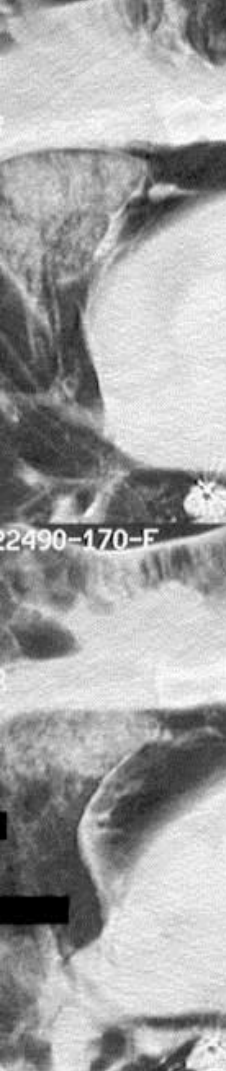
25

R

0

F

22490-163

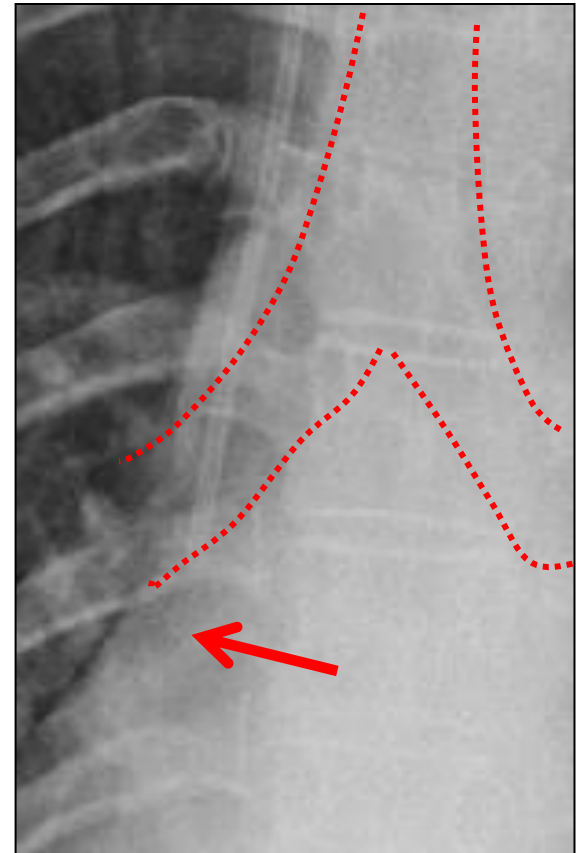
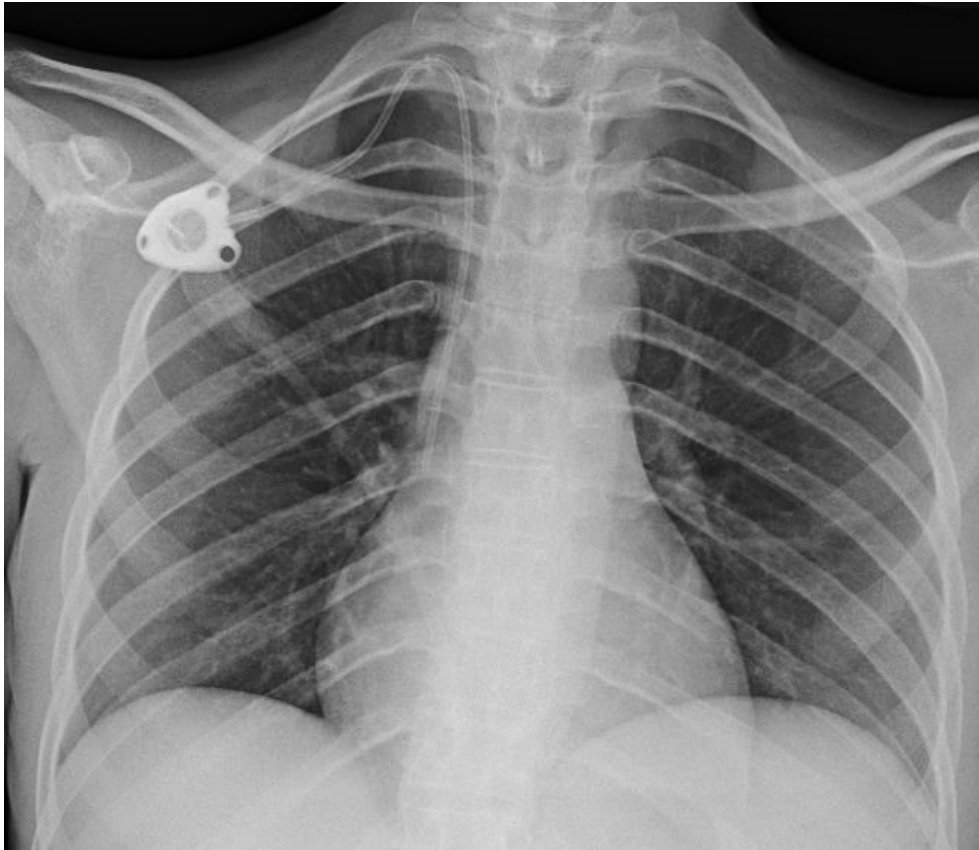


Cathéters,
drains,
tubes,
etc...

Cathéters centraux

- Position idéale = jonction VCS- atrium D

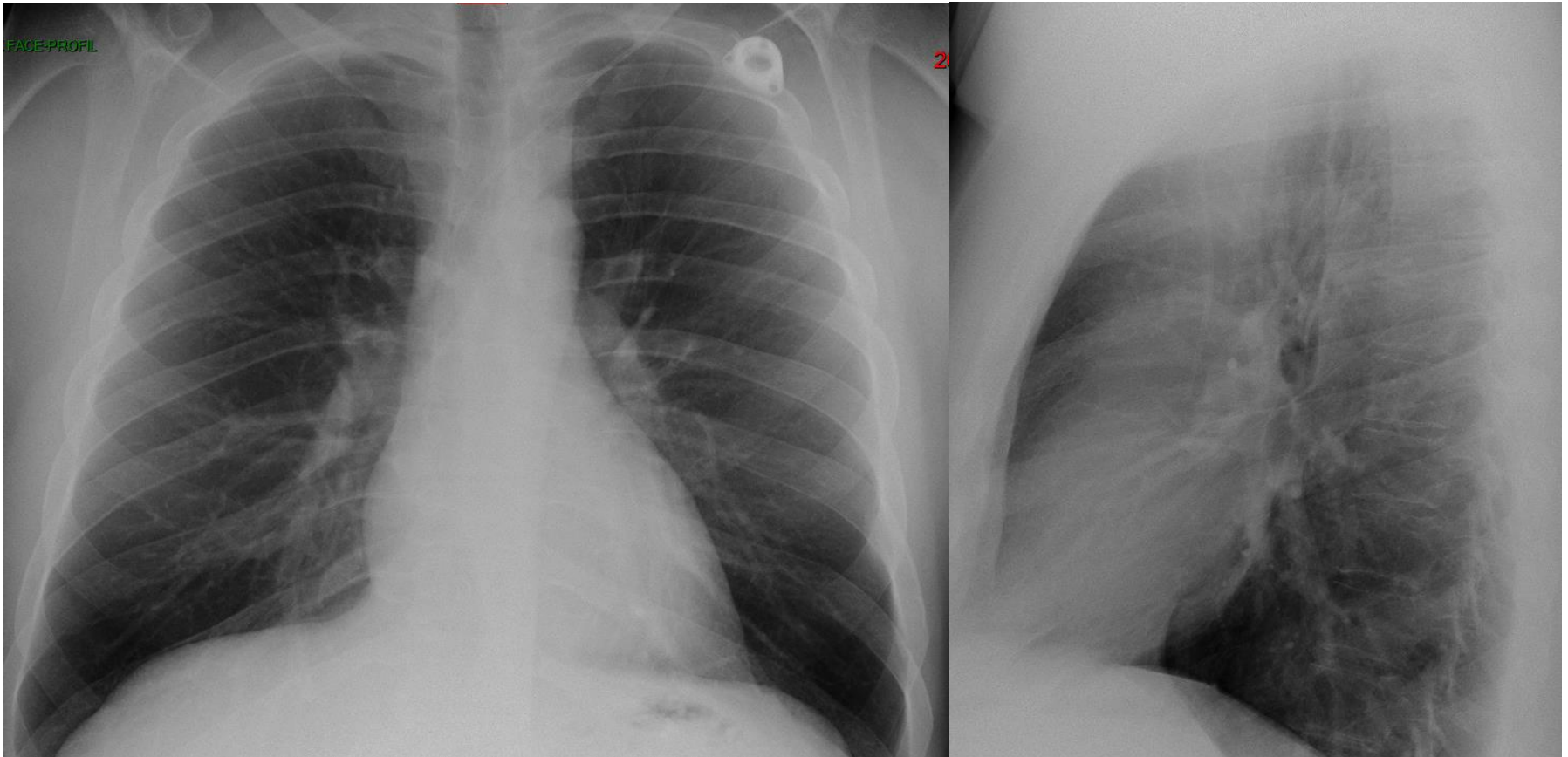
VCS 1 cm sous la clarté de la bronche souche D



Cathéters centraux

- Position idéale = jonction VCS- atrium D

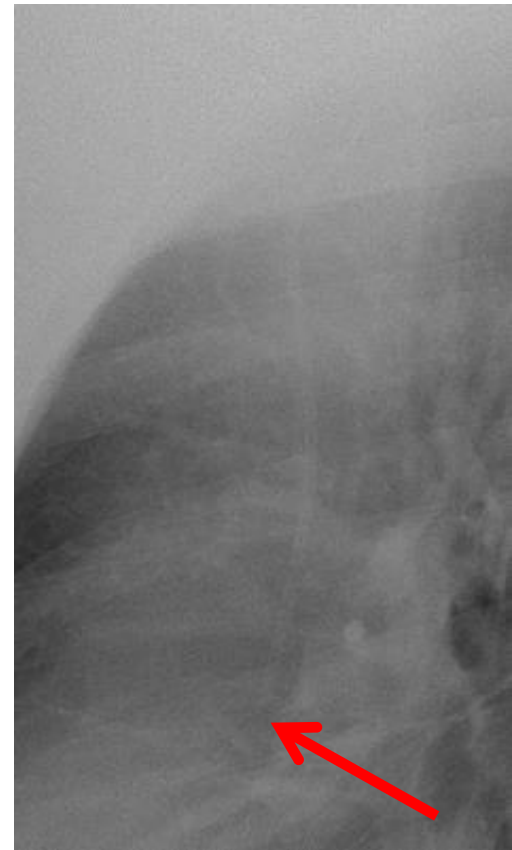
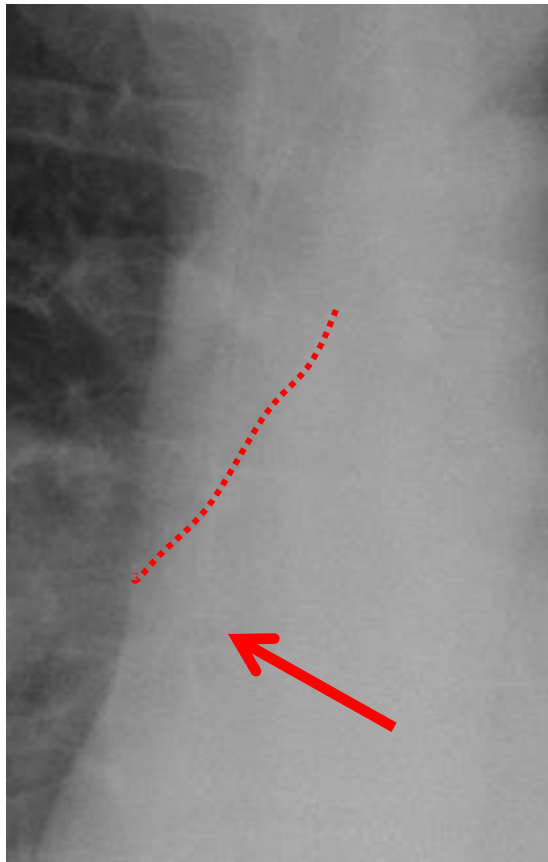
VCS 1 cm sous la clarté de la bronche souche D

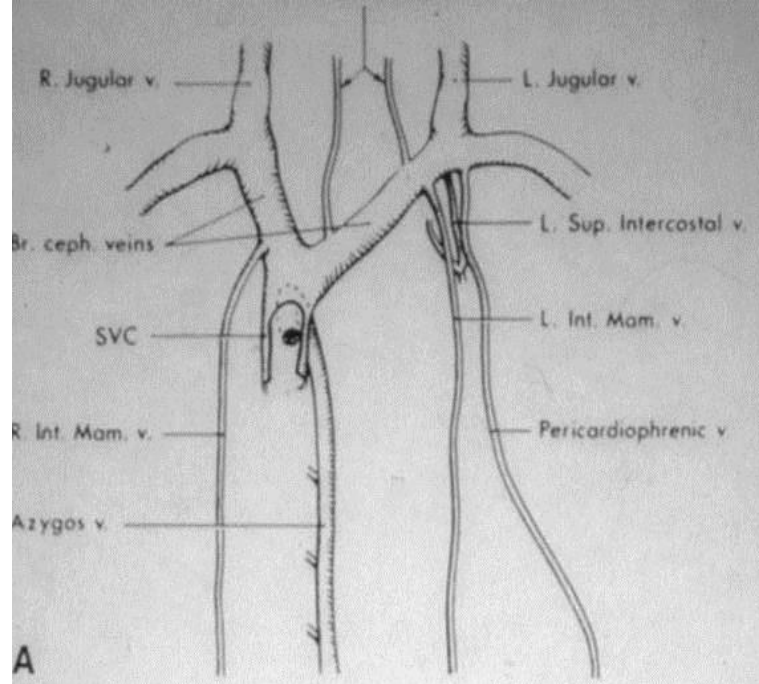


Cathéters centraux

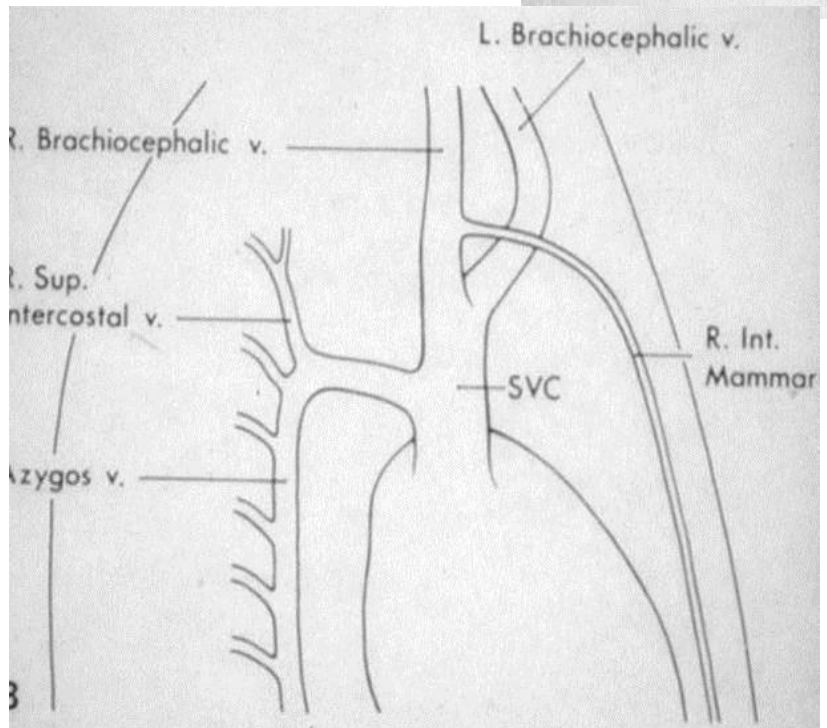
- Position idéale = jonction VCS- atrium D

VCS 1 cm sous la clarté de la bronche souche D

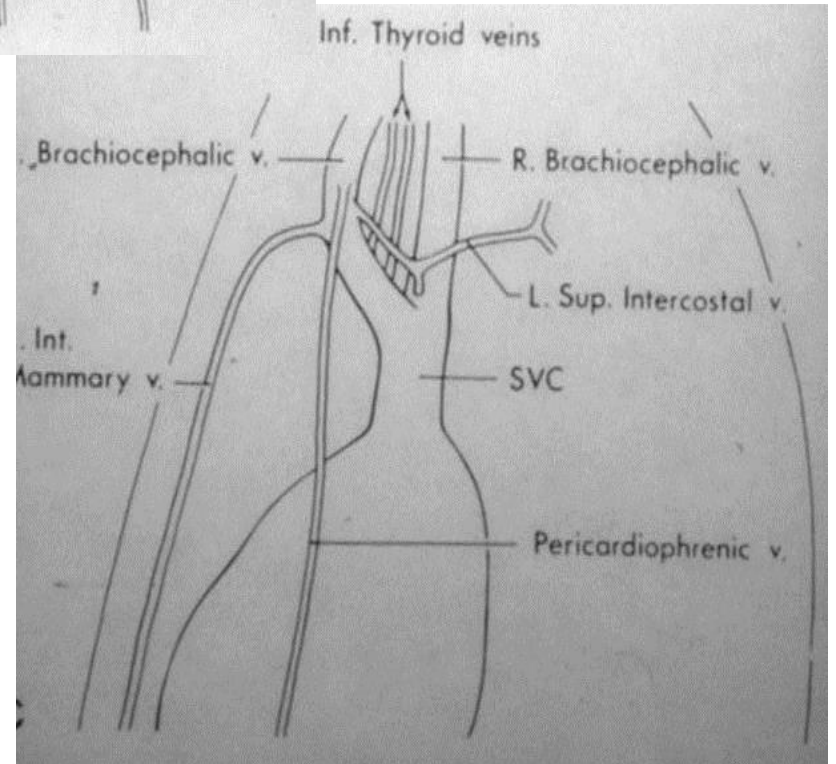




A



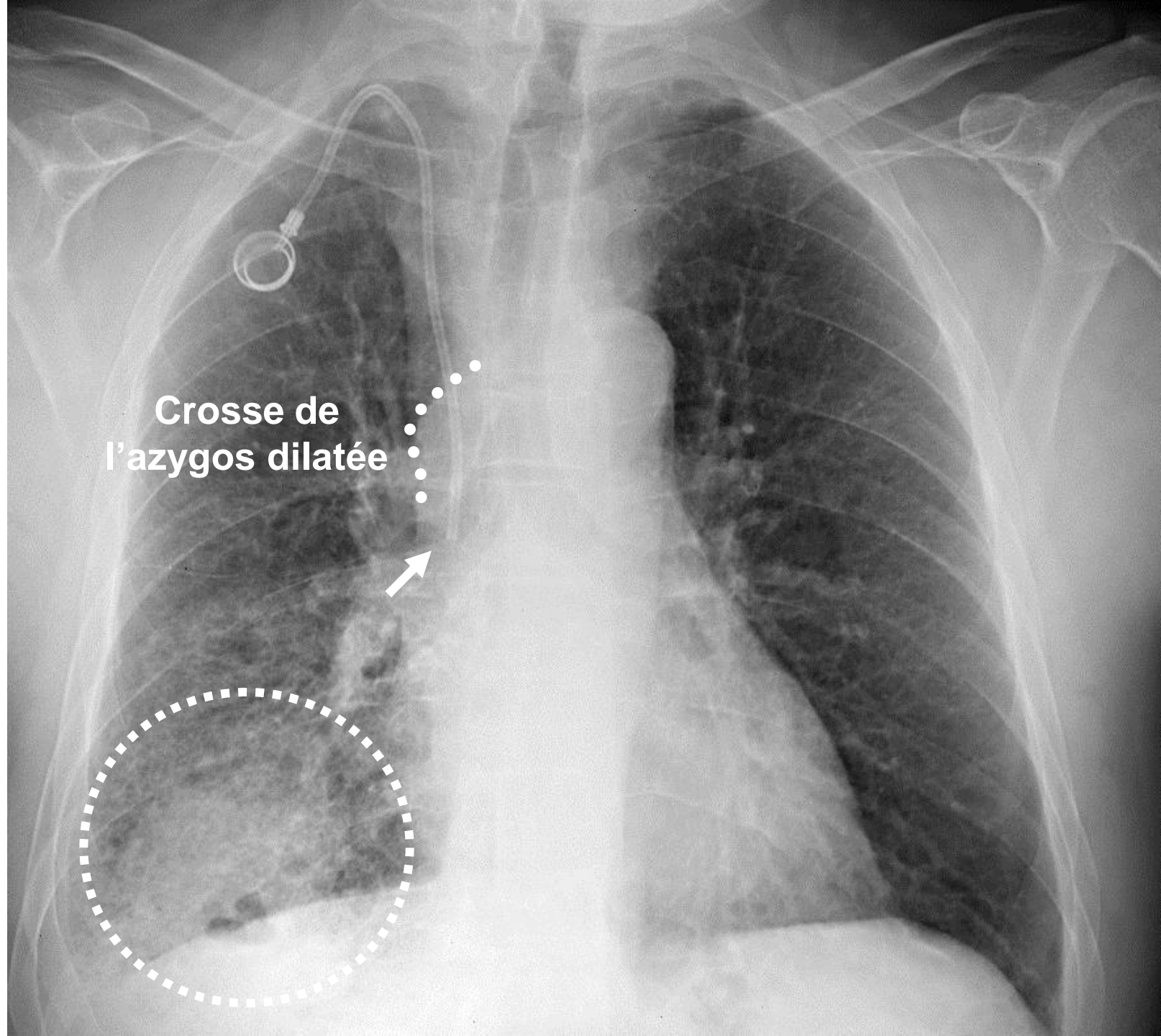
B



C

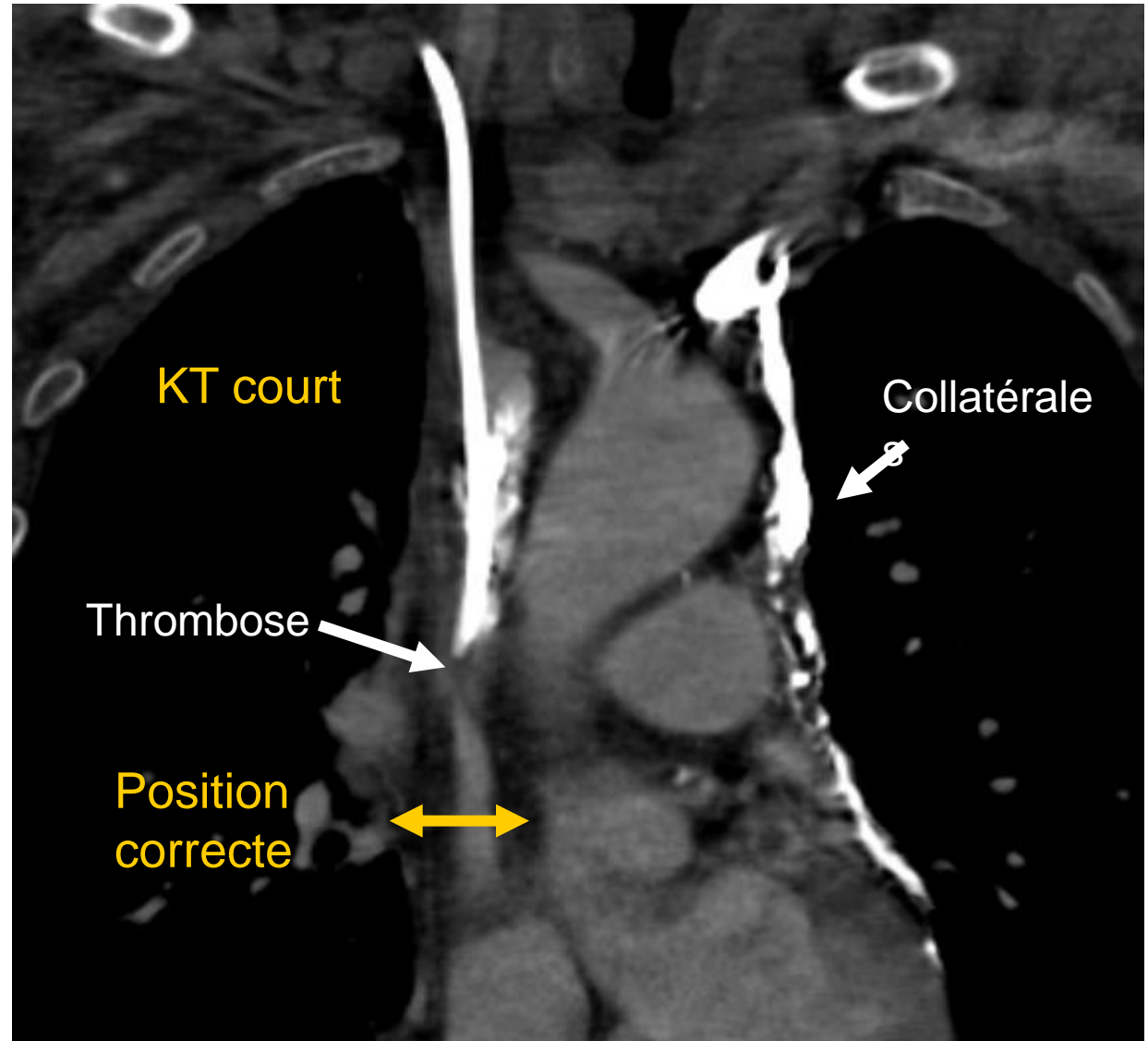
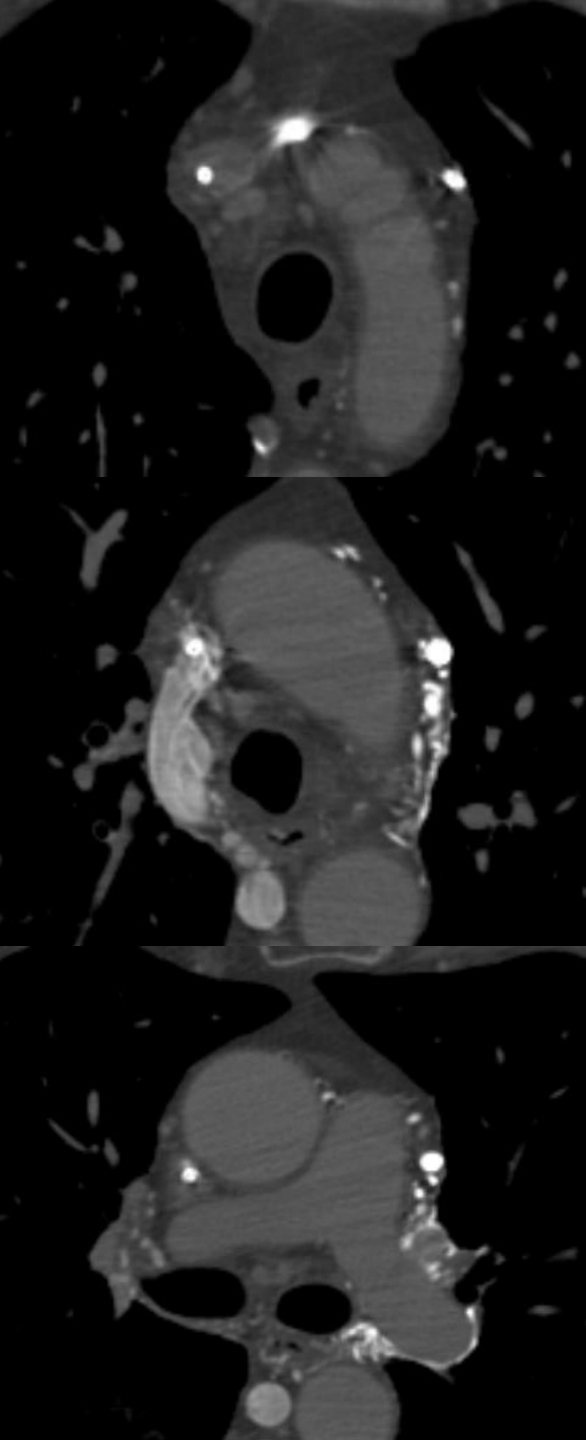
Cathéters centraux

- Position idéale = jonction VCS- atrium D
 - VCS 1 cm sous la clarté de la bronche souche D
- En cas de doute : - cliché de profil
 - injection de produit de contraste par le cathéter
- Malposition : ~ 50%
- Complications :
 - pneumothorax
 - lésions vasculaires (perforation, thrombose)
 - infection
 - plicature, écrasement et fragmentation

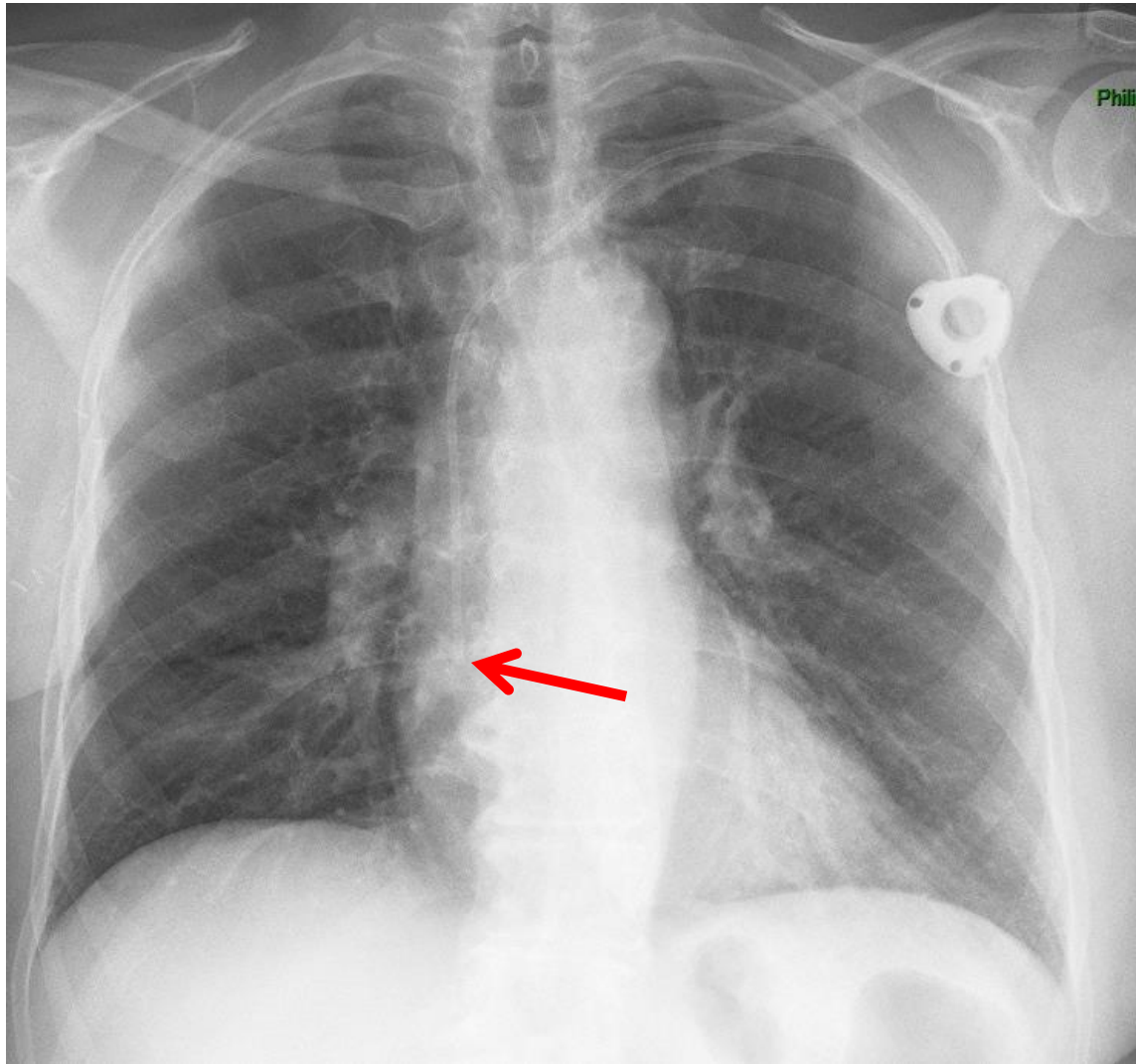


Crosse de
l'azygos dilatée

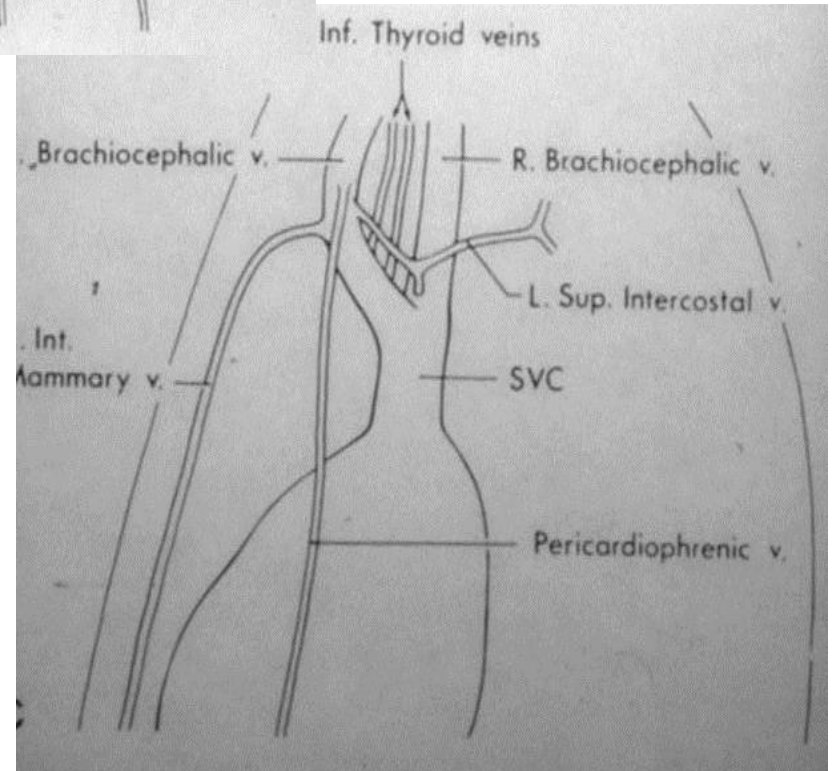
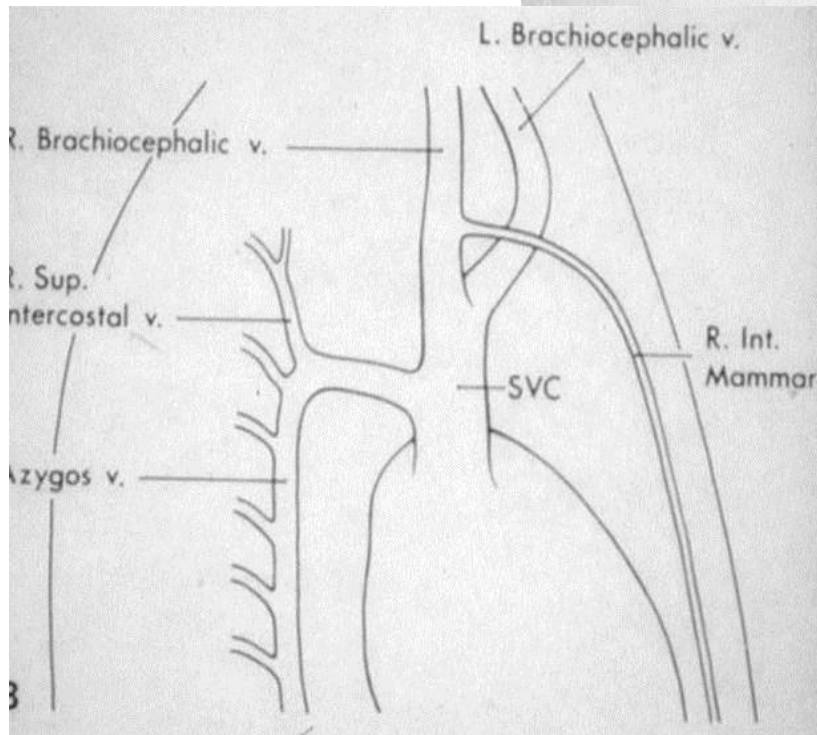
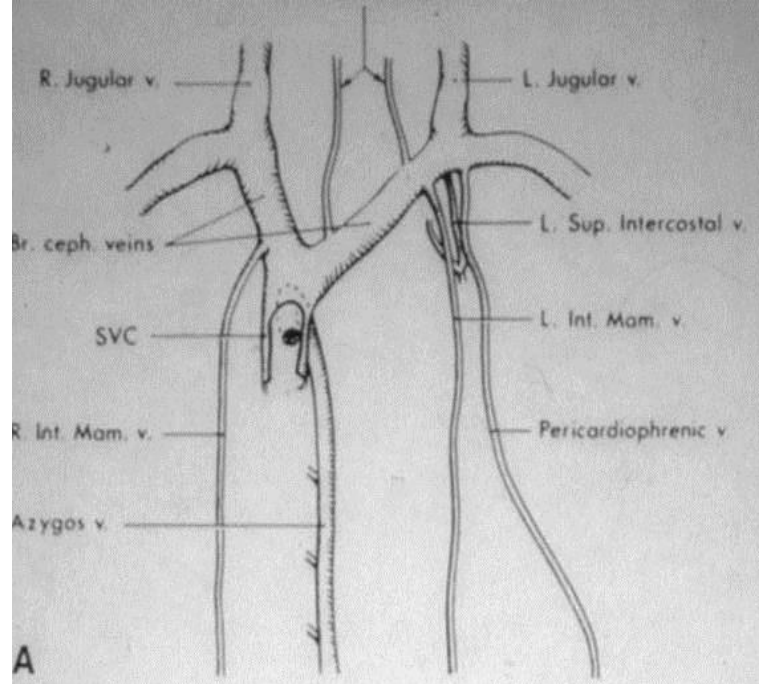
Cathéters centraux



Cathéters centraux

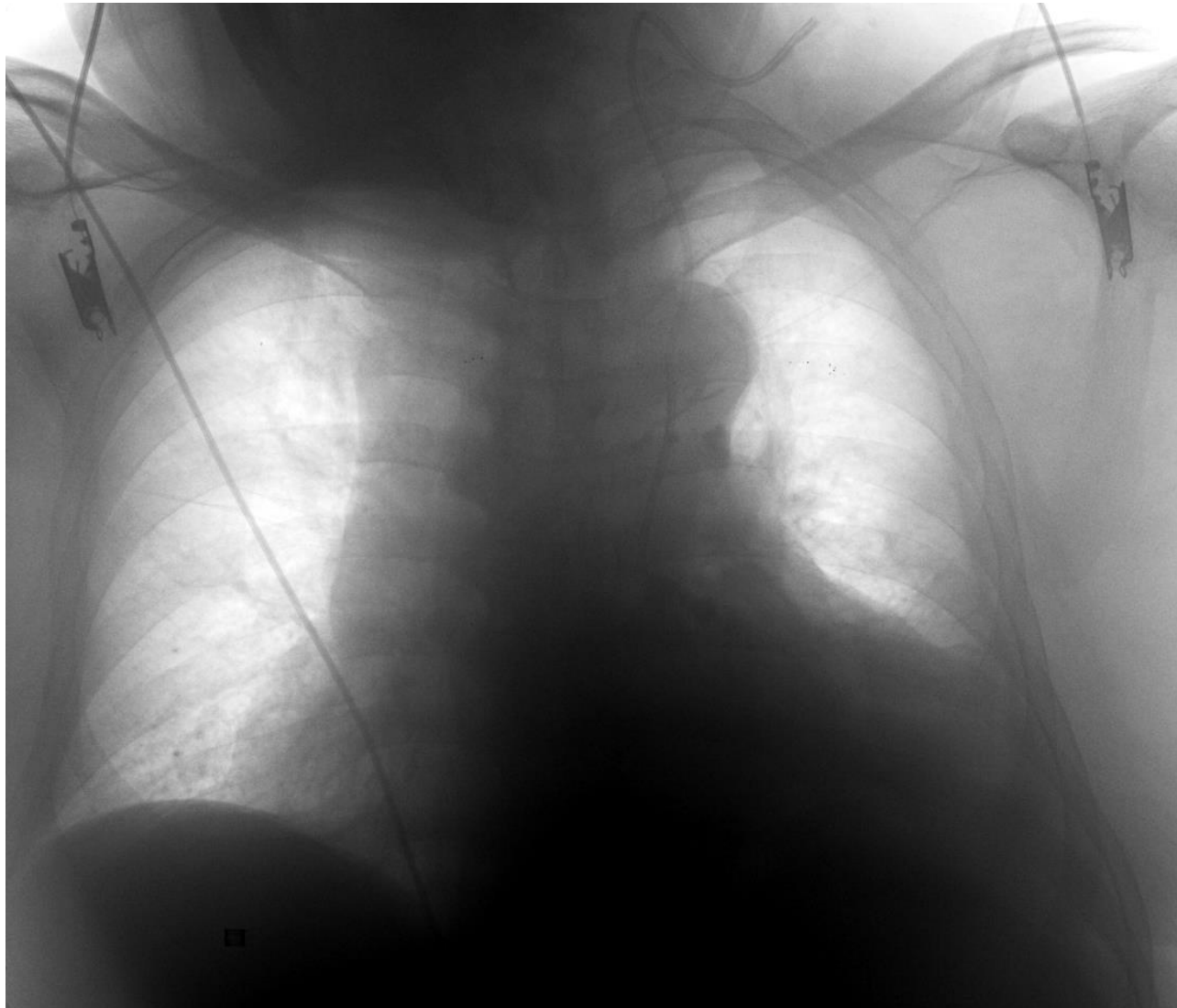

Un peu trop long = mieux que trop court
Mais risque (faible) d'arythmie



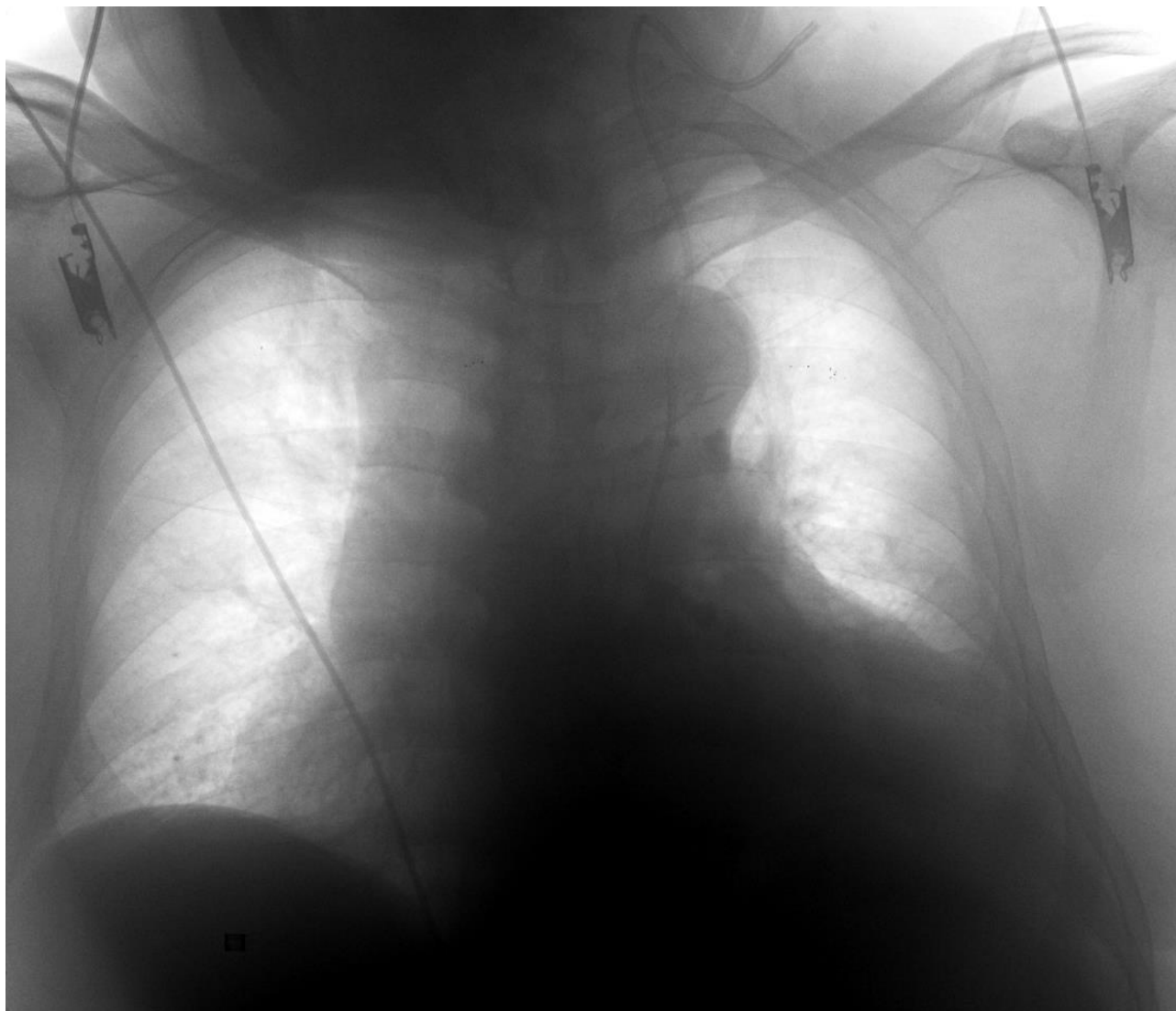Cathéters centraux

Ex 1



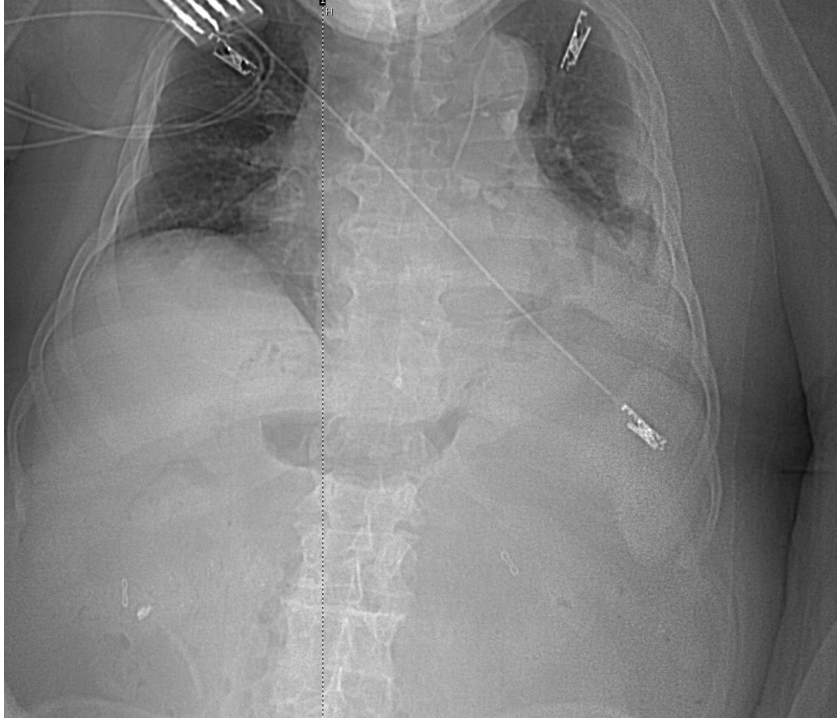Cathéters centraux

Ex 1

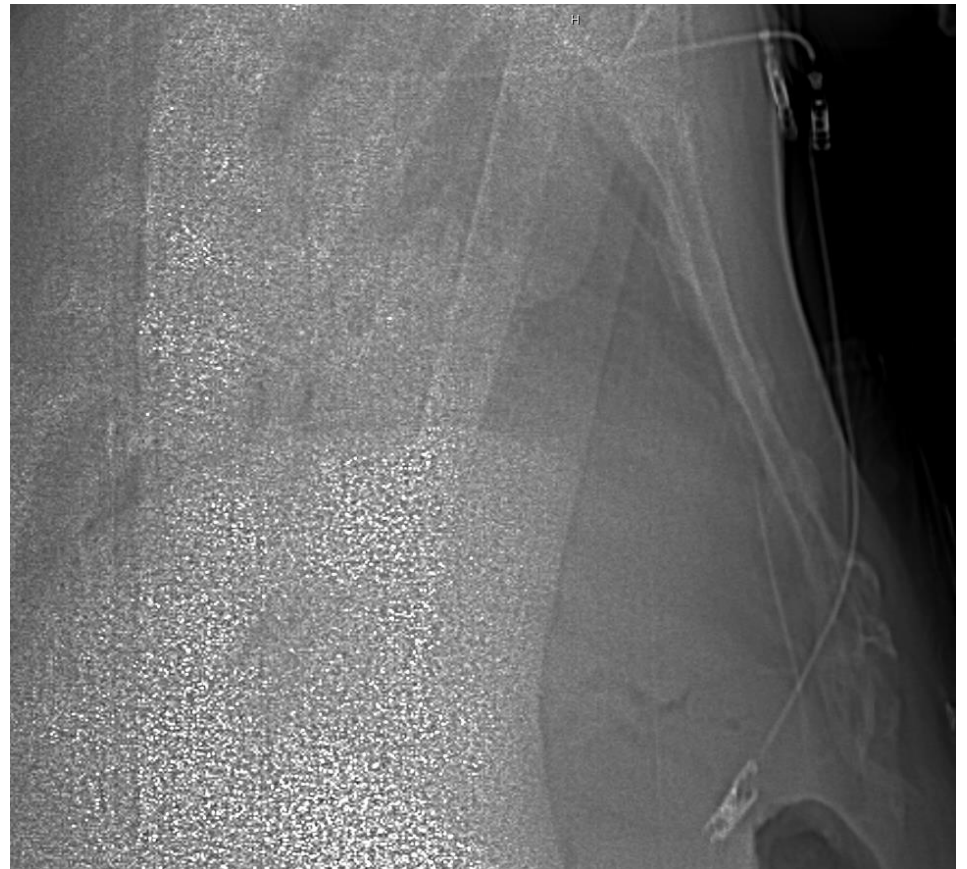

Cathéters centraux

Ex 1

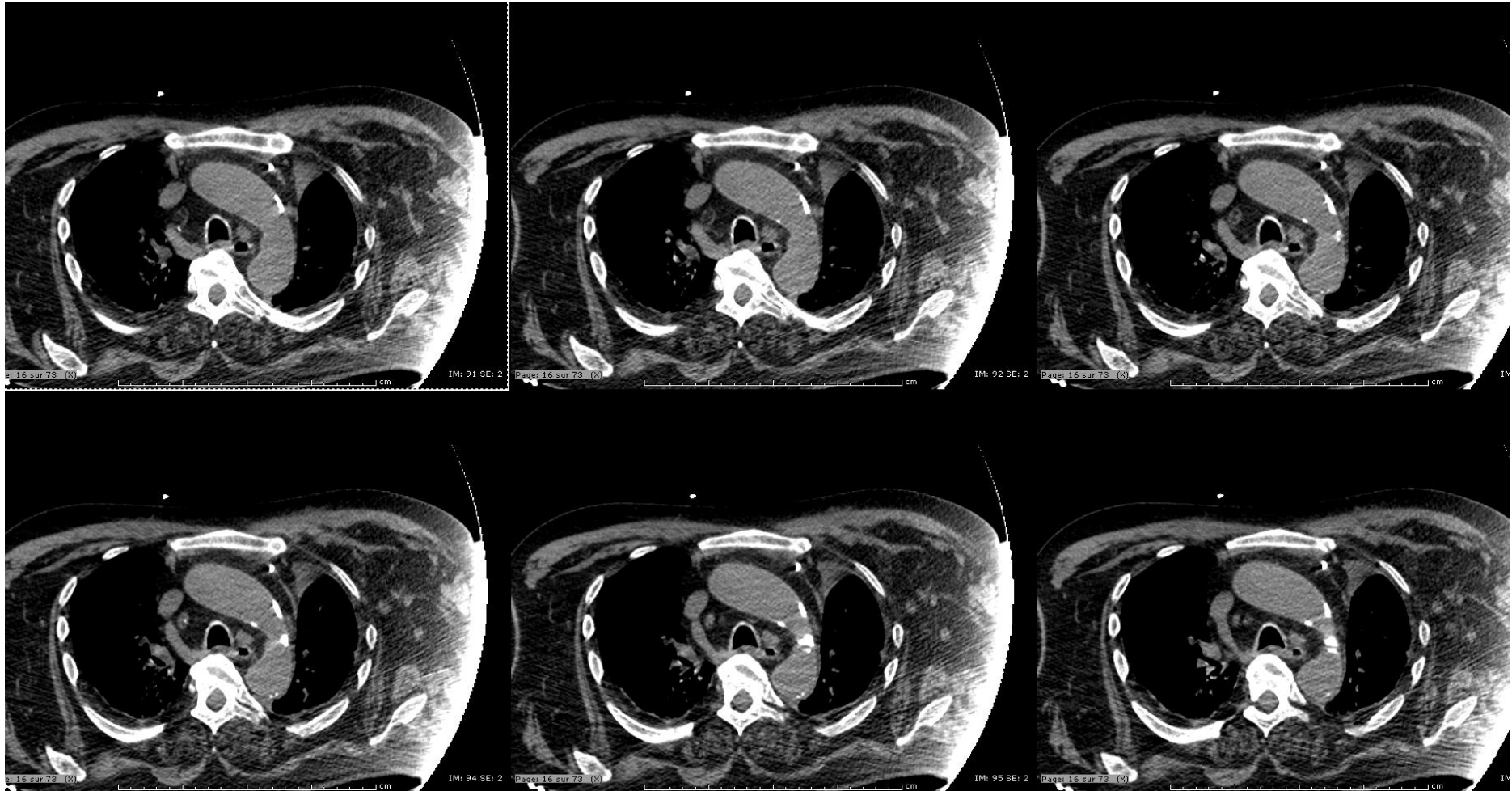


Importance du
topogramme



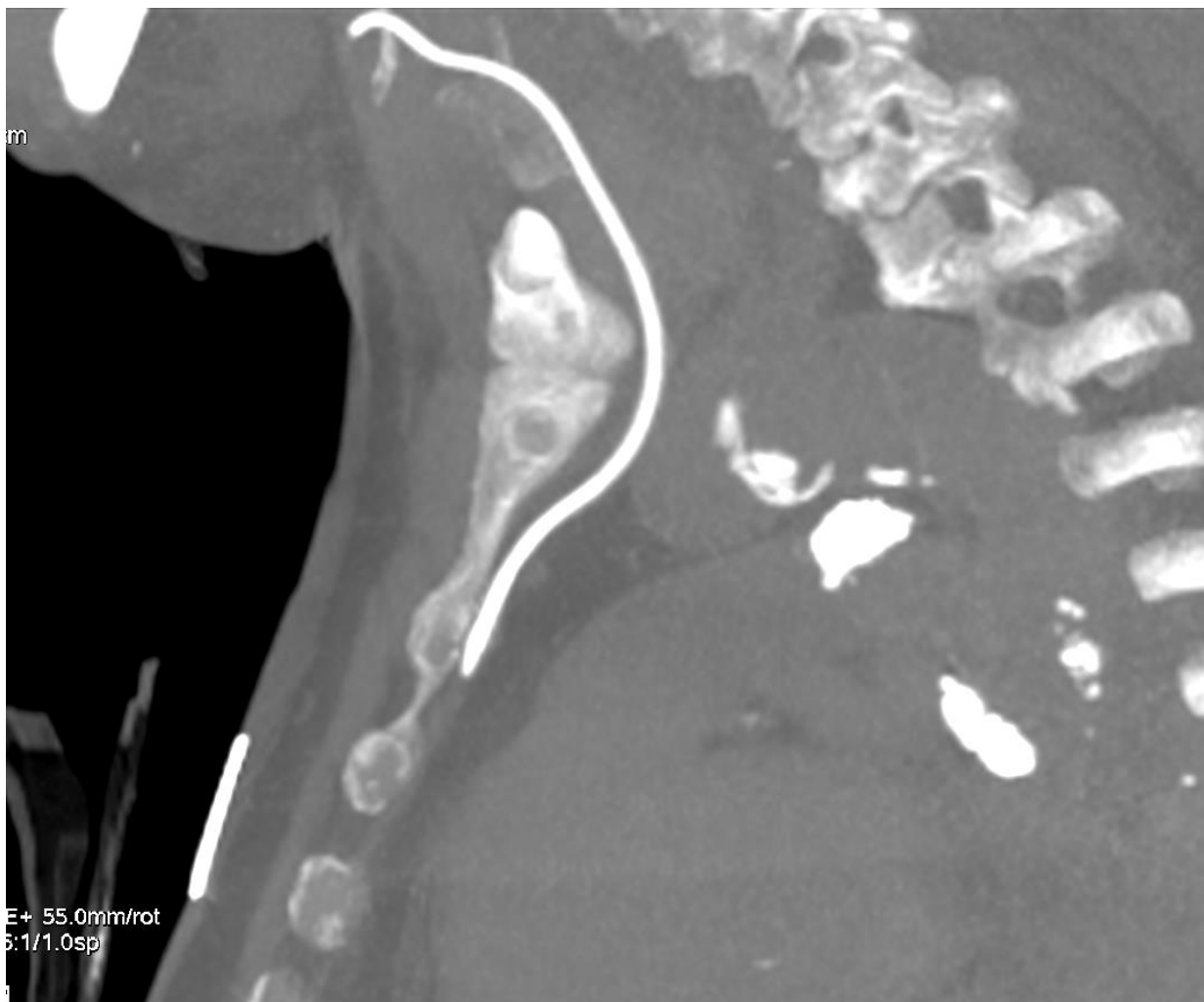
Cathéters centraux

Ex 1



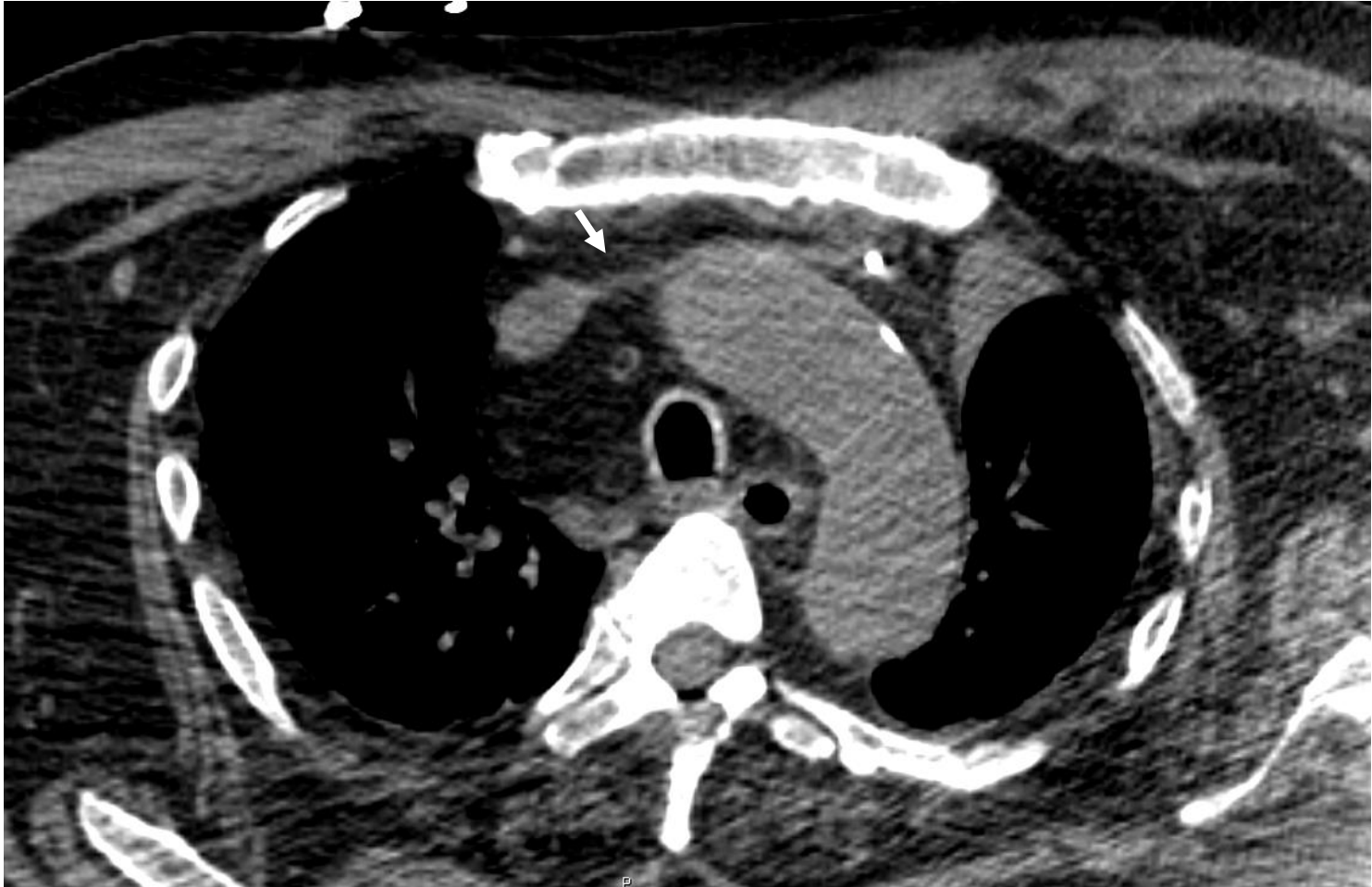Cathéters centraux

Ex 1

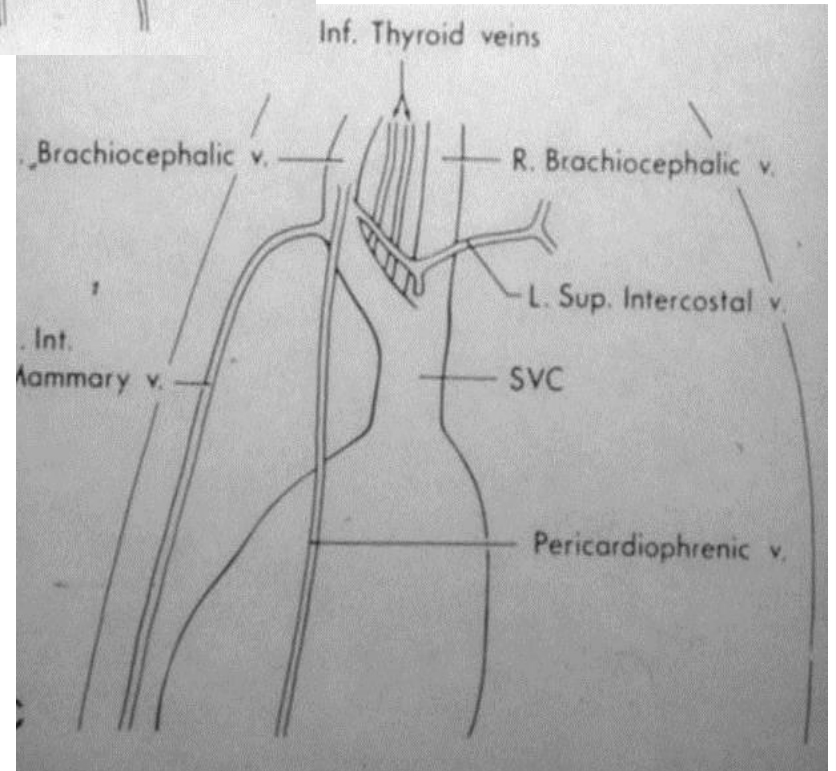
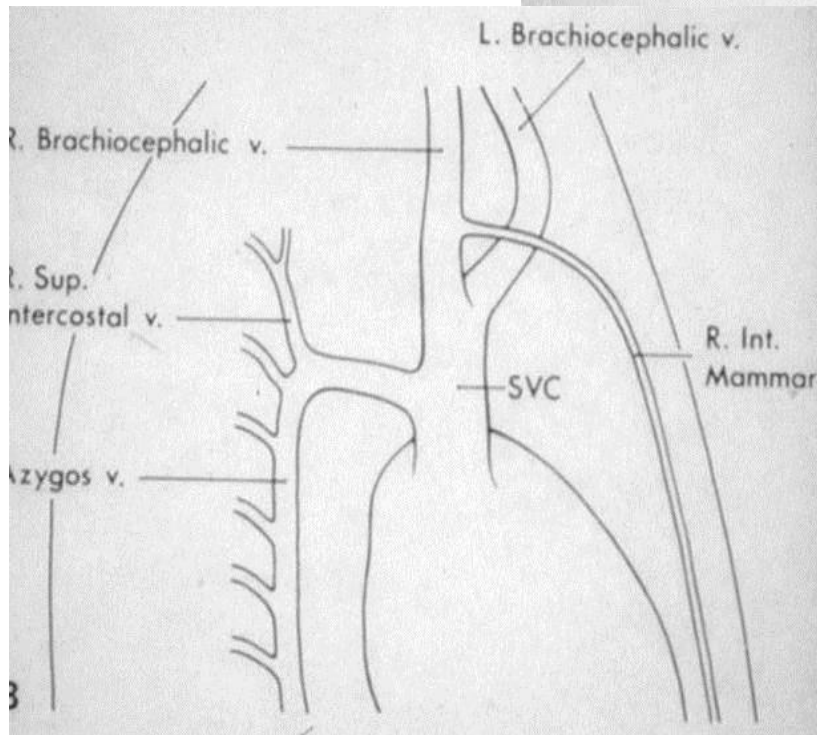
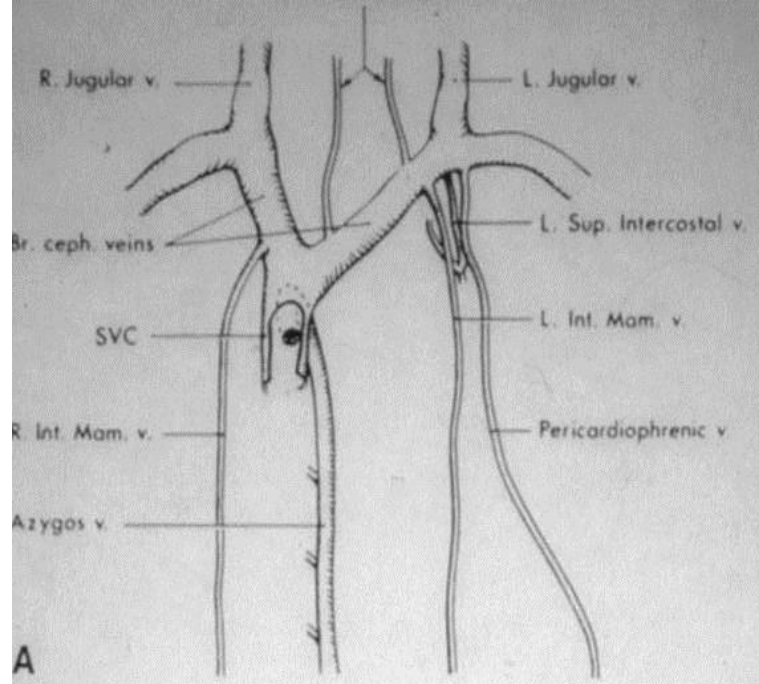


Cathéters centraux

Ex 1

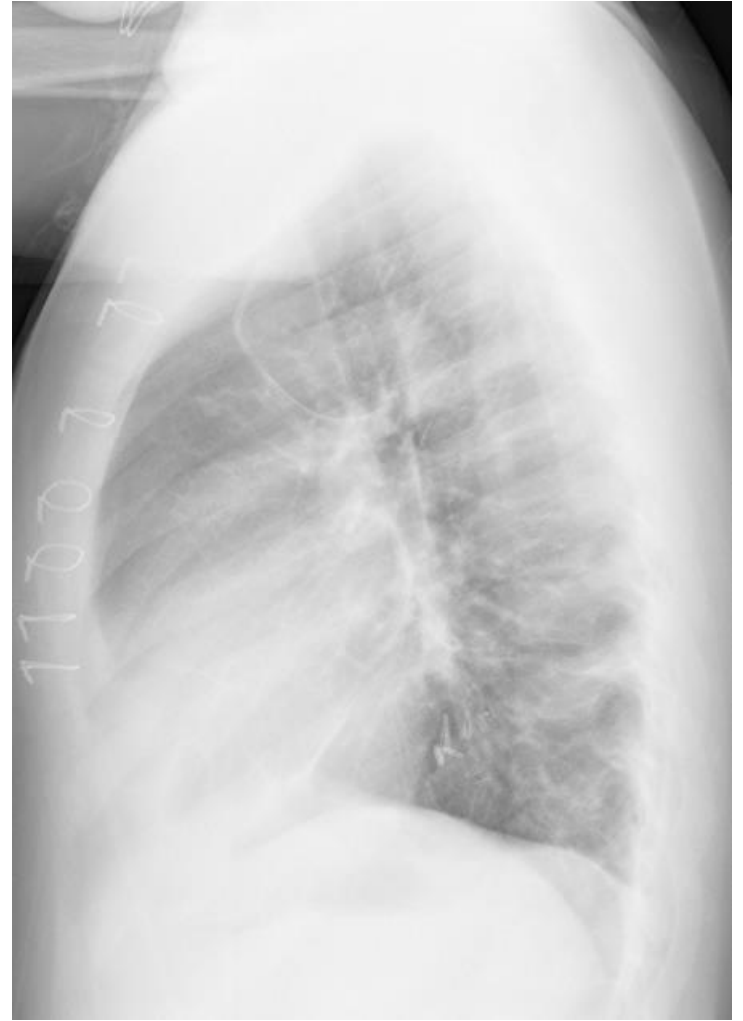
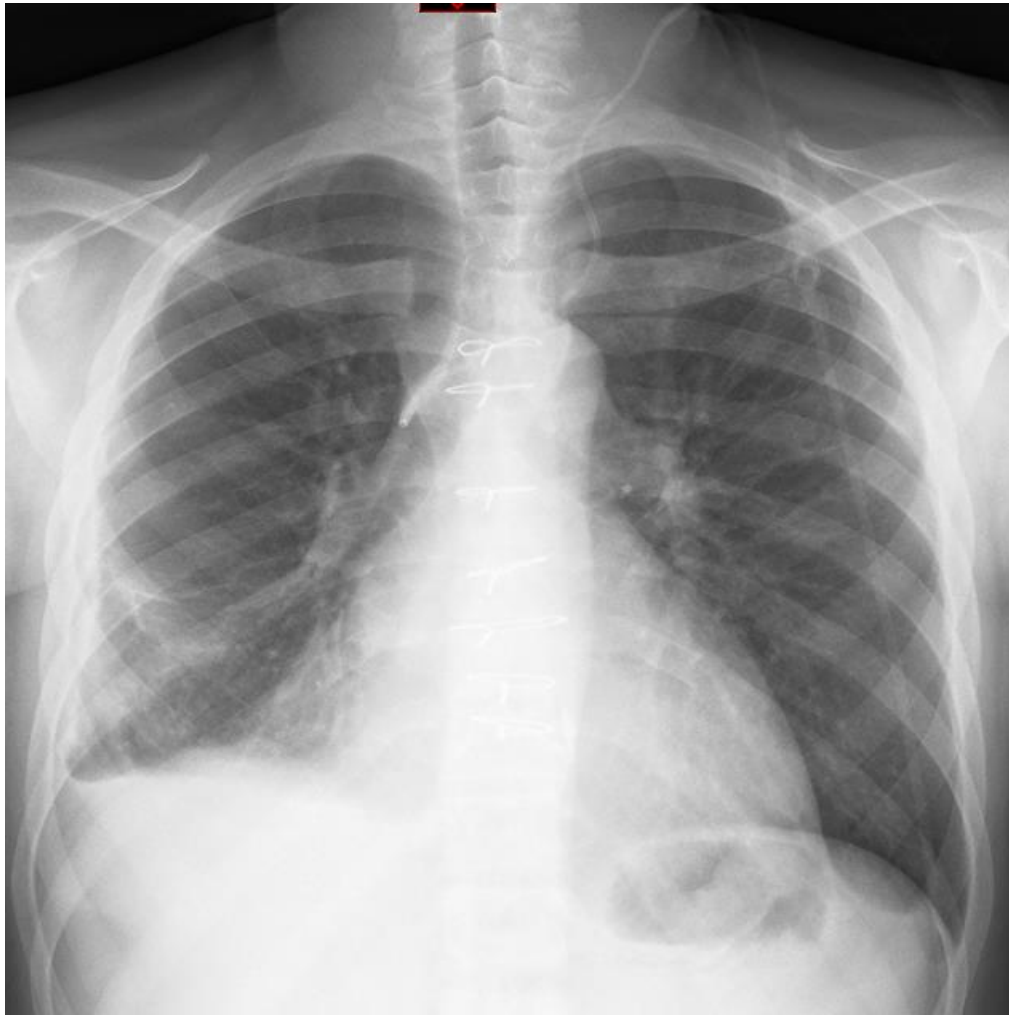
Tronc veineux innominé gauche fibreux
(ATCD de KT)



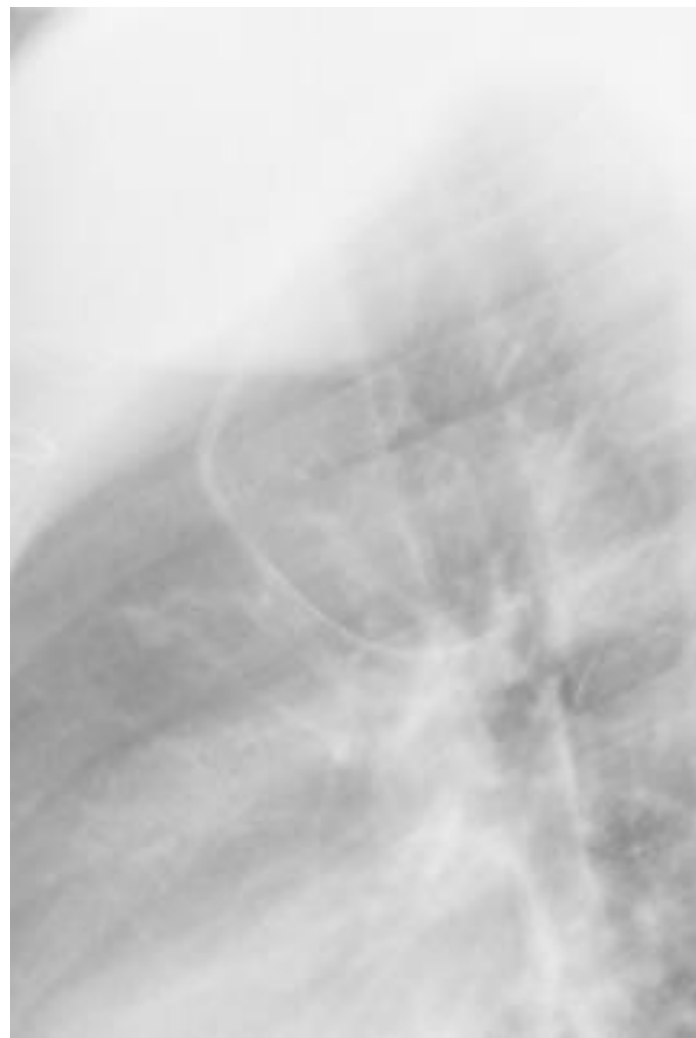
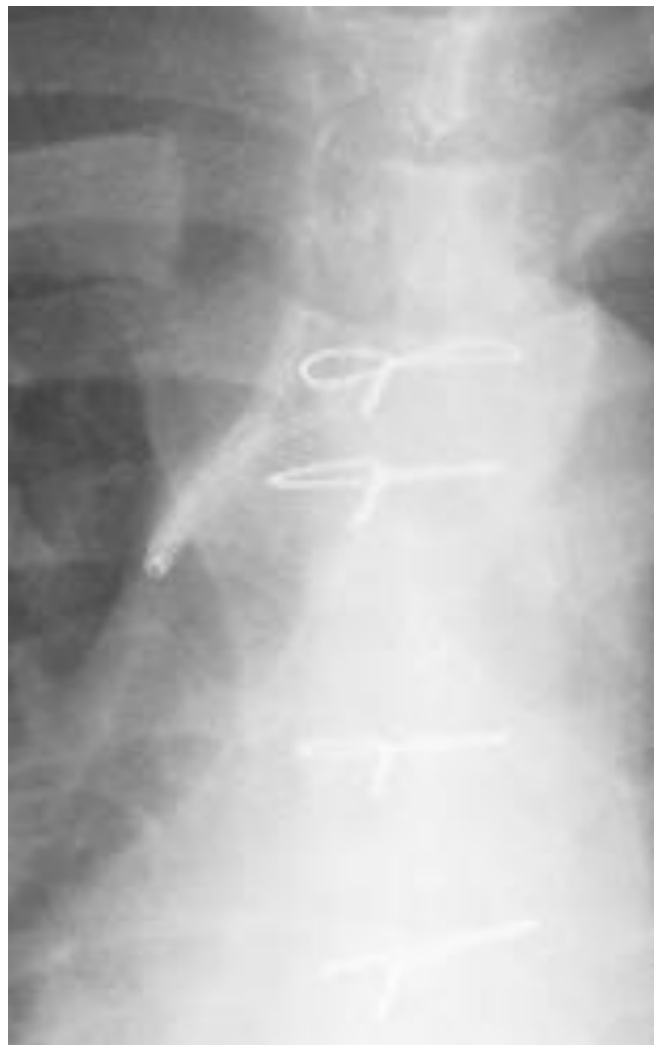Cathéters centraux

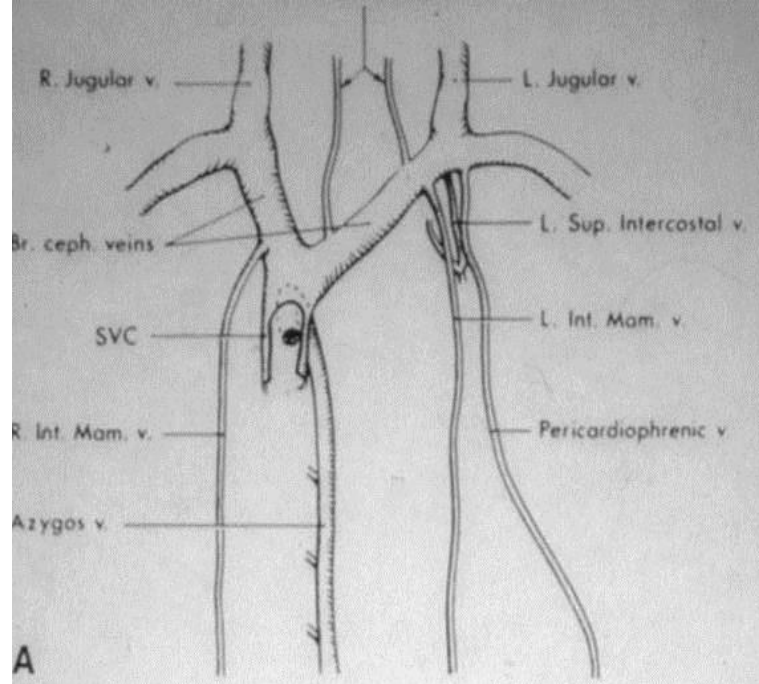
Ex 2



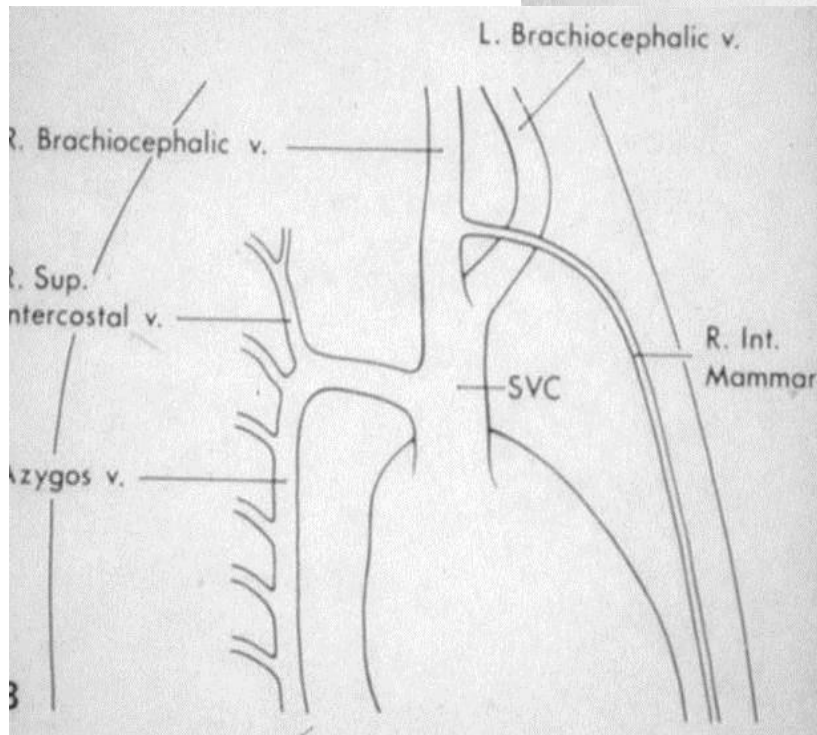
Cathéters centraux

Ex 2

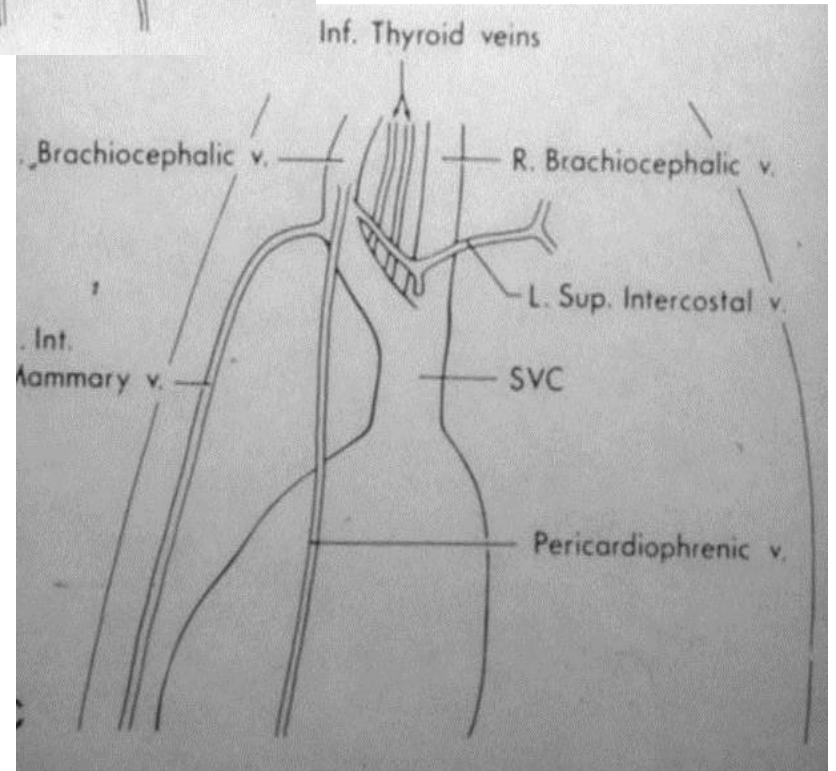




A



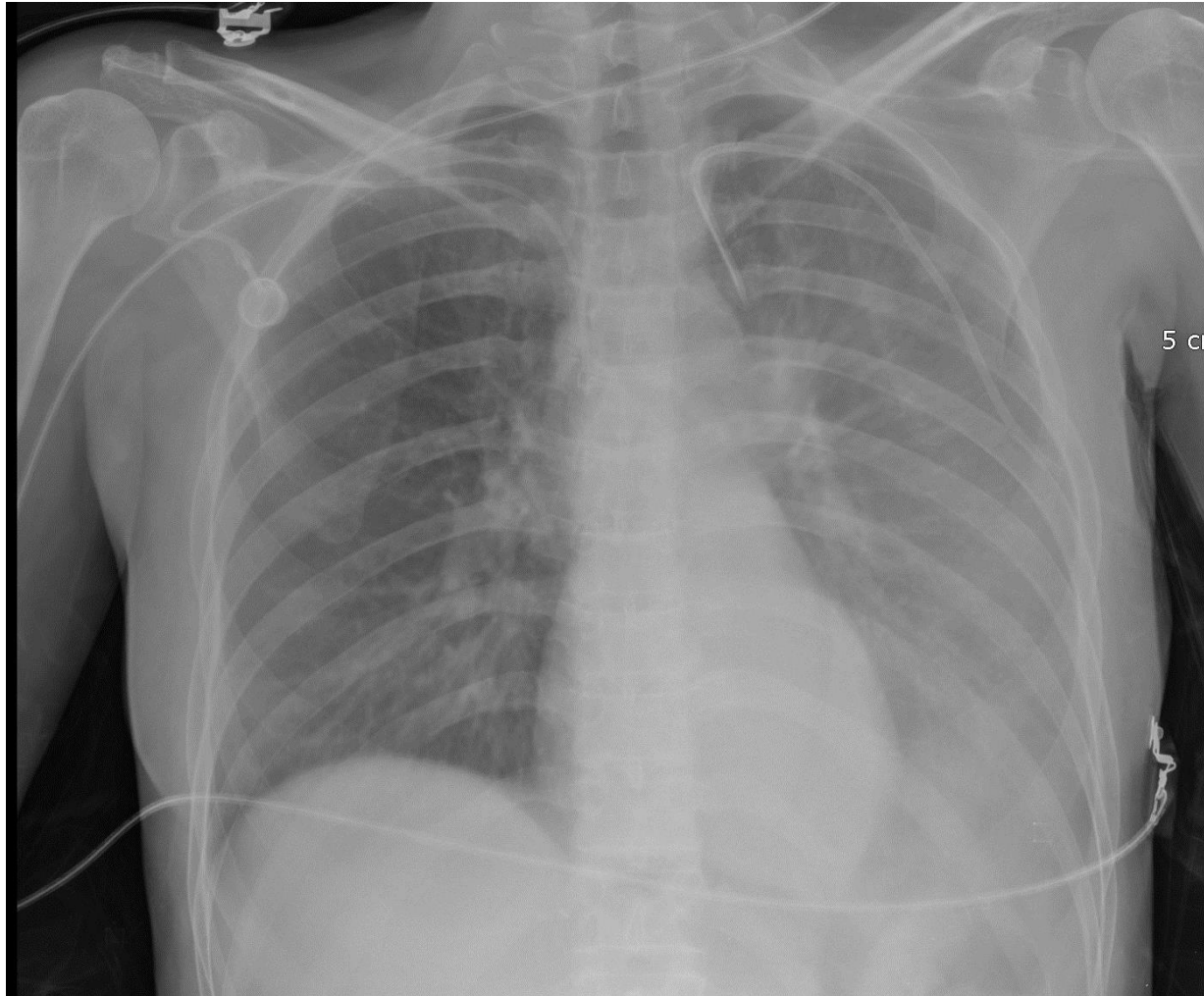
B



C

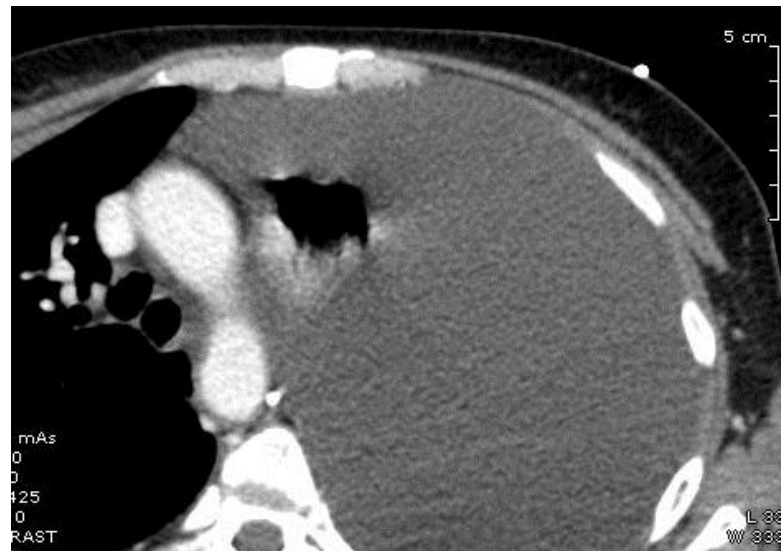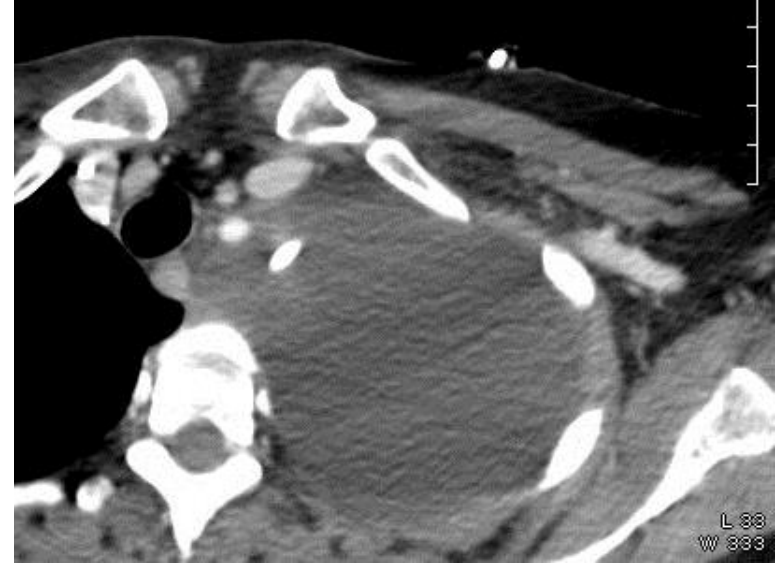
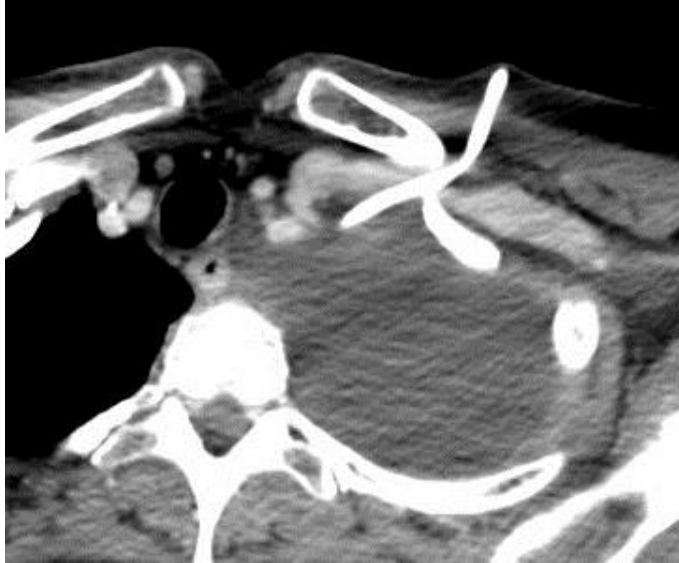Cathéters centraux

Ex 3



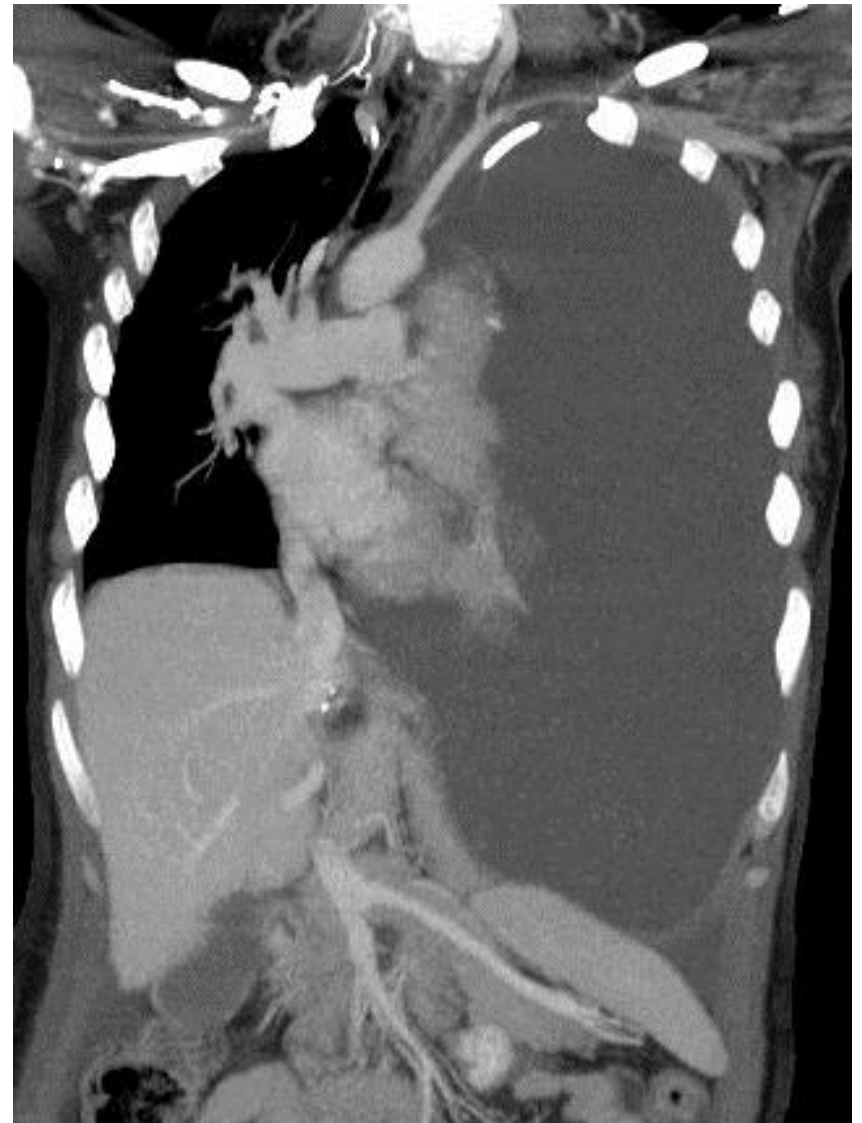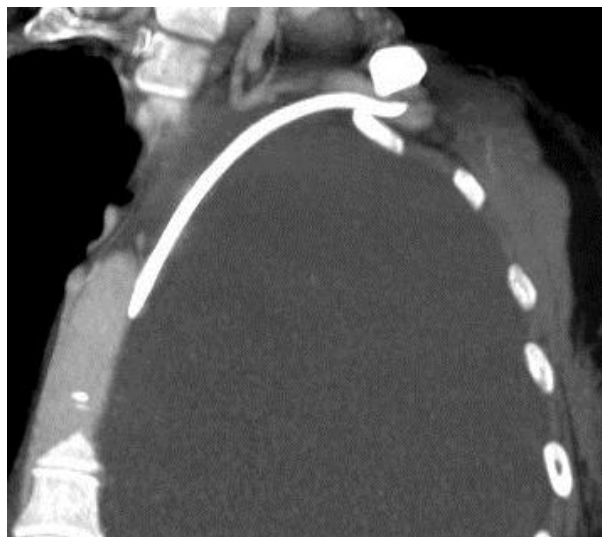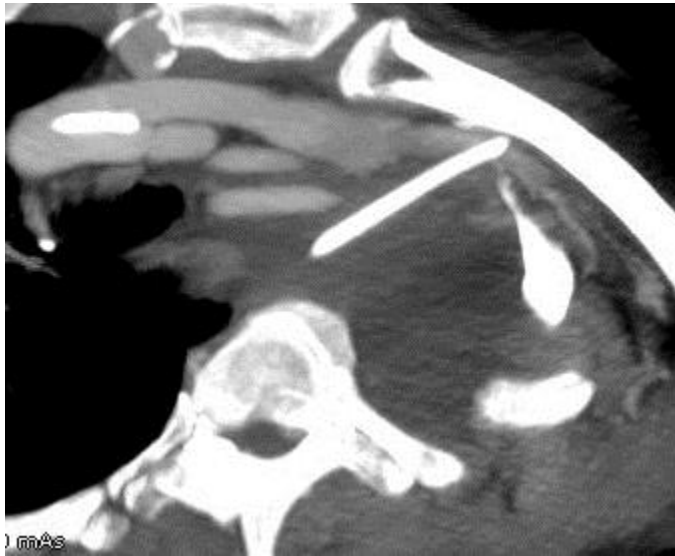
Cathéters centraux

Ex 3



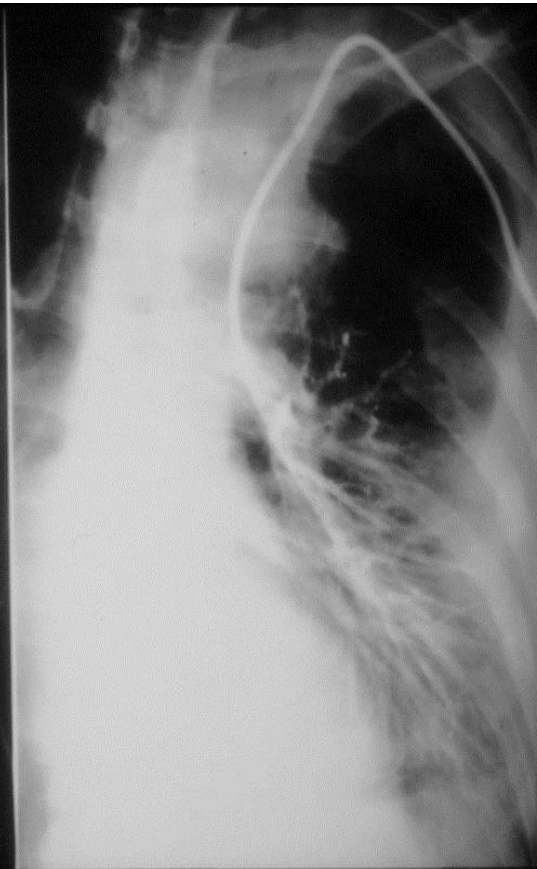
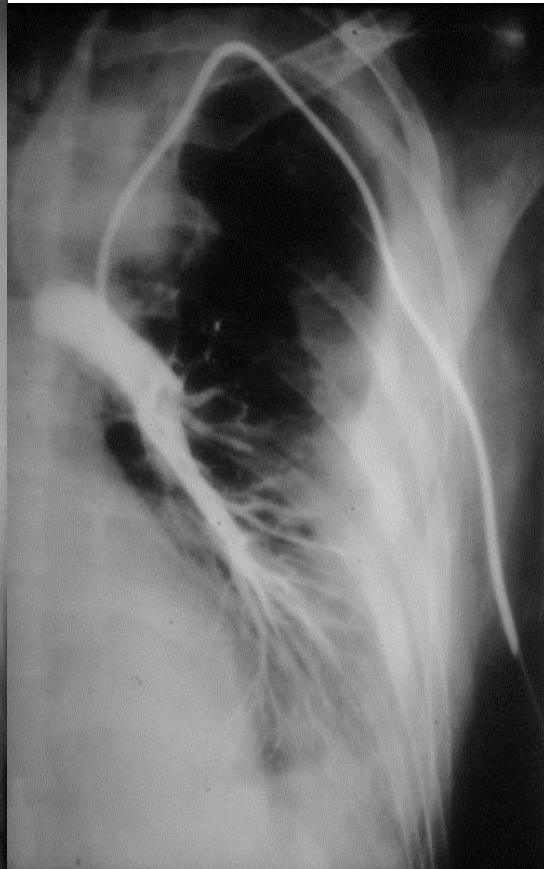
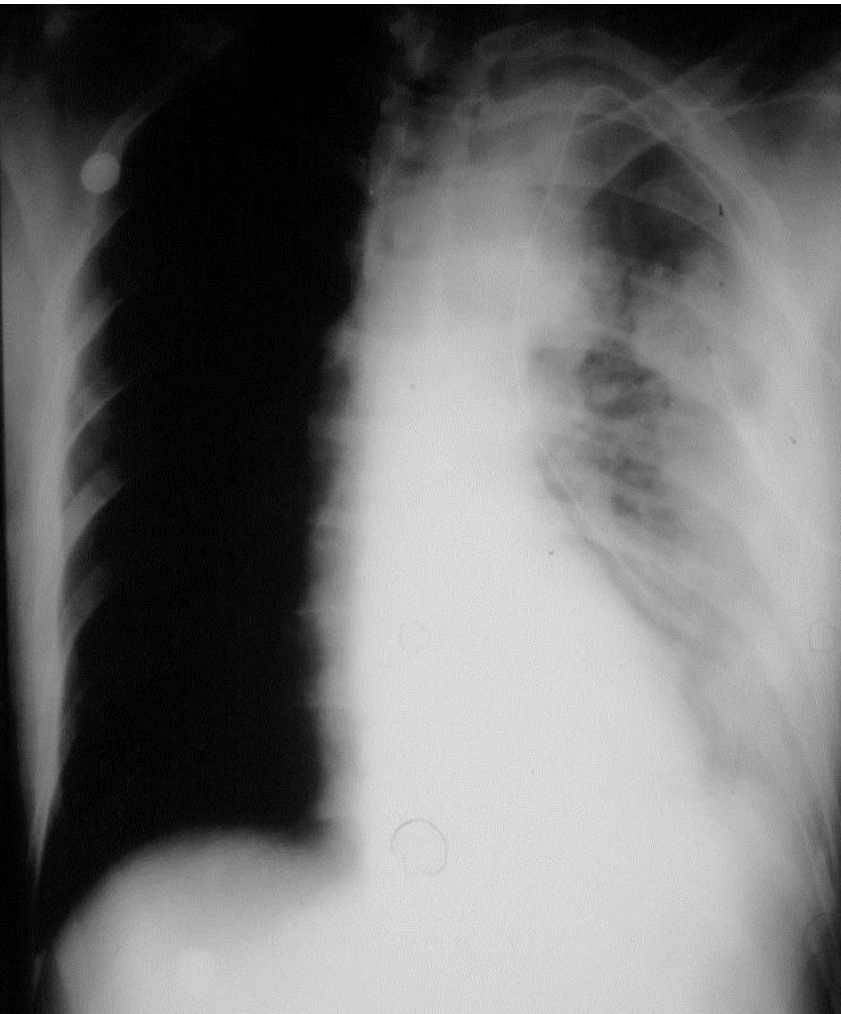
Cathéters centraux

Ex 3



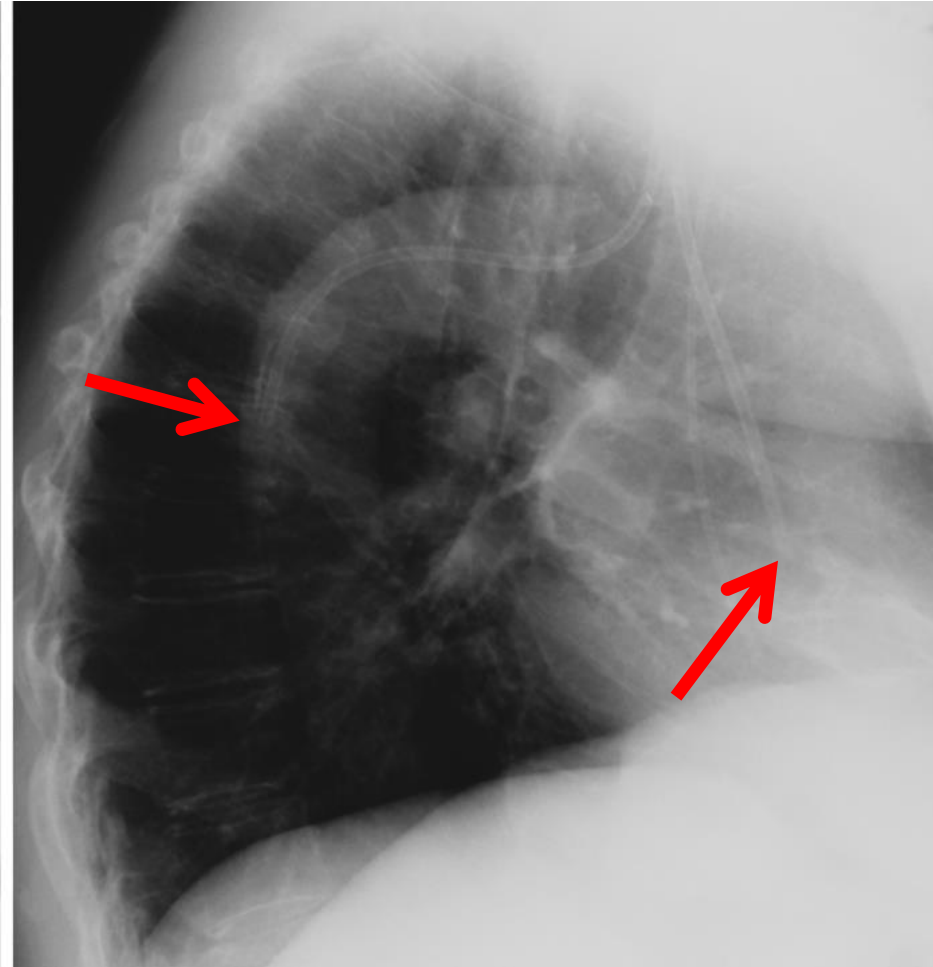
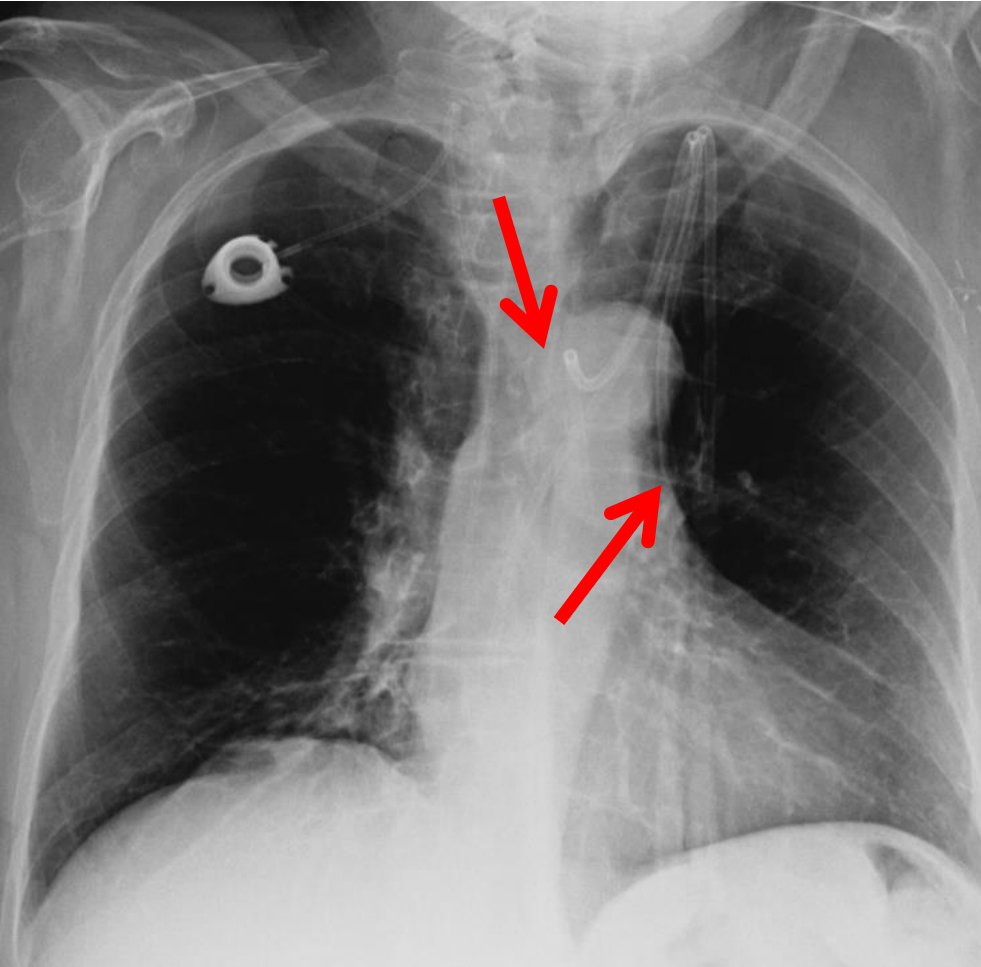
Cathéters centraux

Ex 4



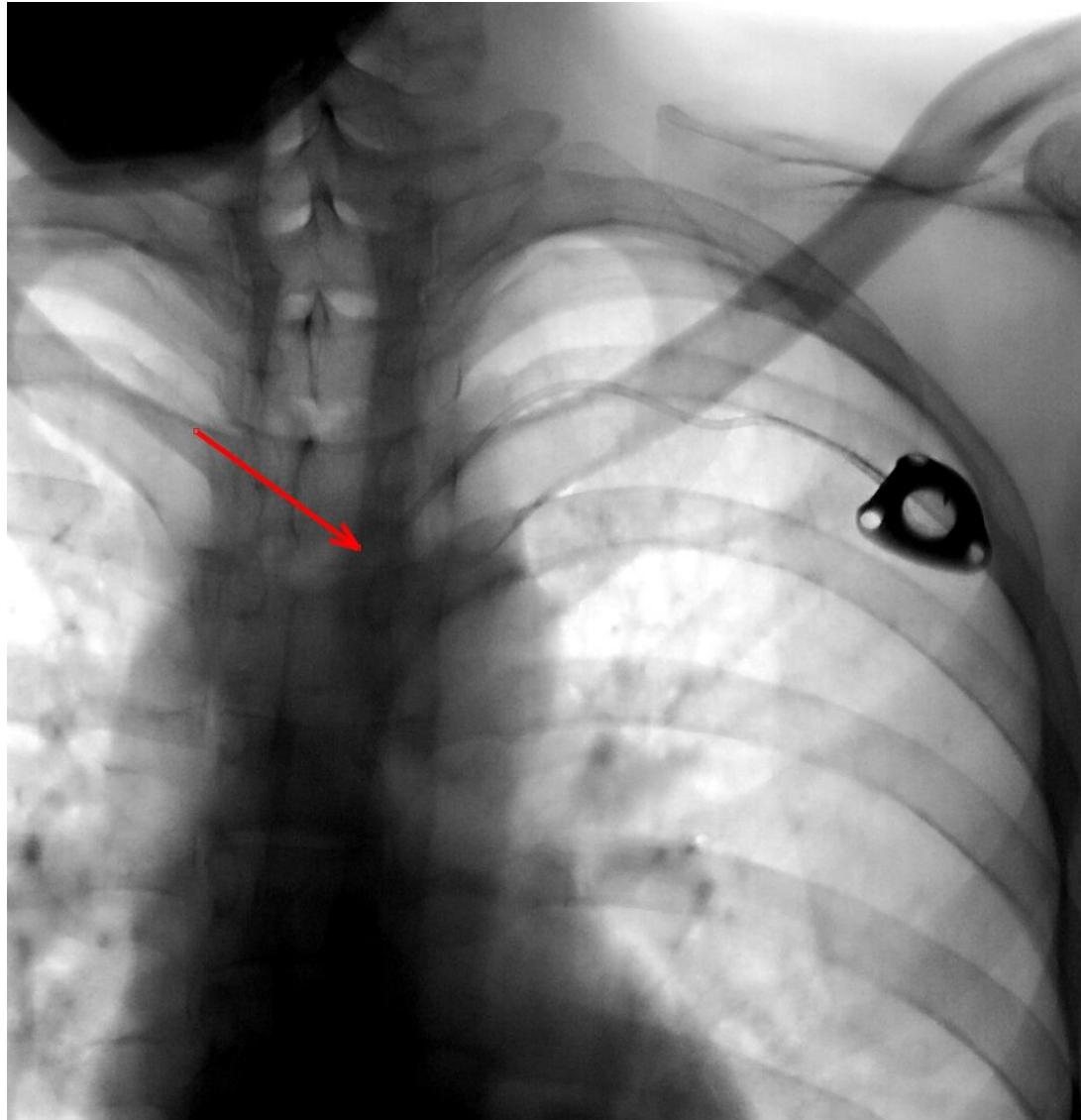
Cathéters centraux

Ex 5



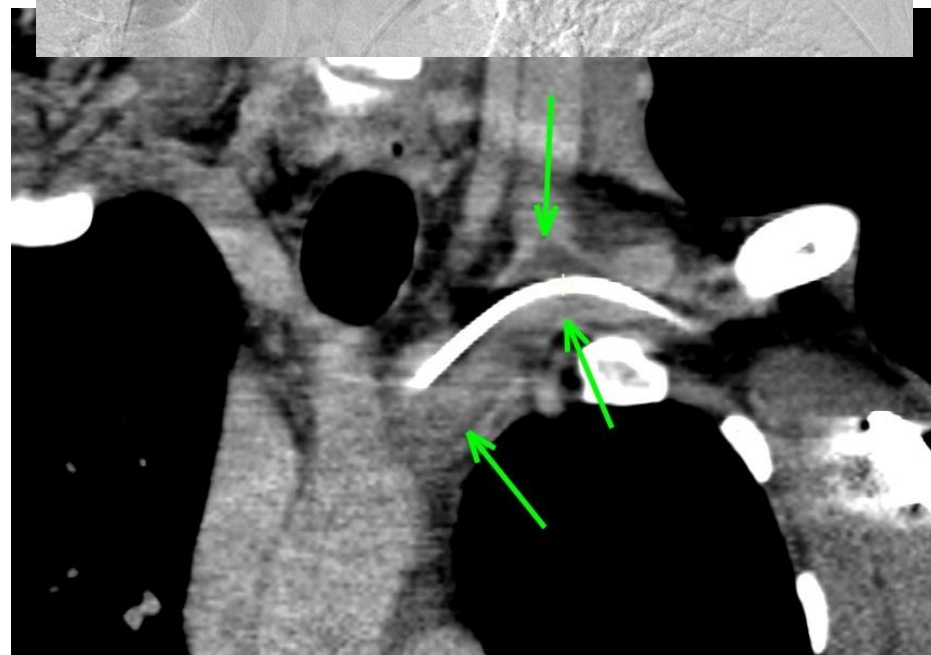
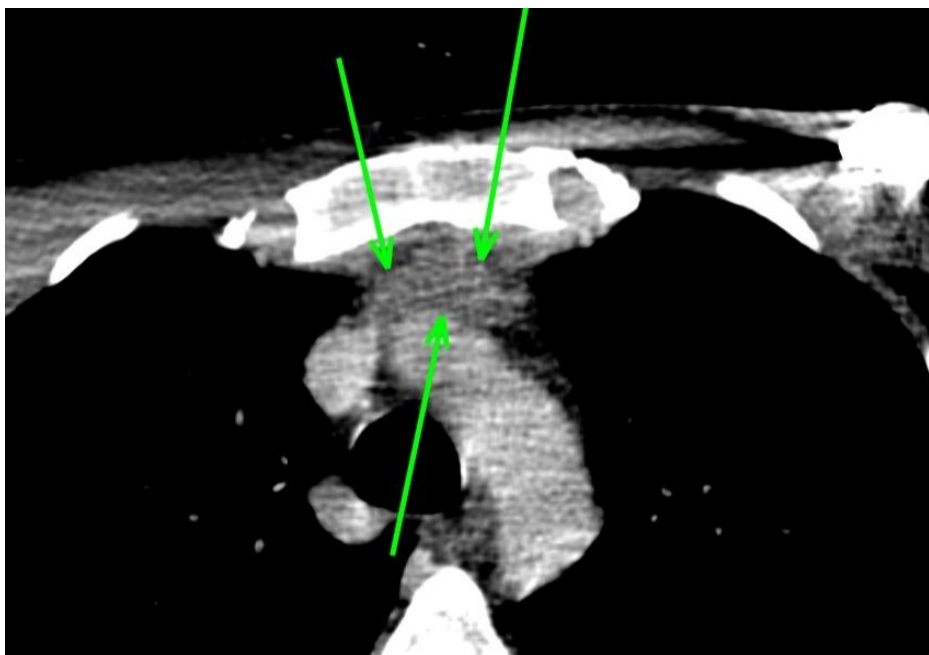
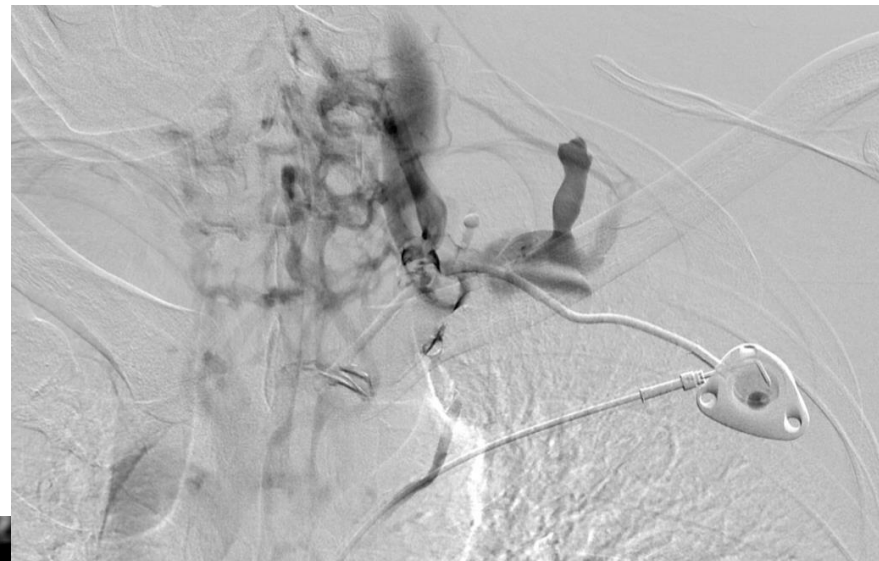Cathéters centraux

Ex 6



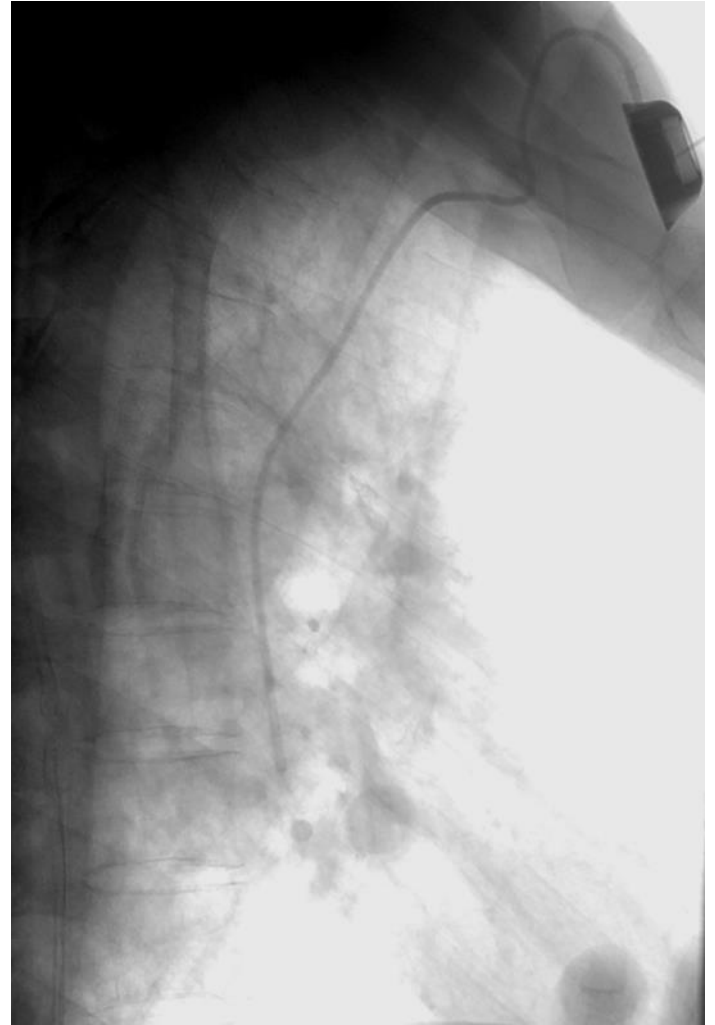
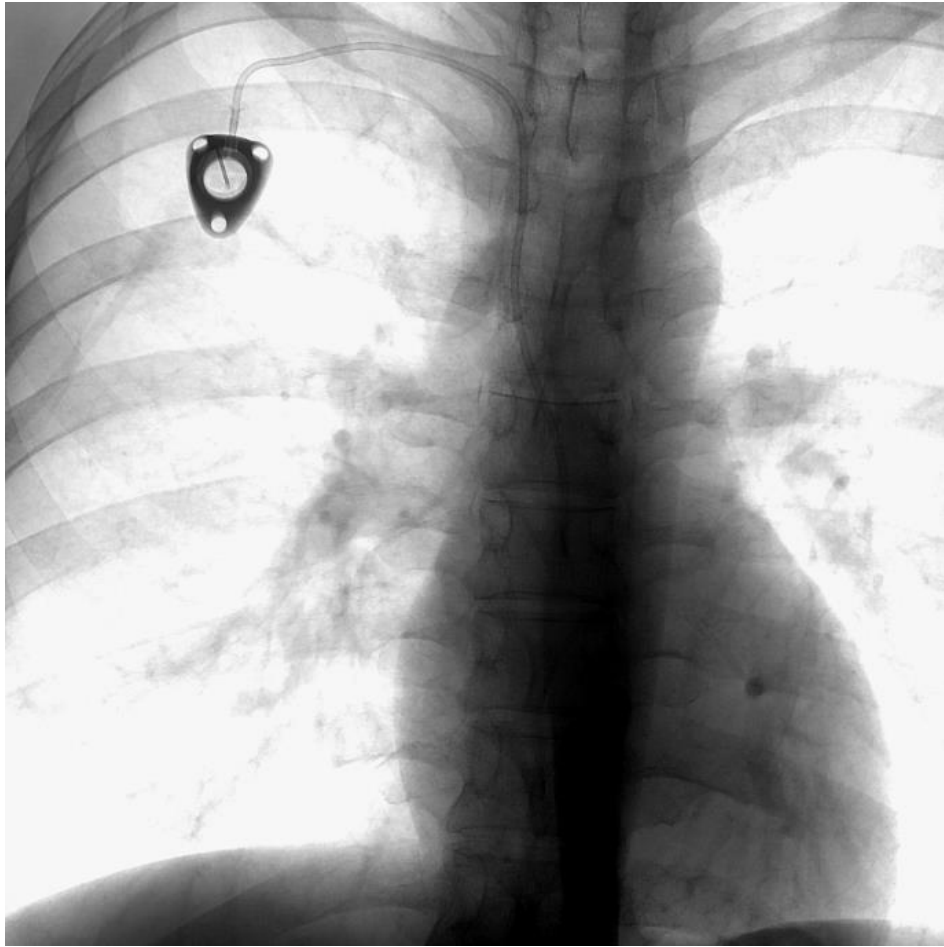
Cathéters centraux

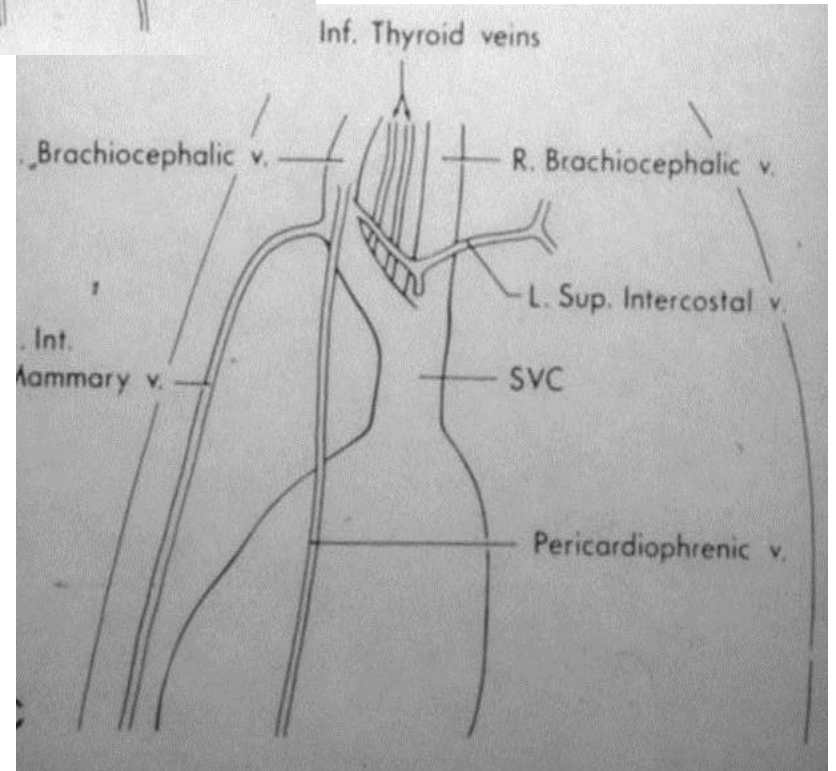
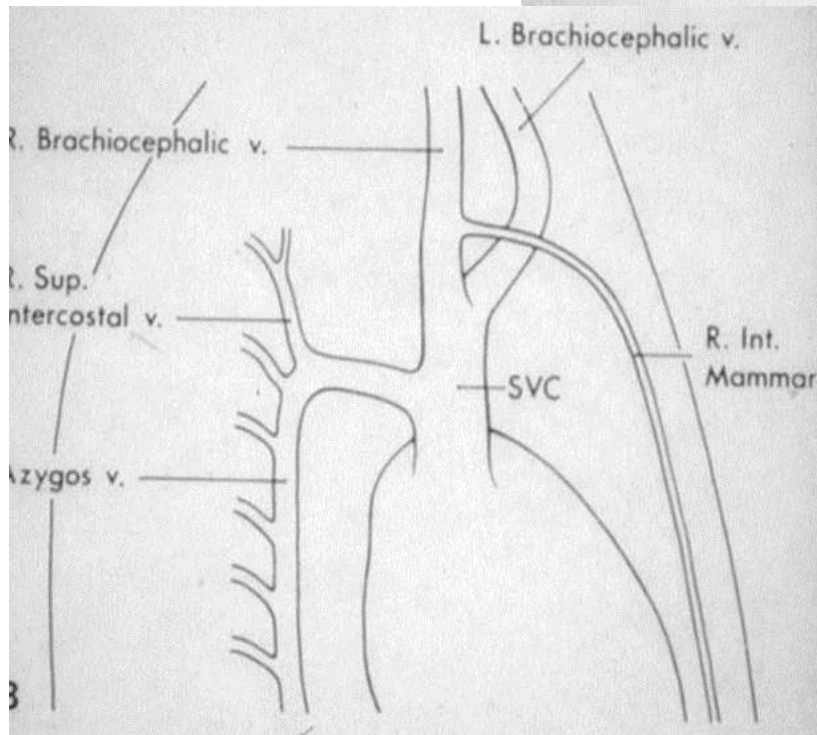
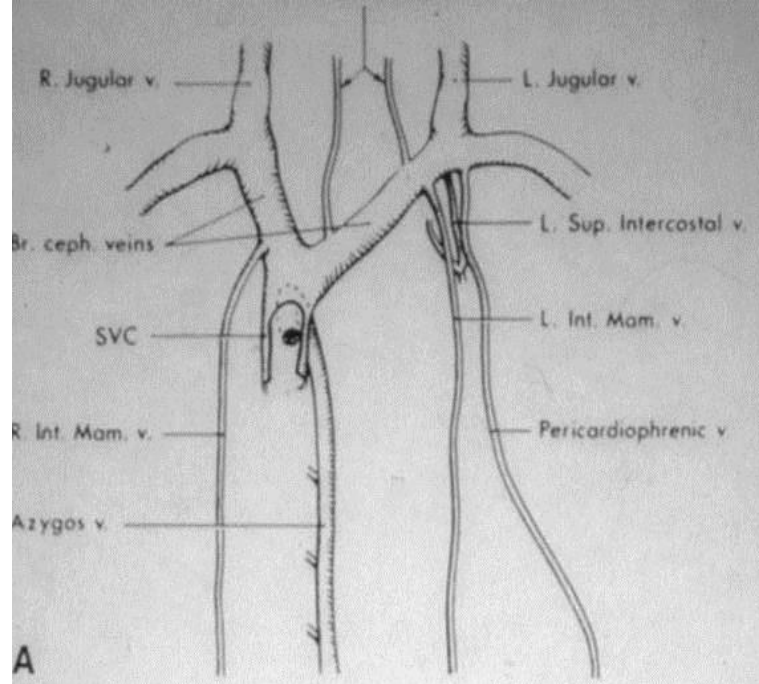
Ex 6



Cathéters centraux

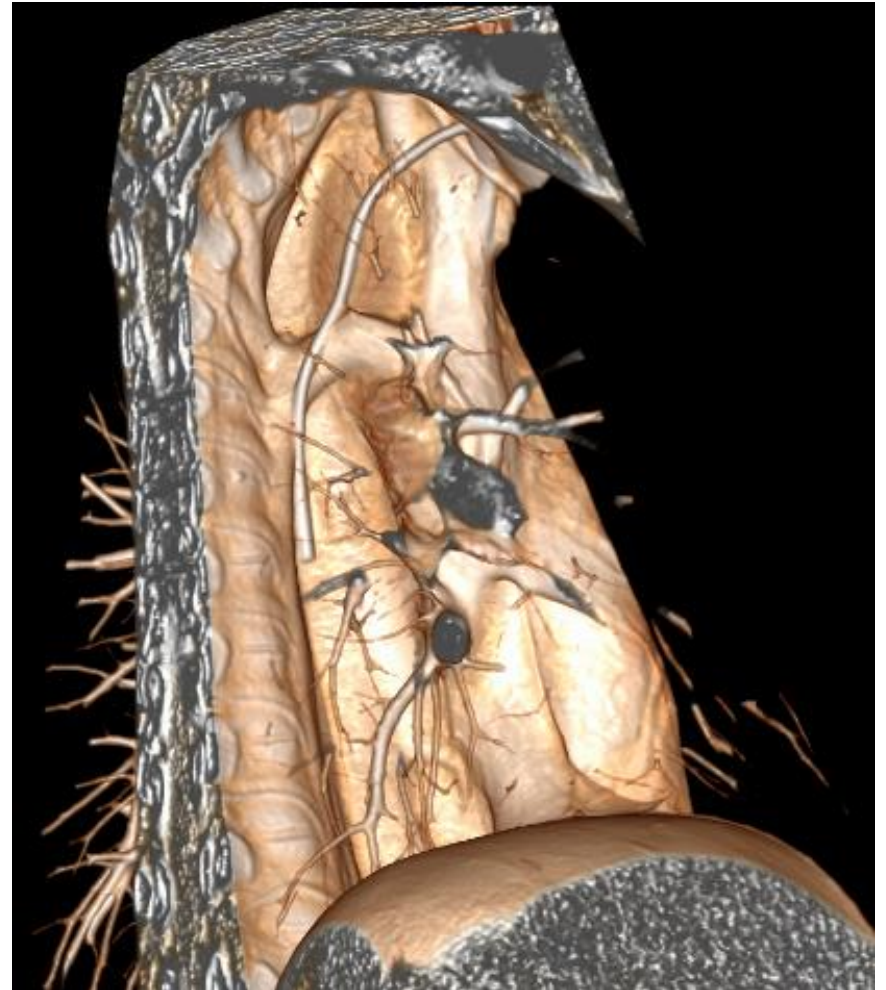
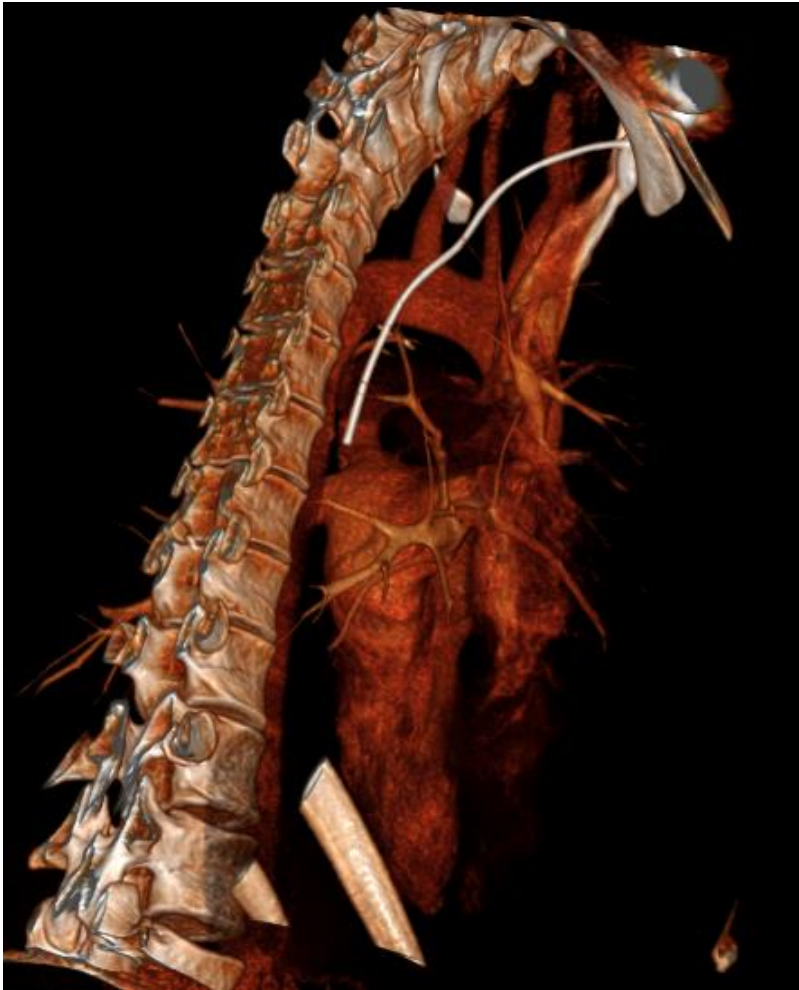Ex 6





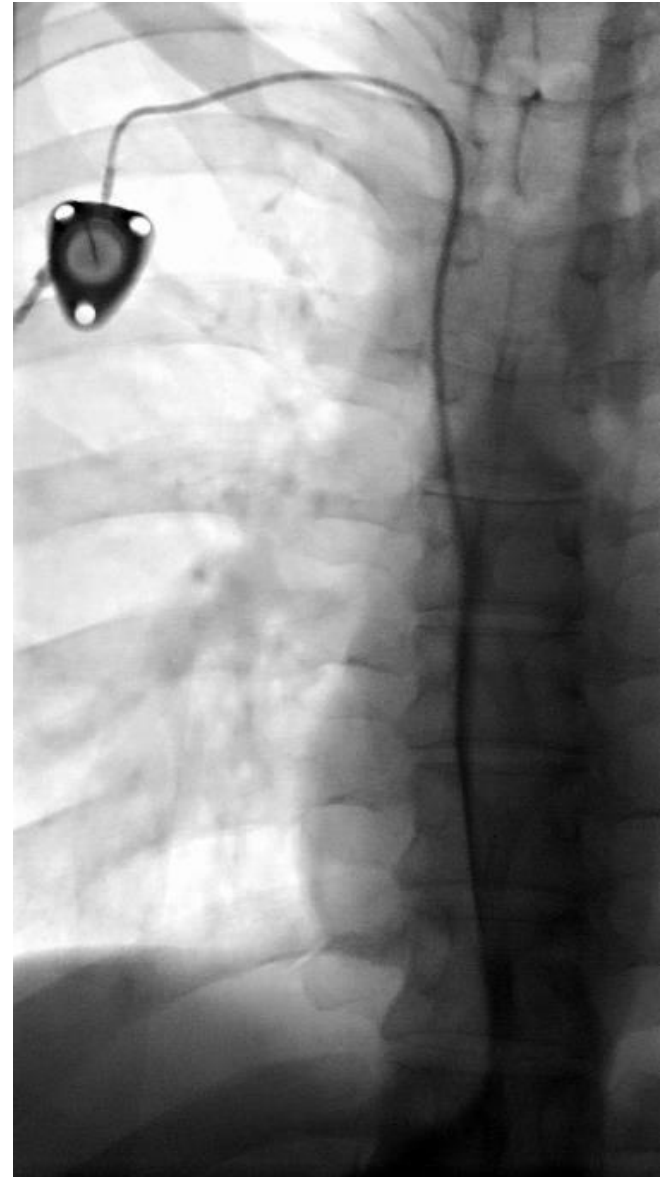
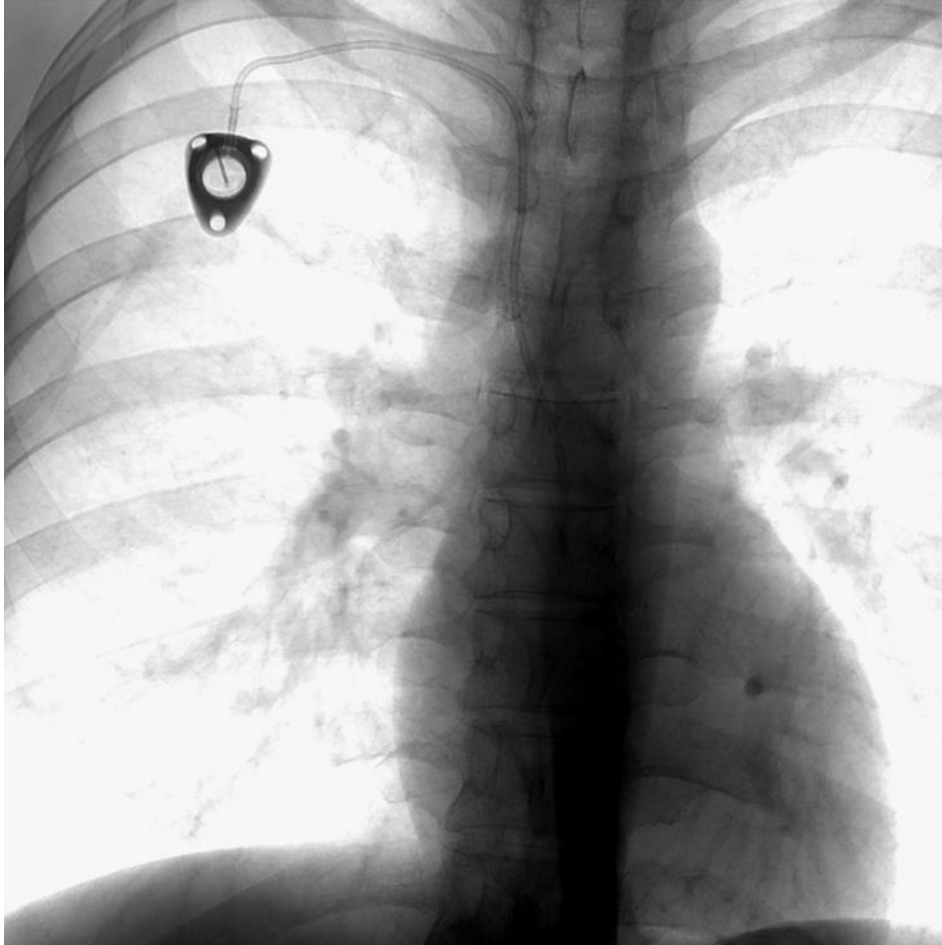Cathéters centraux

Ex 6



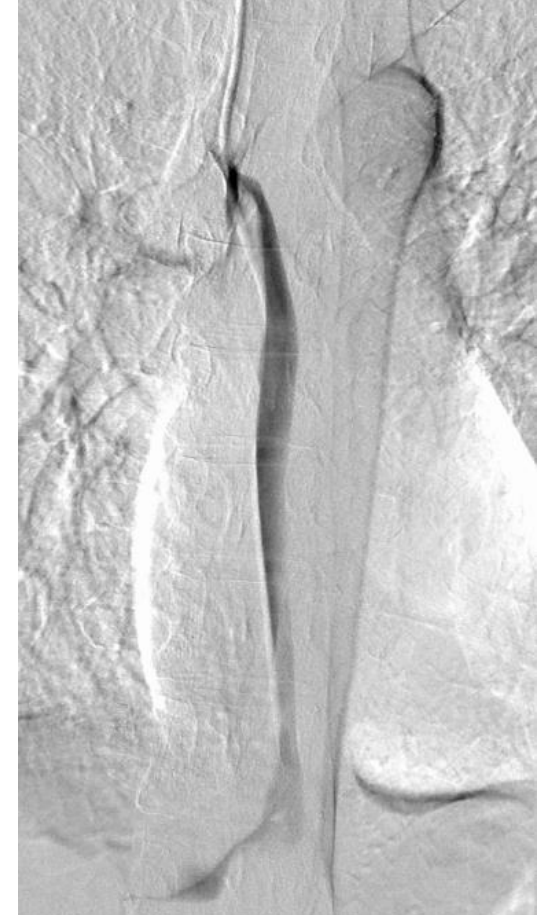
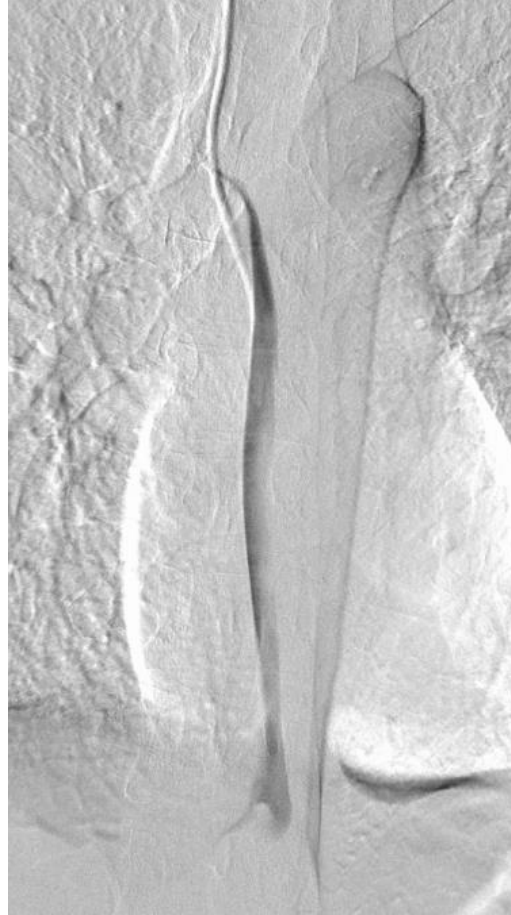
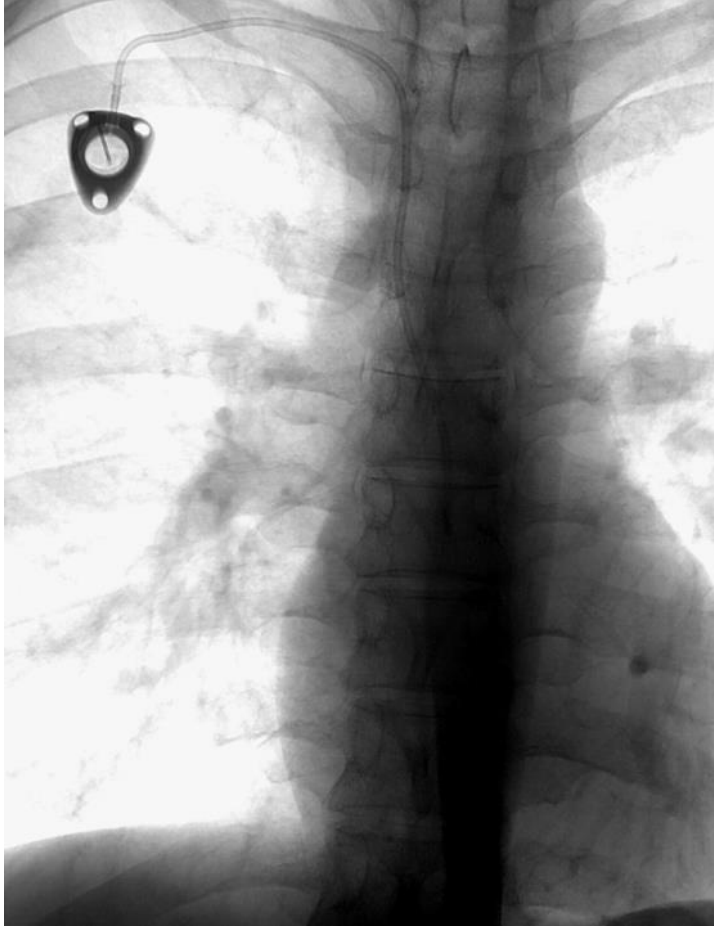
Cathéters centraux

Ex 6



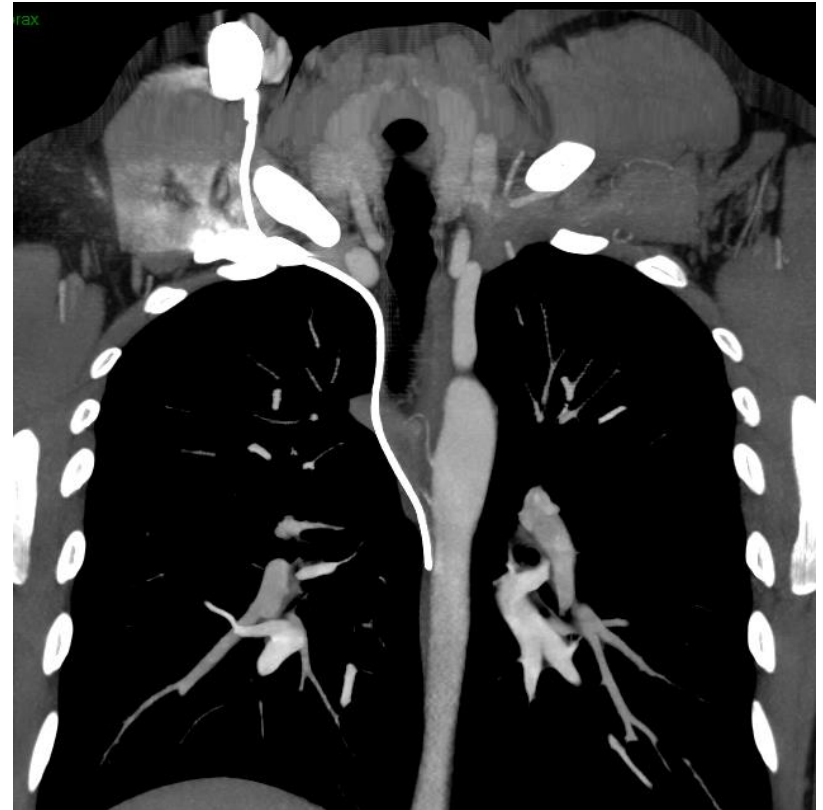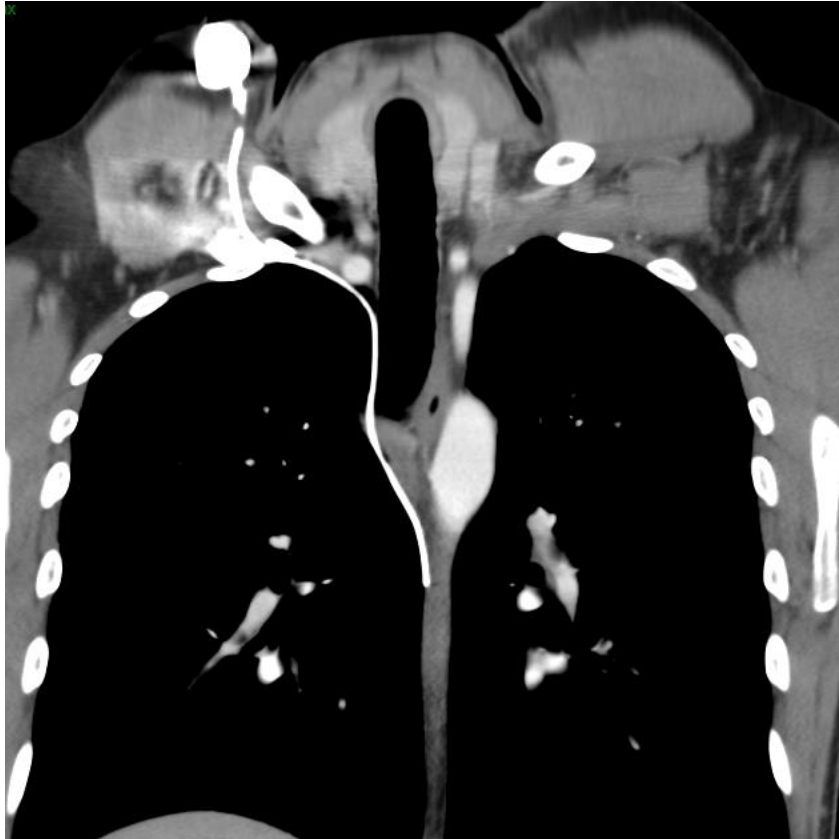
Cathéters centraux

Ex 6

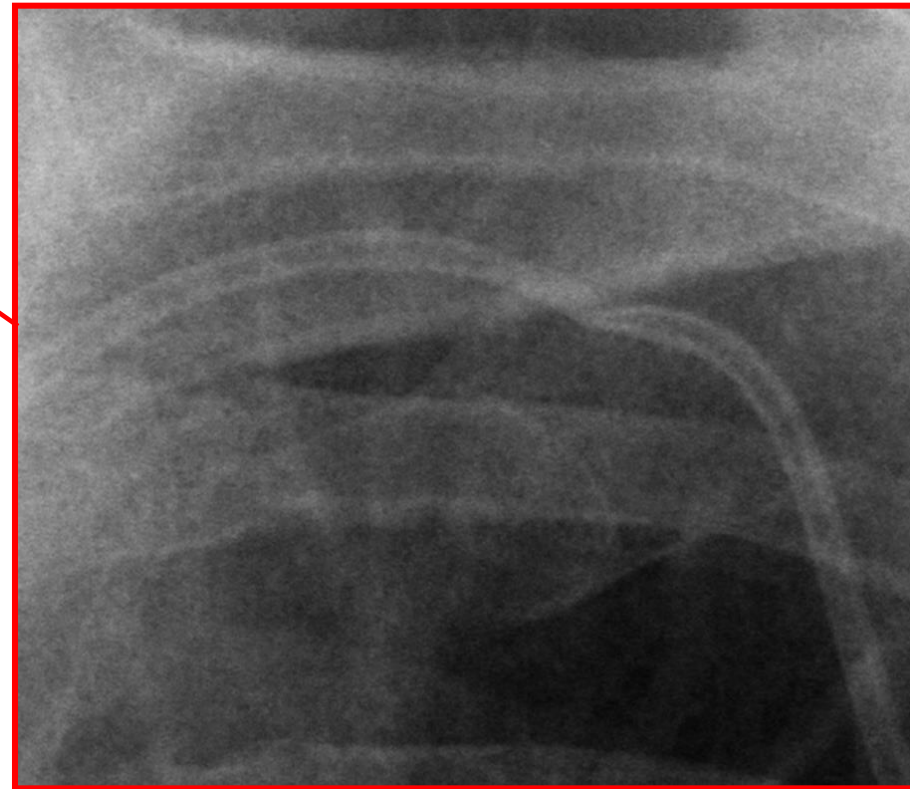
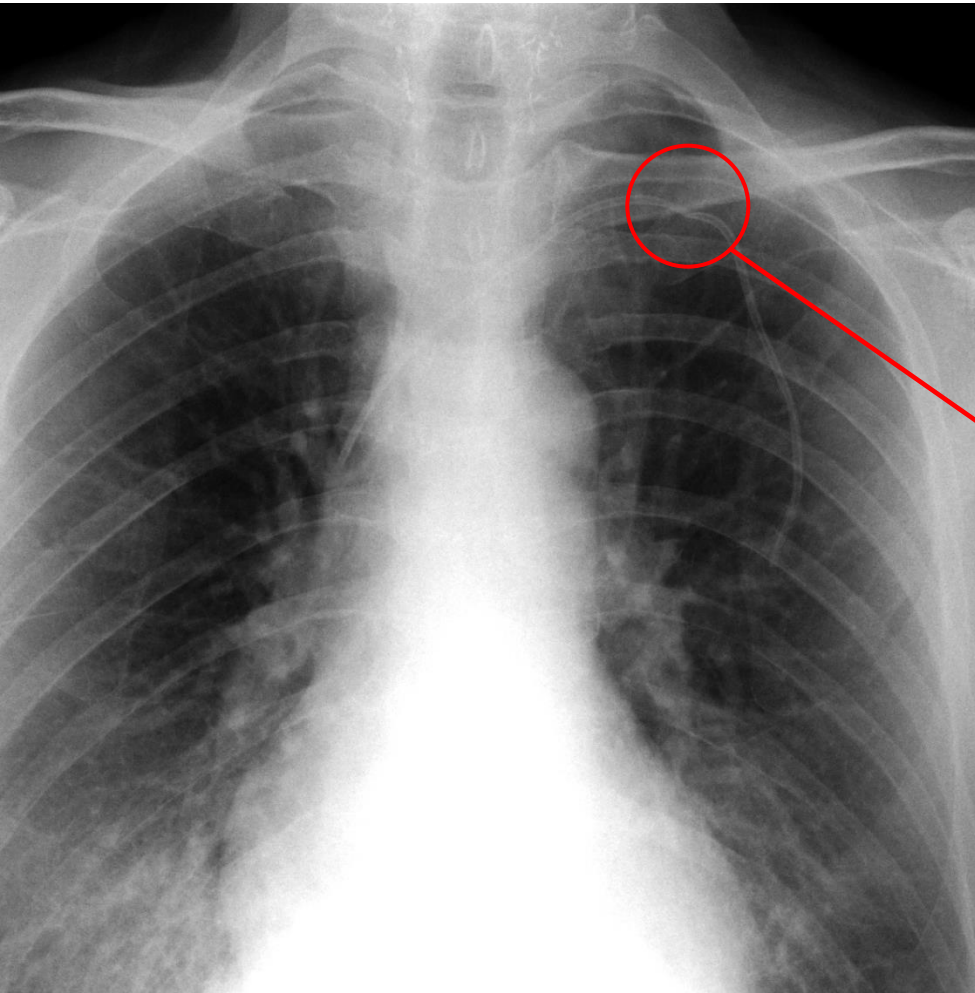


Cathéters centraux

Ex 6

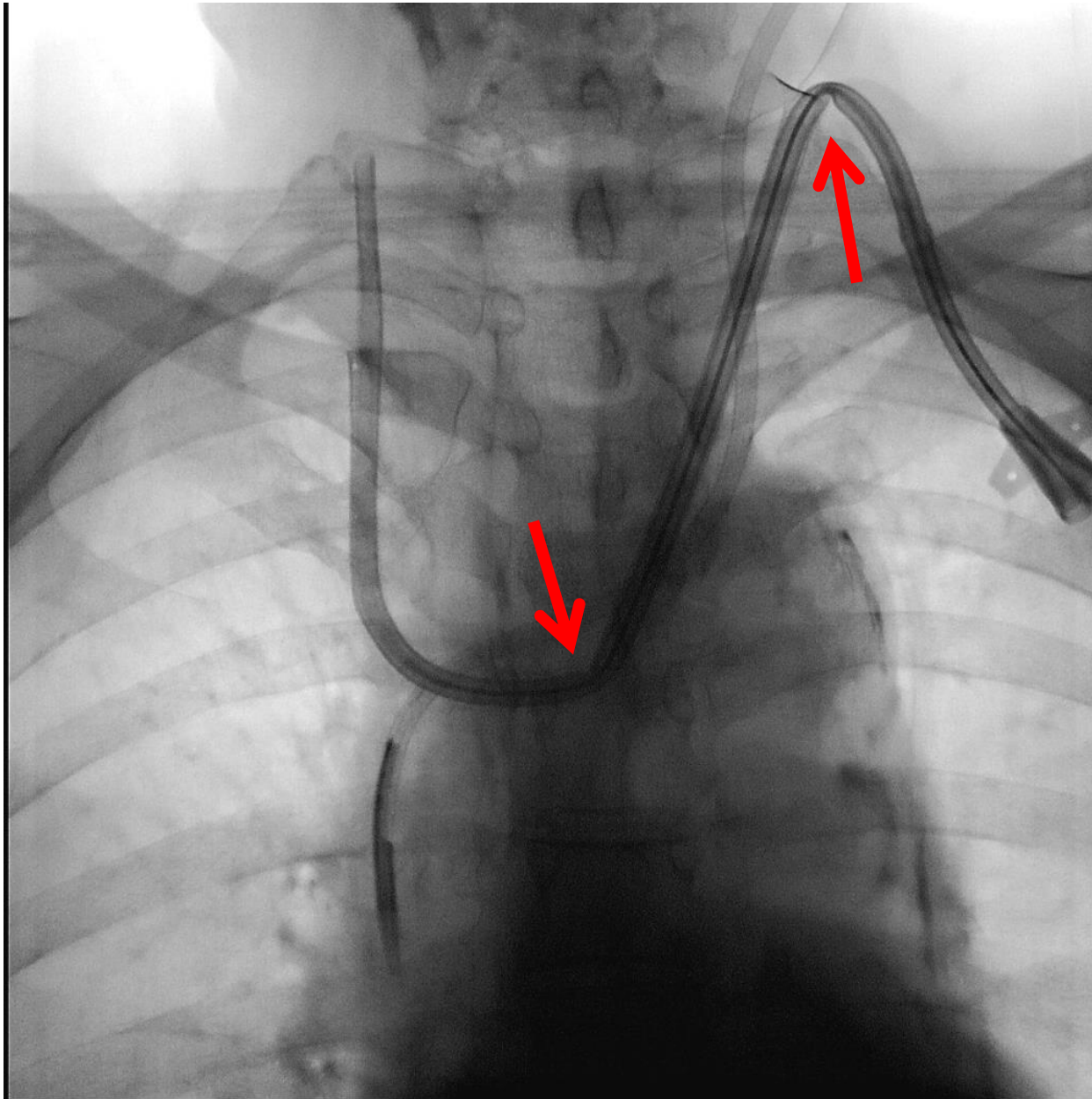


Cathéters centraux



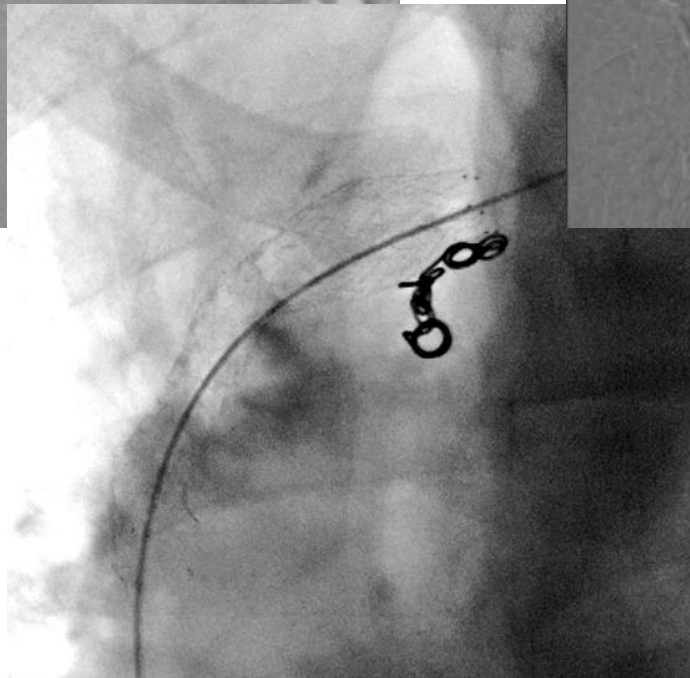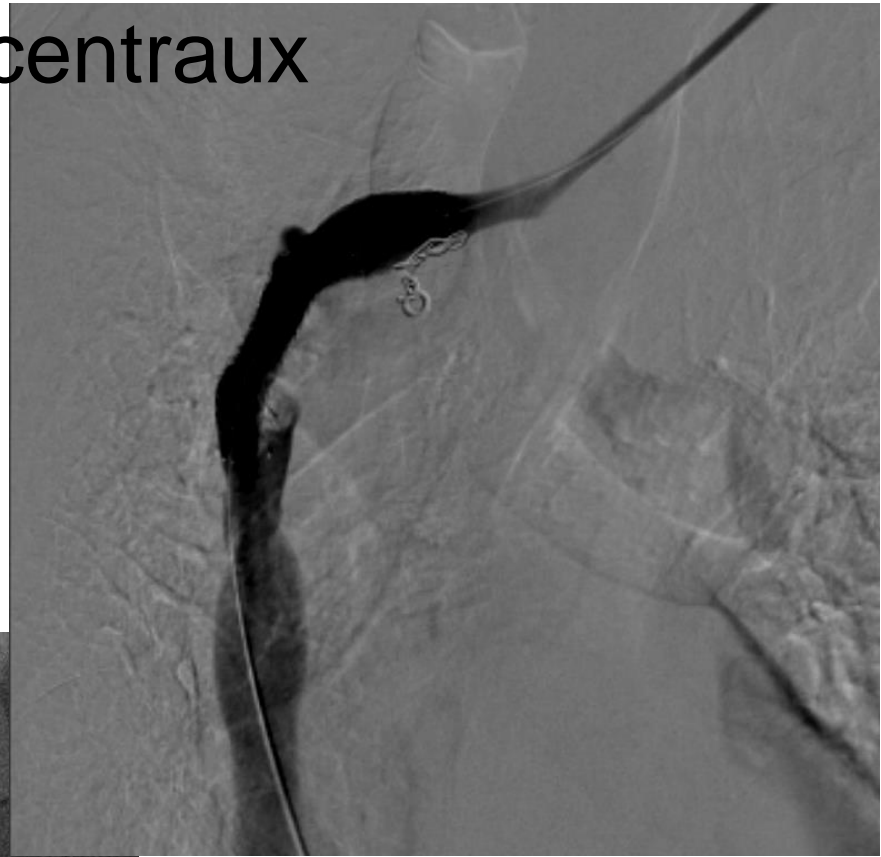
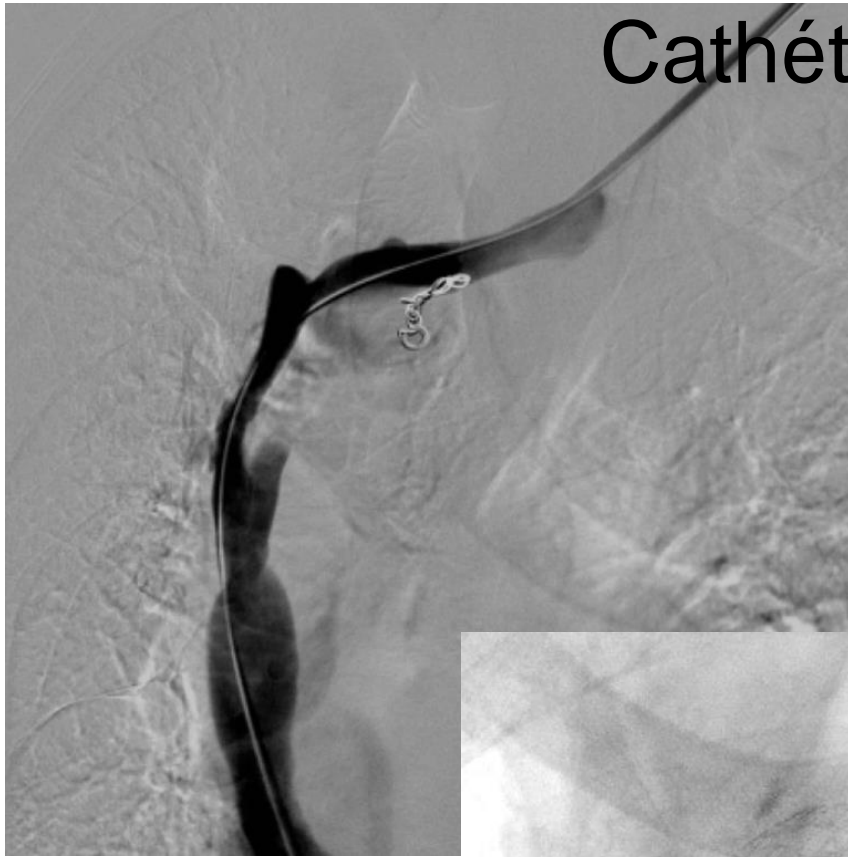


Impigement syndrome

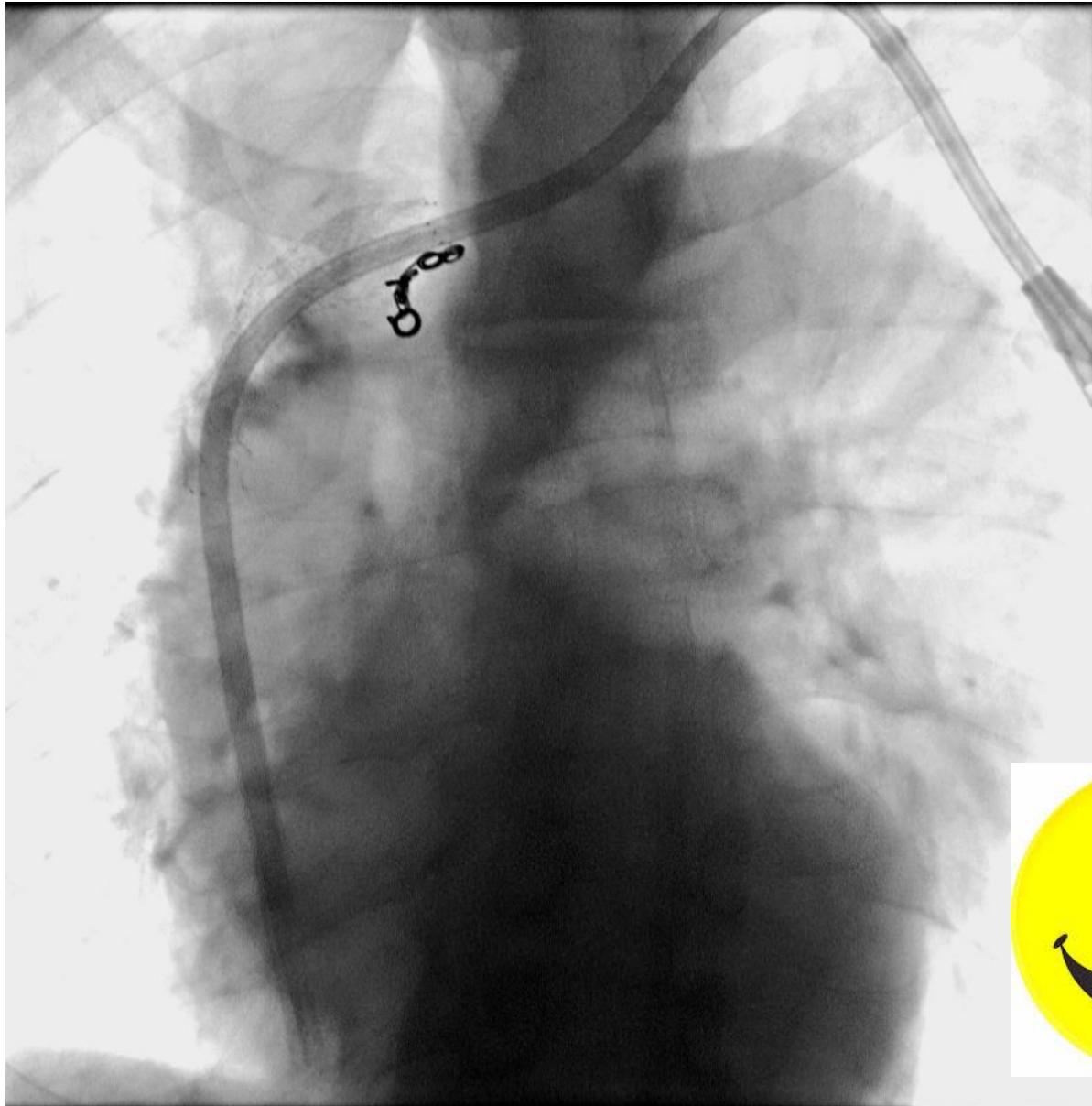
Cathéters centraux



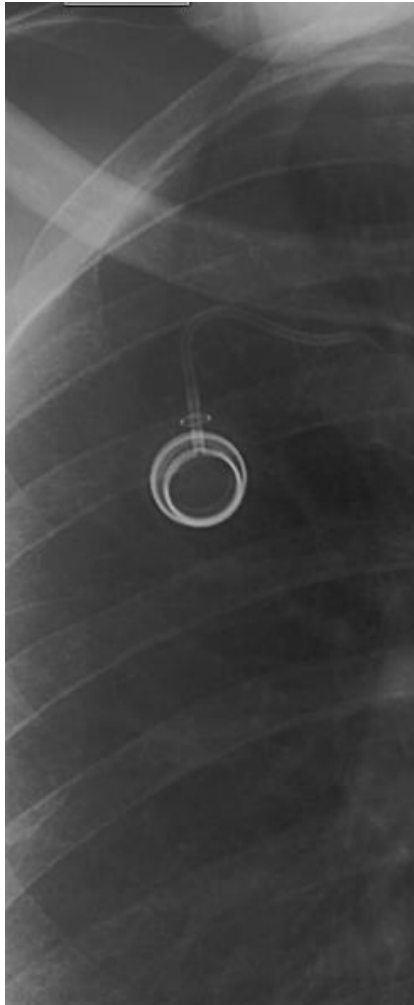
Cathéters centraux



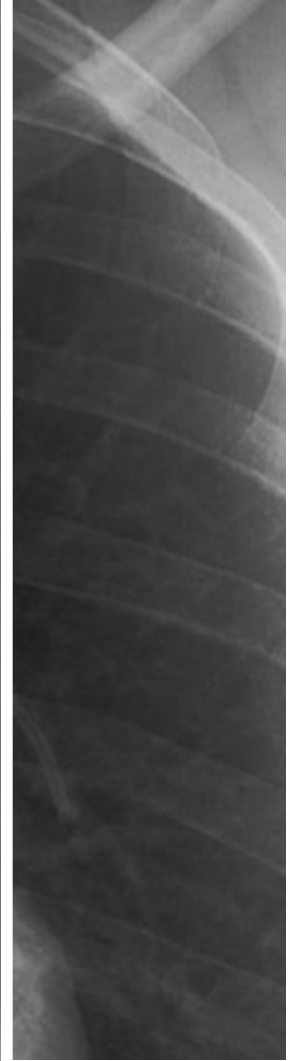
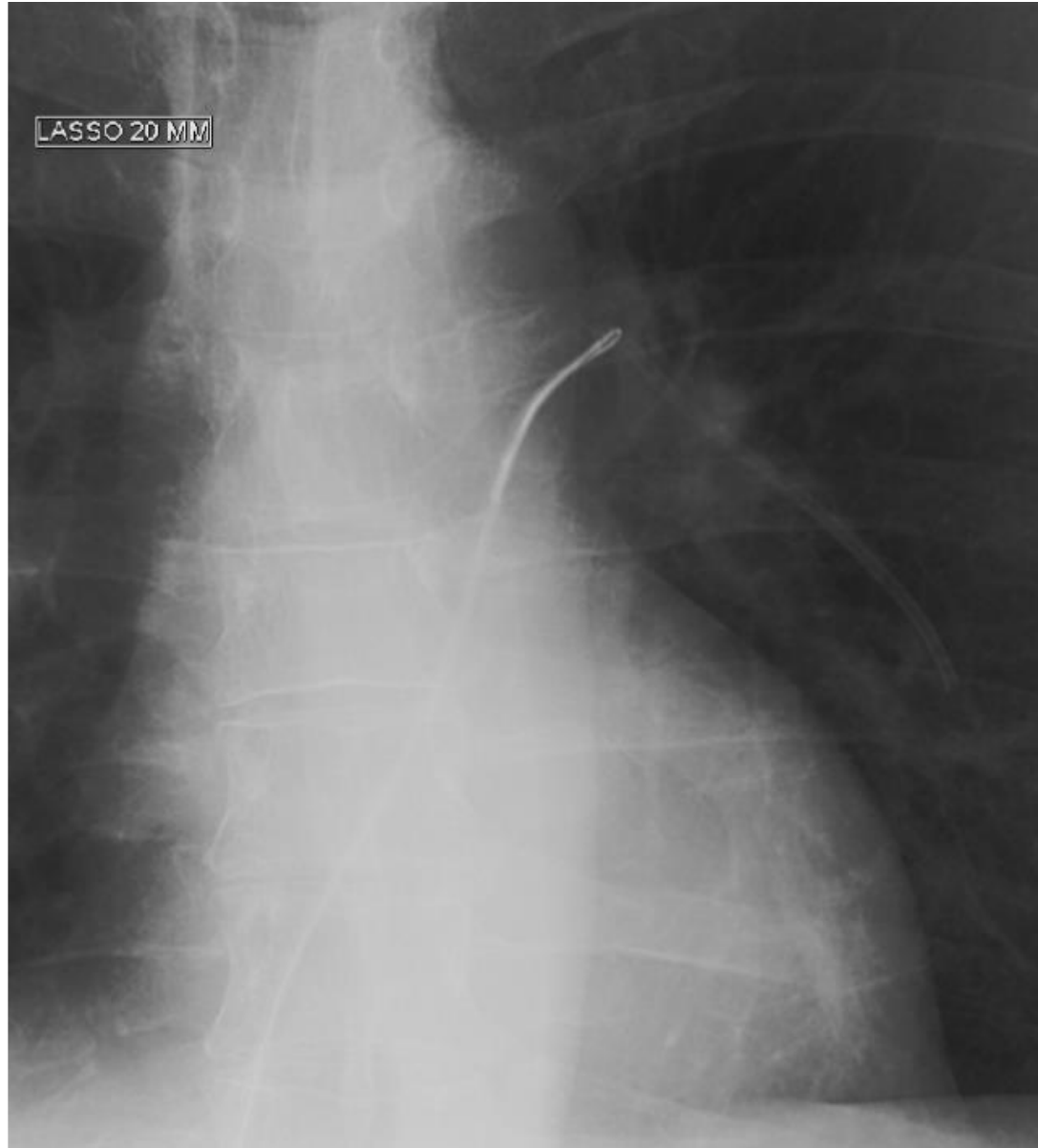Cathéters centraux



Cathéters centraux



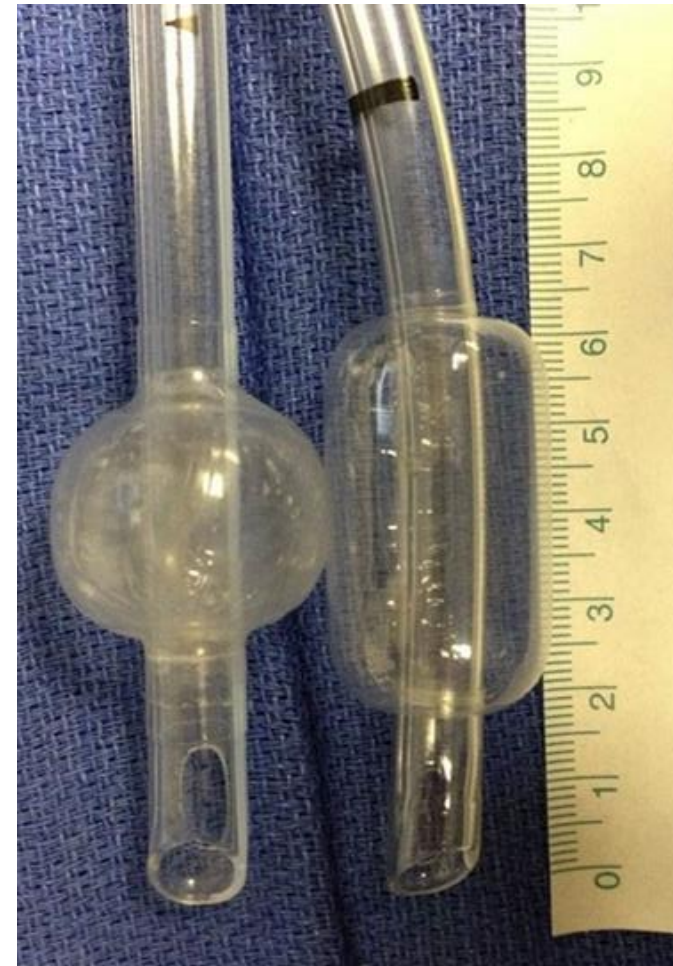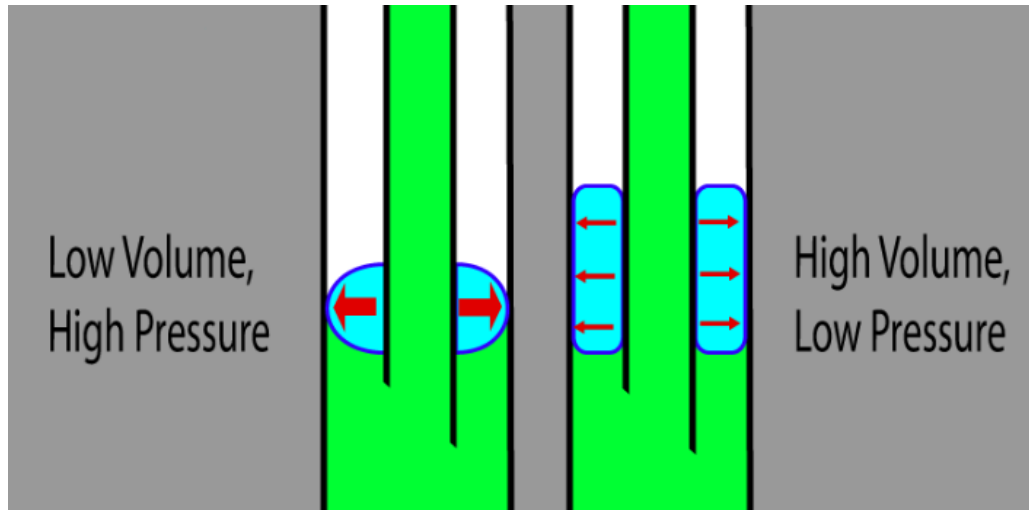
Rupture KT
Extraction CE



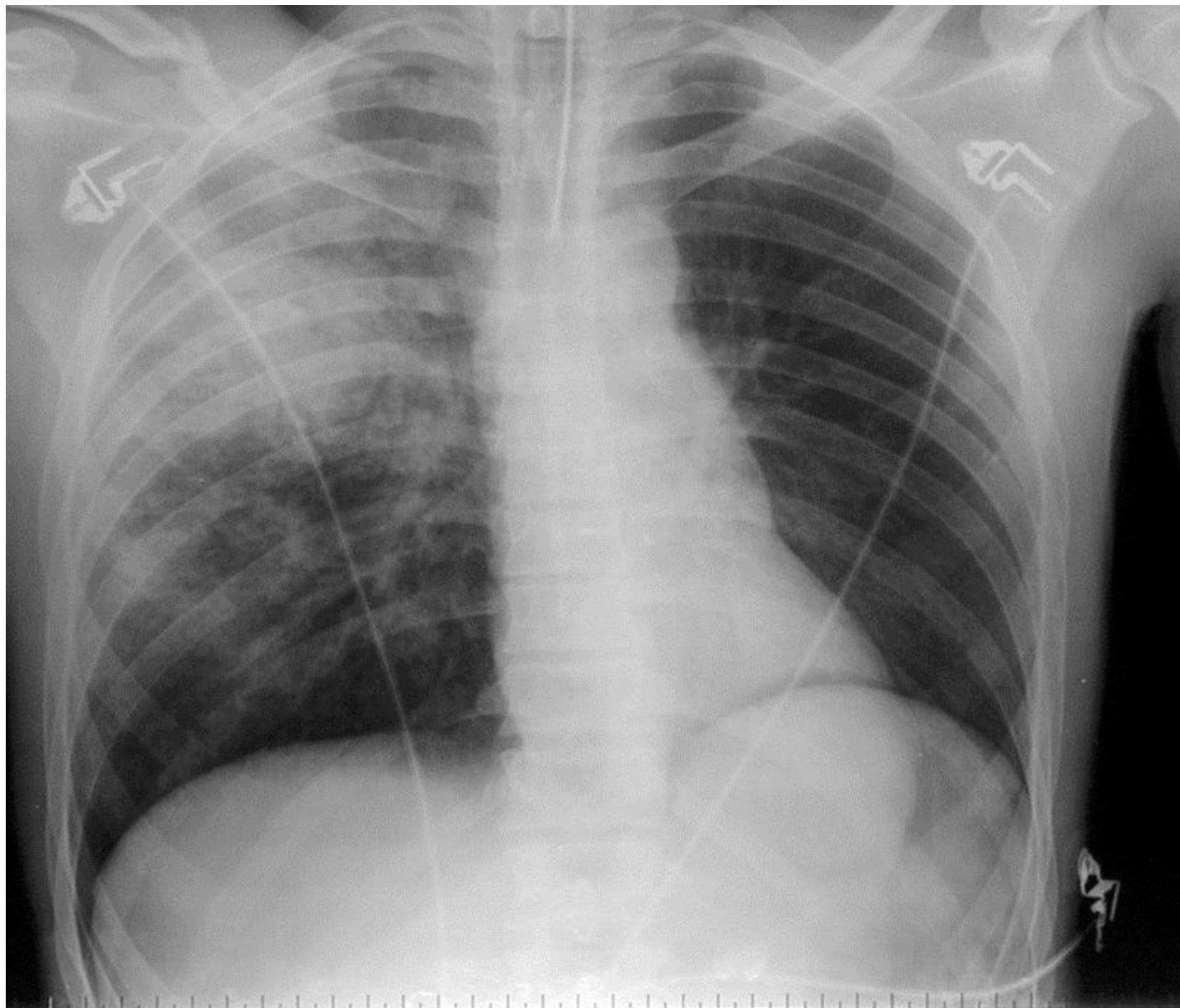
Tube endotrachéaux

- Idéal = extrémité à 5 cm de la trachée
- Extension du cou : → ascension de 2 cm
Flexion du cou : → descente de 2 cm
- Complications :
 - Trop haut: extubation, inhalation, spasme laryngé
 - Trop bas : intubation sélective
 - Malposition oesophagienne
 - Rupture trachéale ou oropharyngée

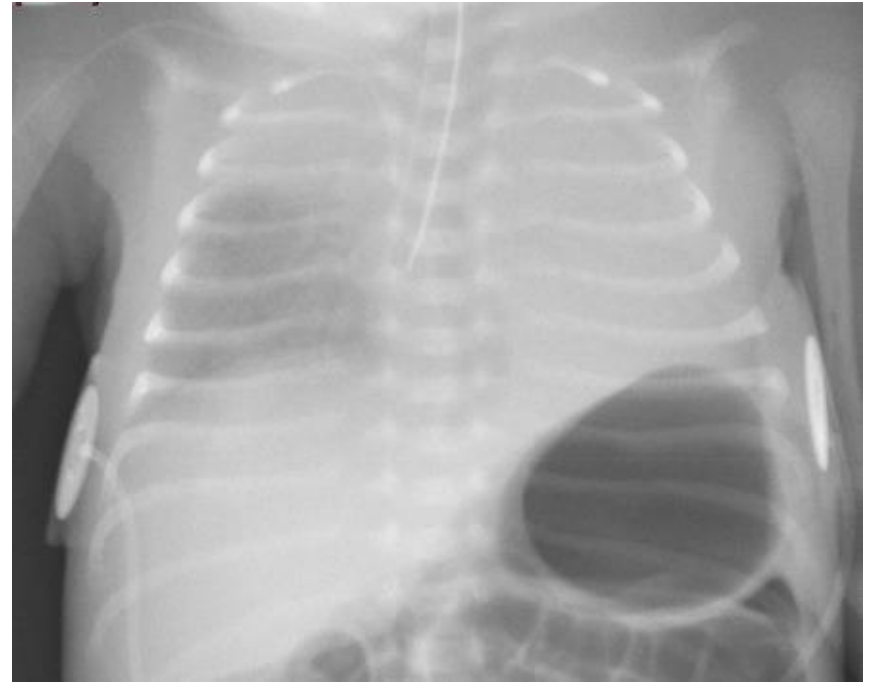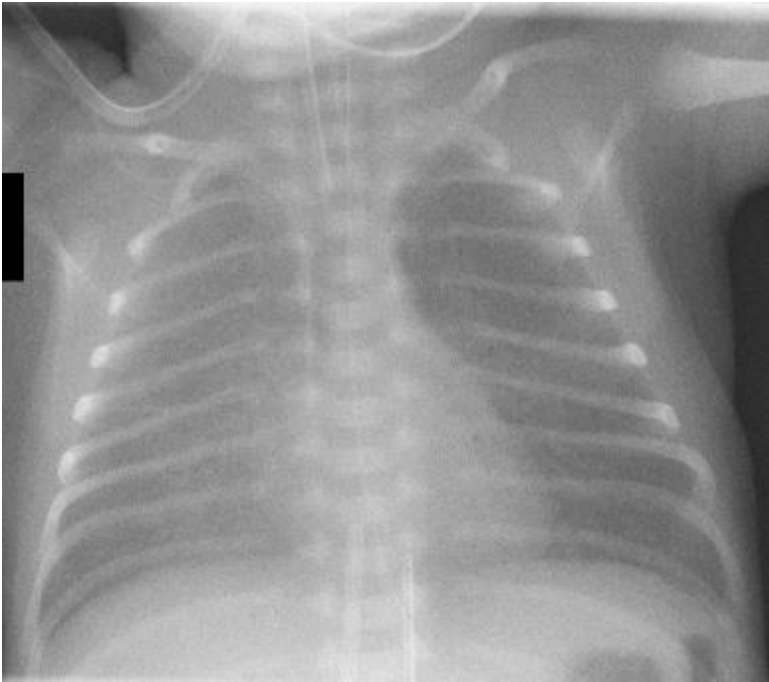
Tube endotrachéaux



Tube endotrachéaux

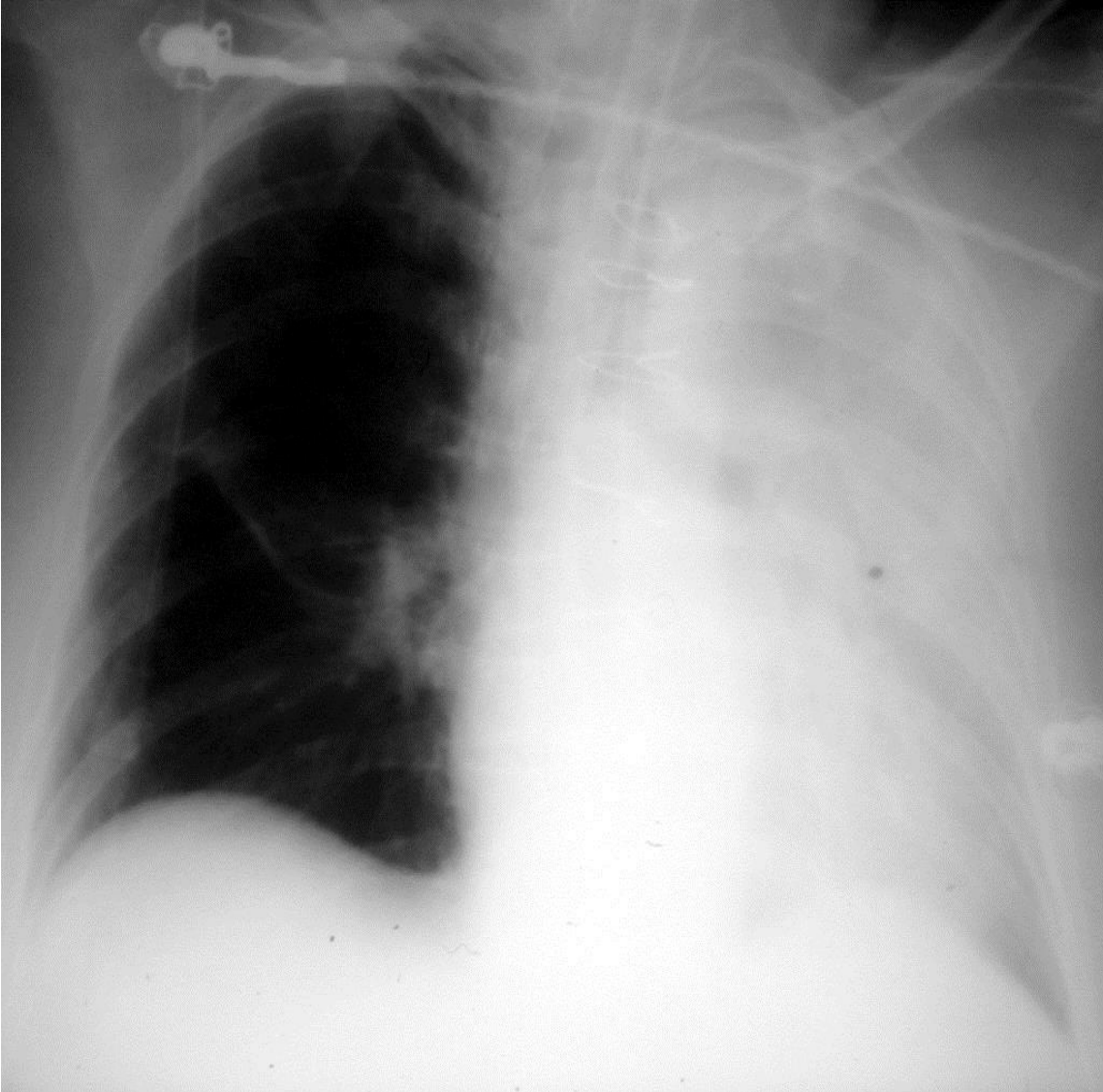


Tube endotrachéaux



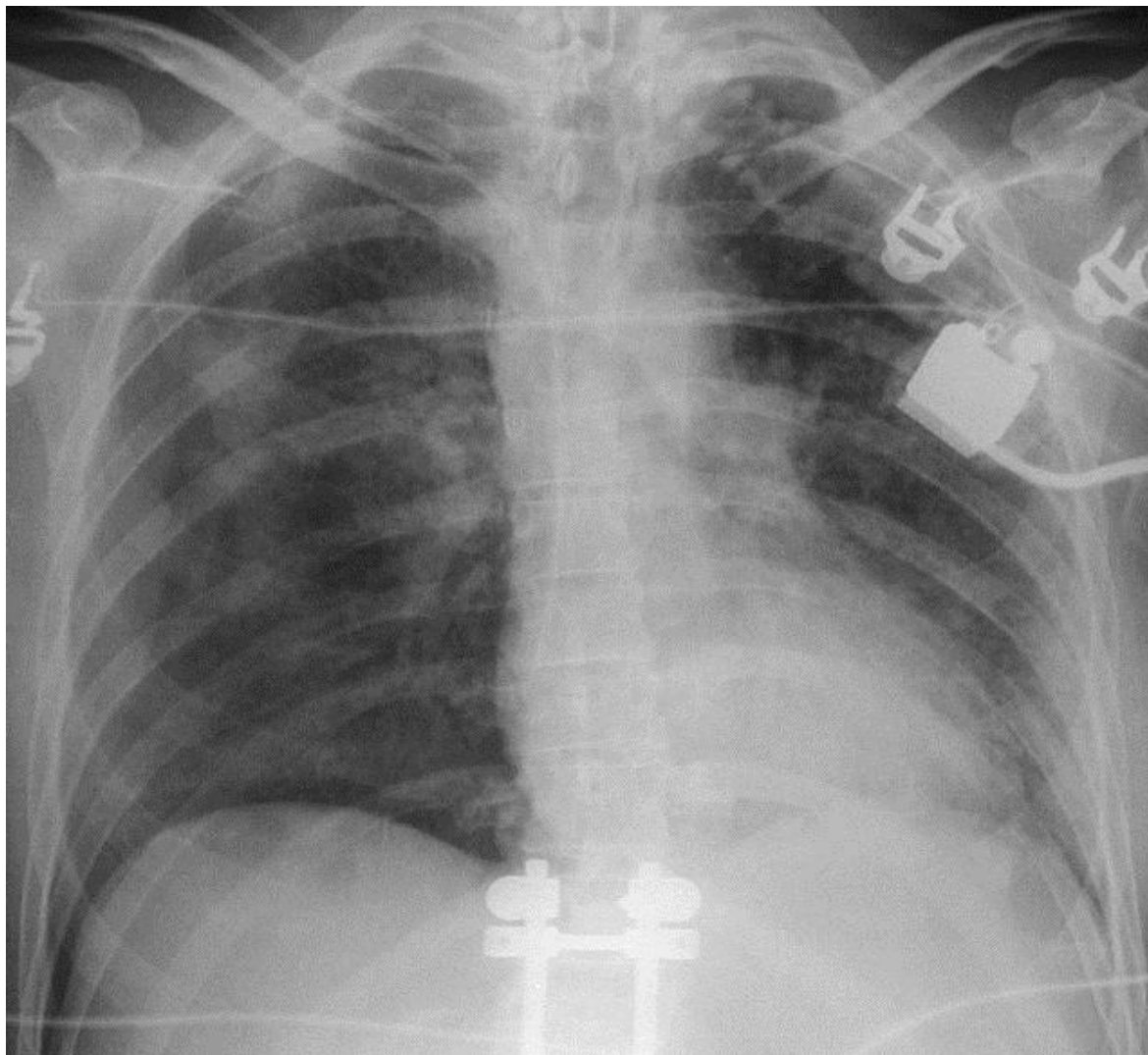
Intubation sélective BSD
Atelectasie poumon G

Tube endotrachéaux



Intubation sélective BSD
Atélectasie poumon G

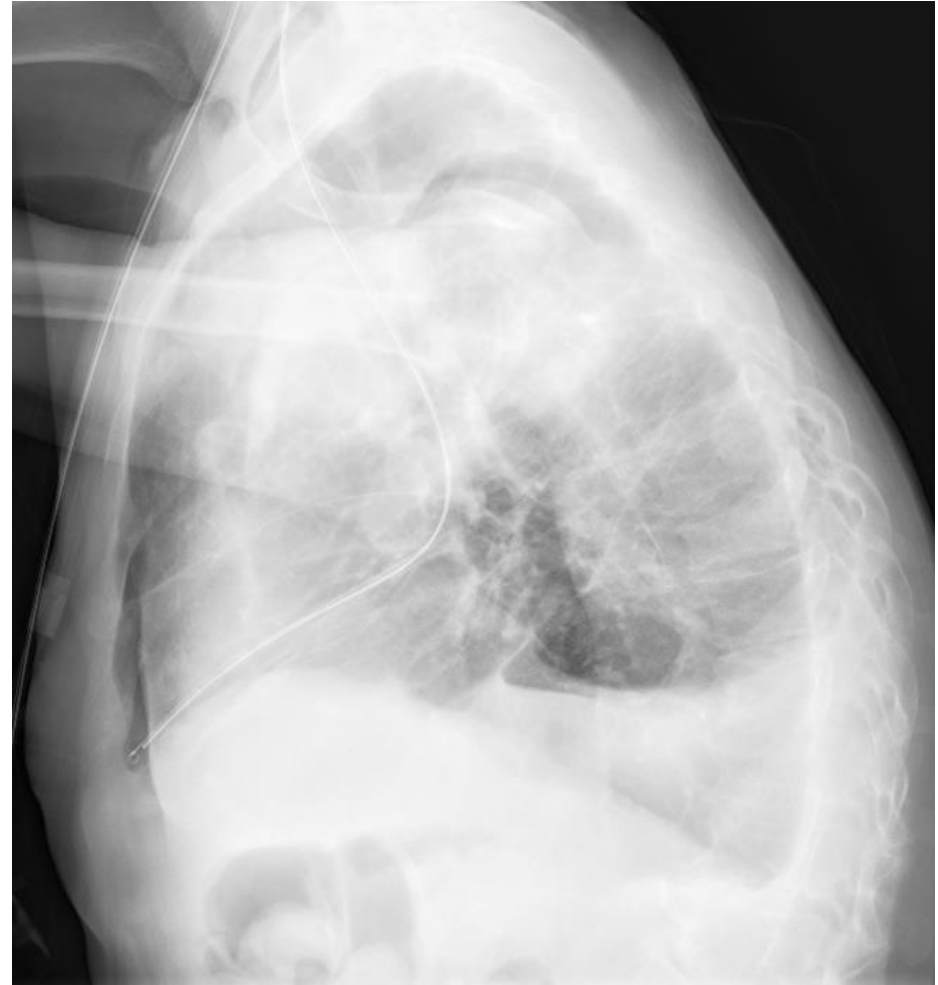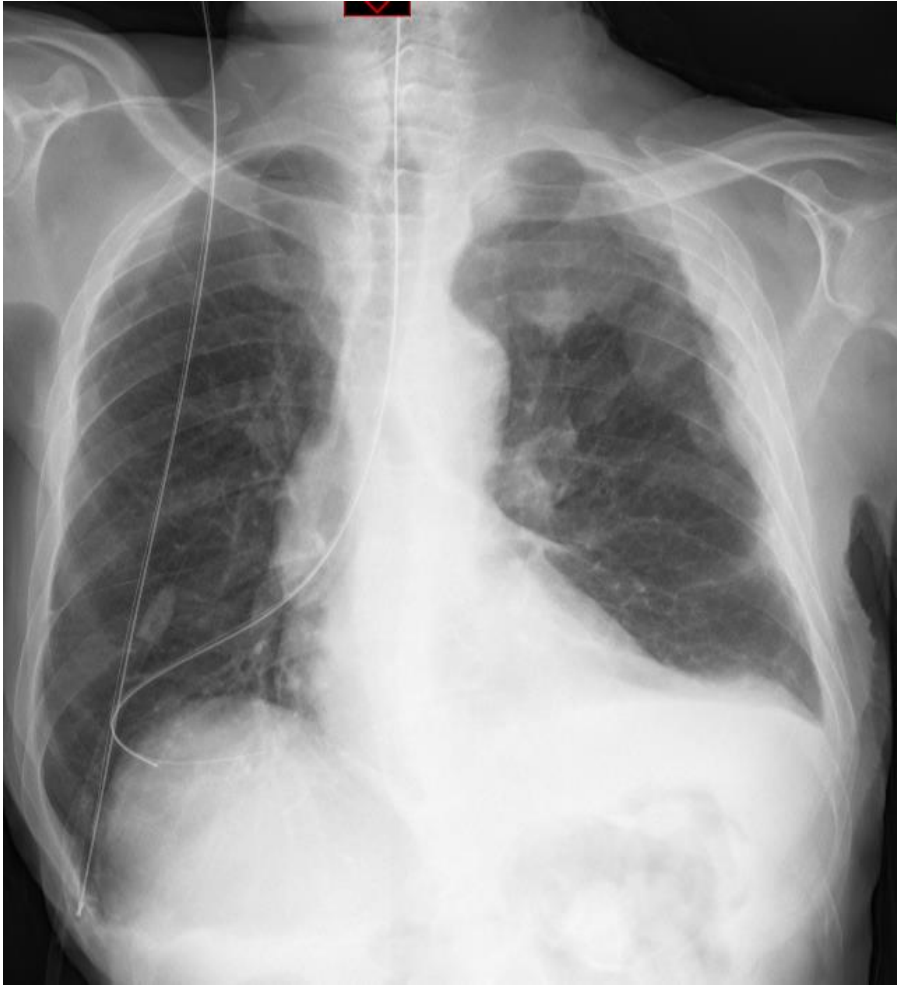Tube endotrachéaux



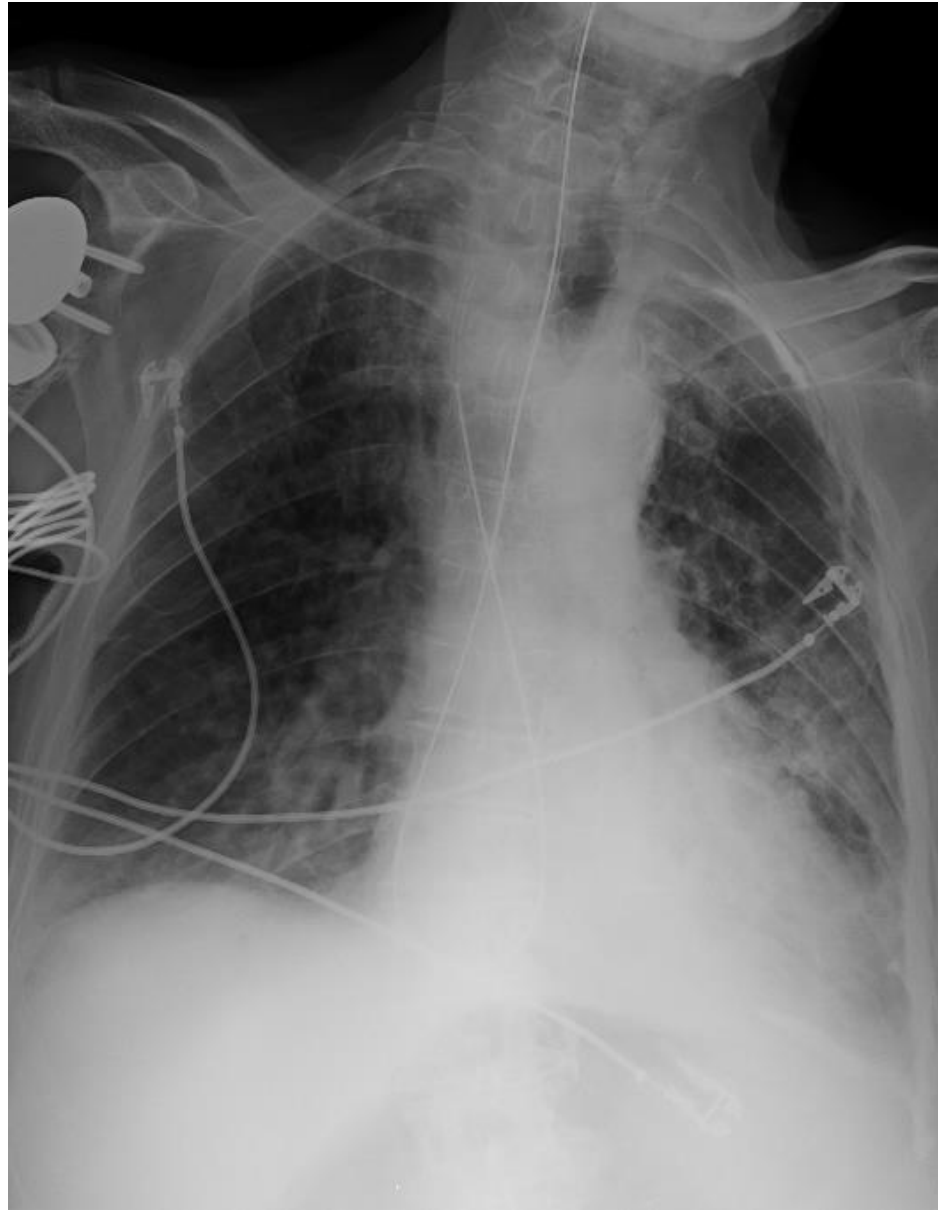Sonde nasogastrique

- Extrémité distale au delà du cardia
- Complications :
 - Malposition dans l'arbre trachéobronchique
 - Pneumonie sévère
 - Pneumothorax
 - Epanchement pleural
 - Perforation du tractus digestif supérieur (pharynx, oesophage, estomac)
 - Epanchement pleural, pneumothorax, pneumomédiastin

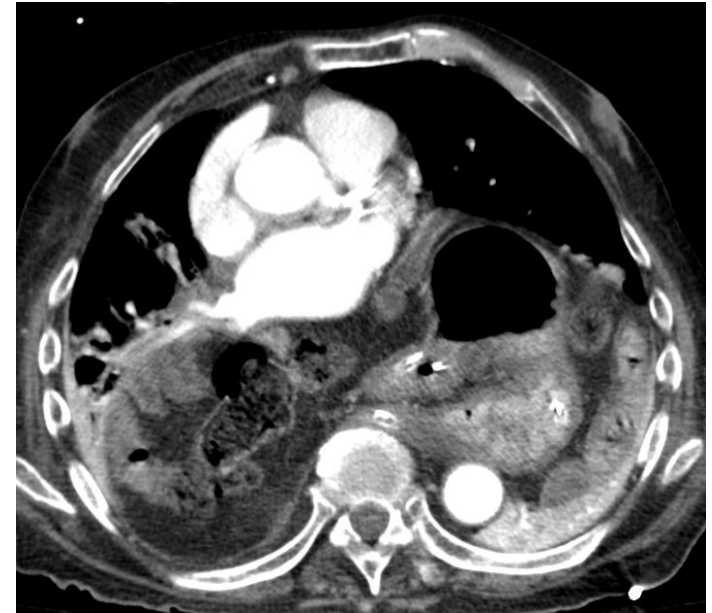
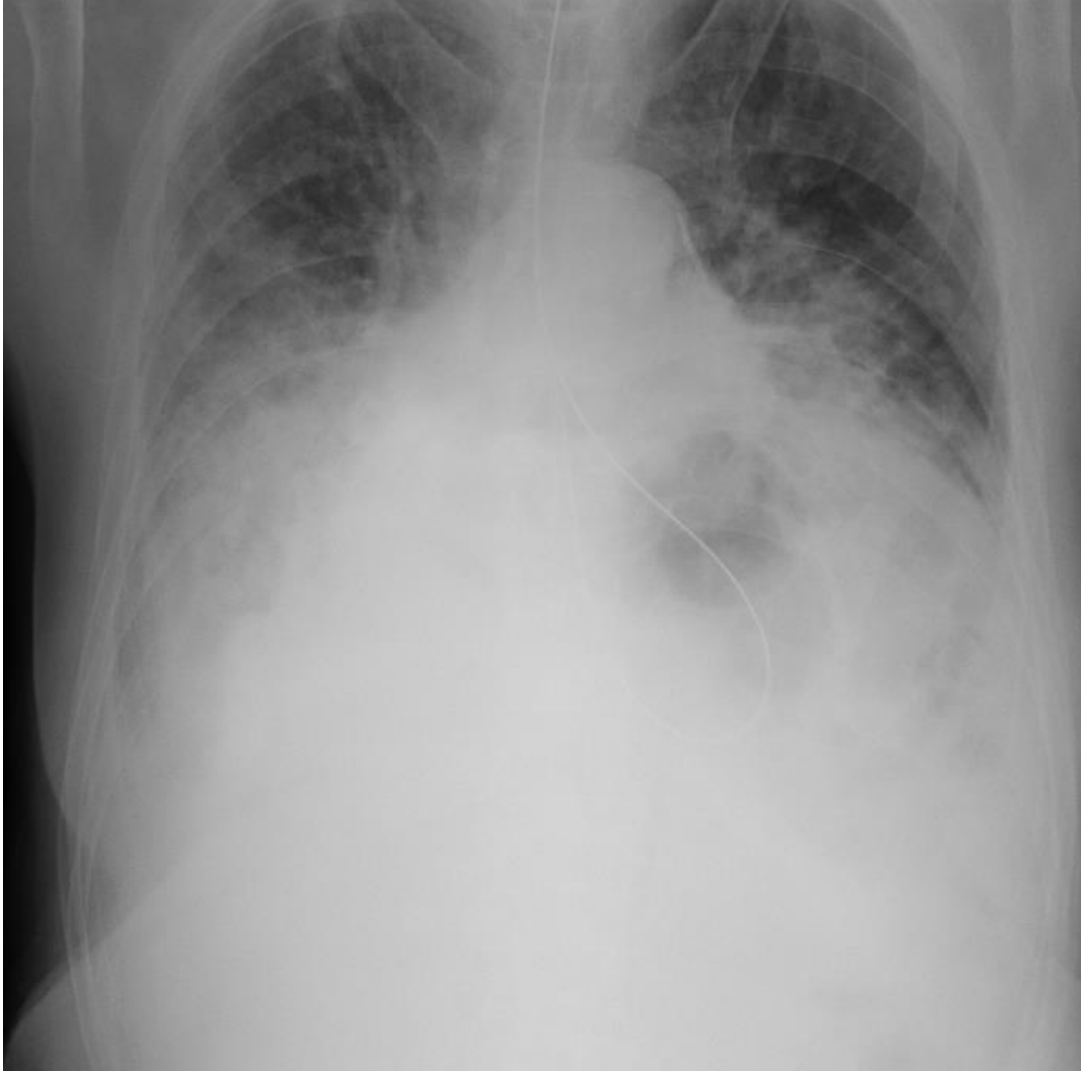Sonde nasogastrique



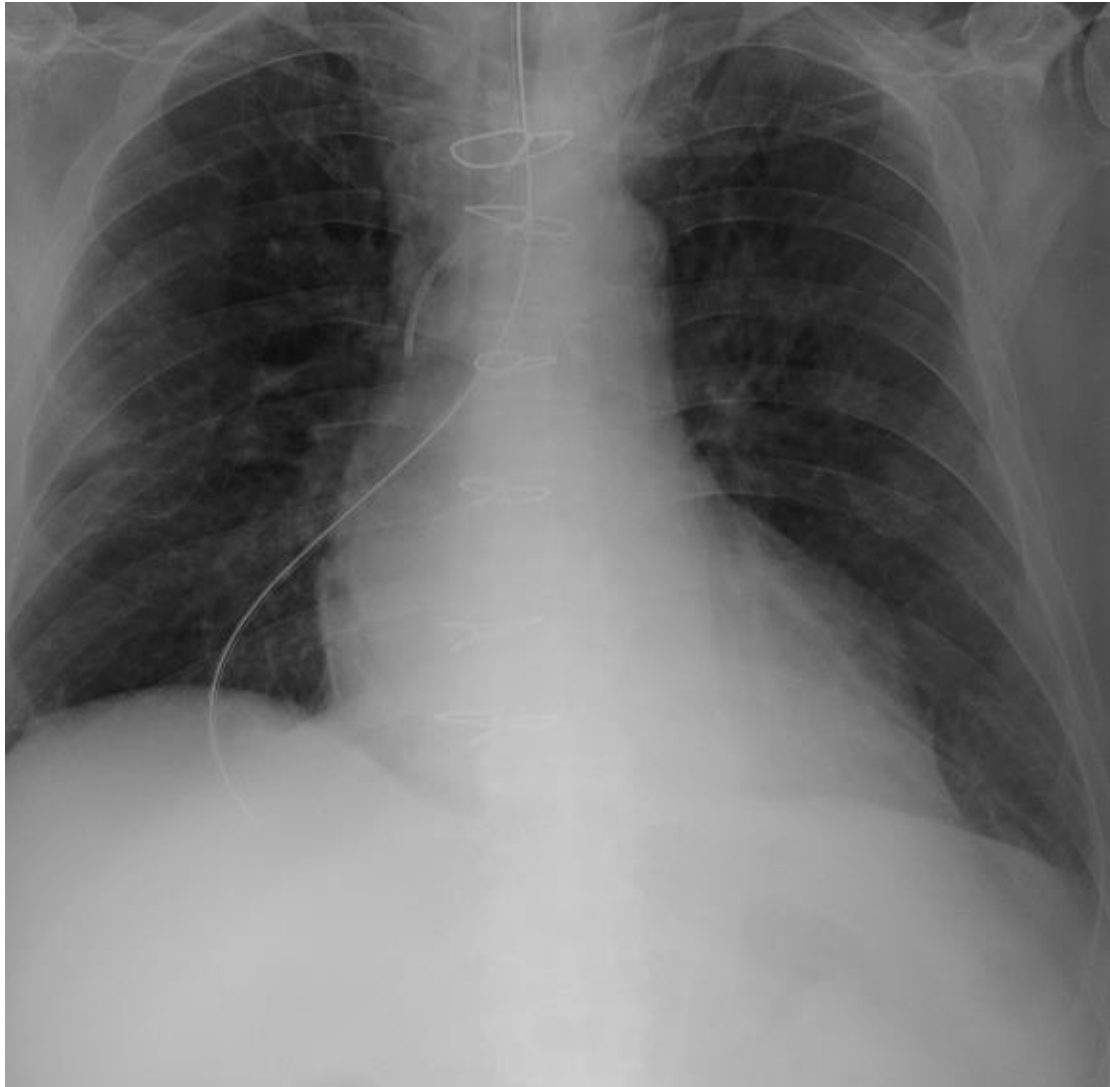Sonde nasogastrique



Sonde nasogastrique

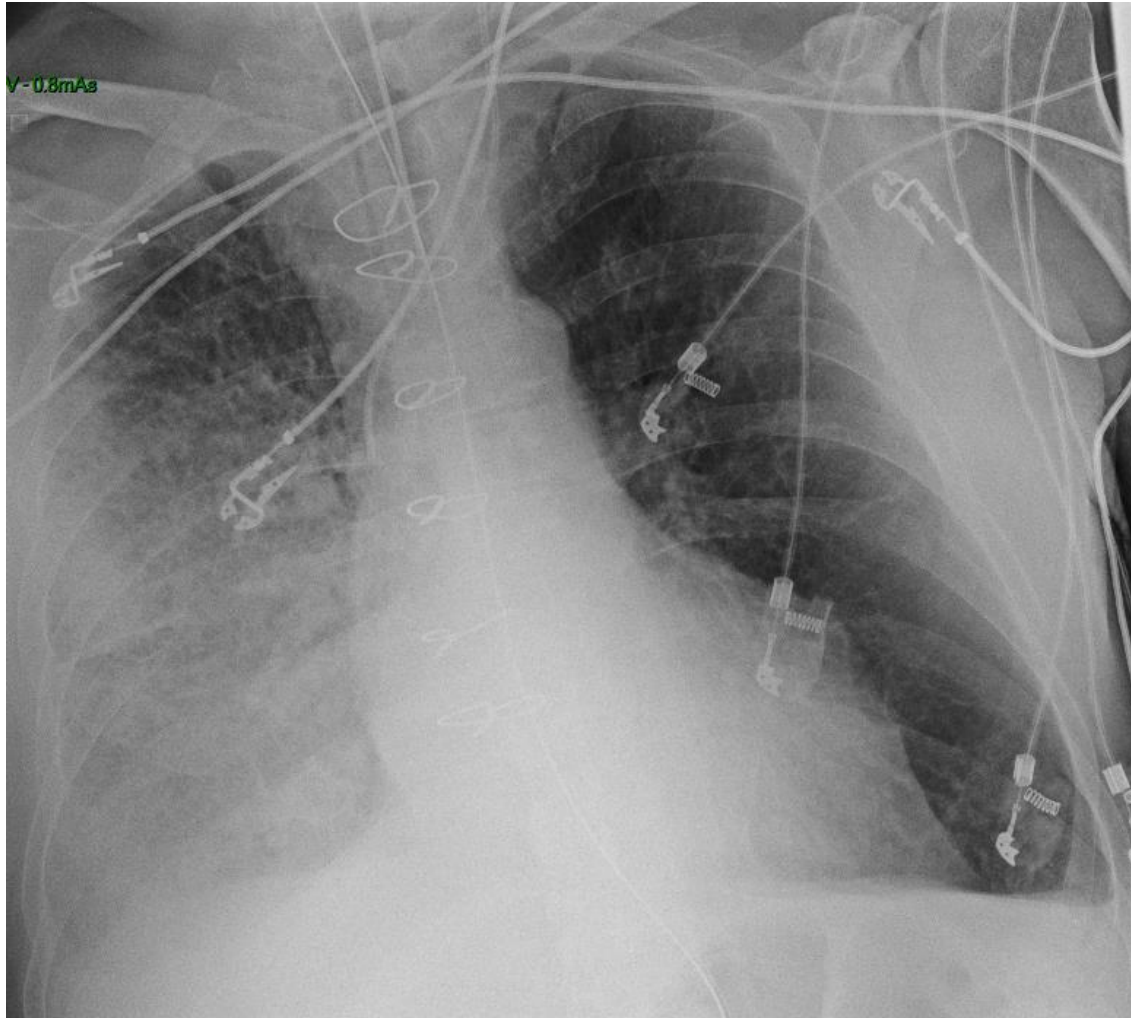


Sonde nasogastrique



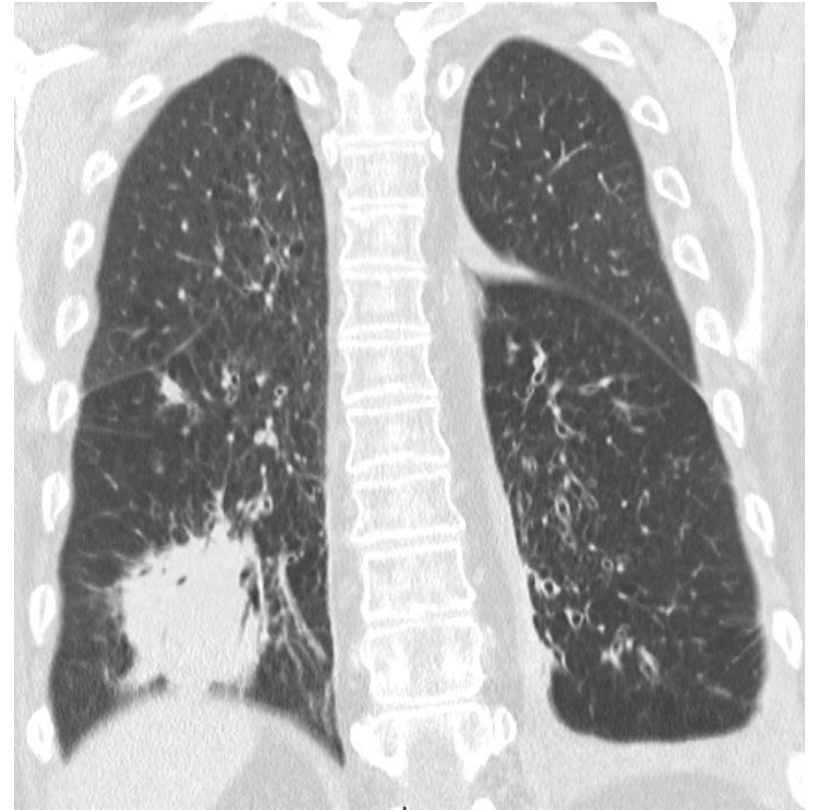
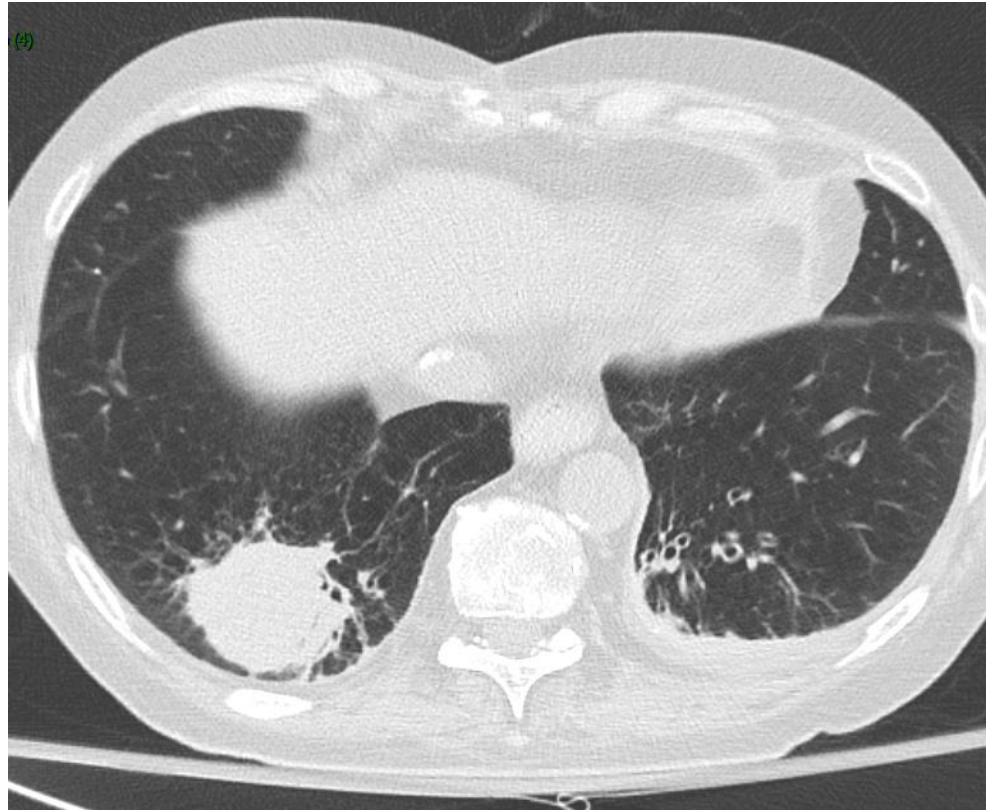
20/01/2016

Sonde nasogastrique



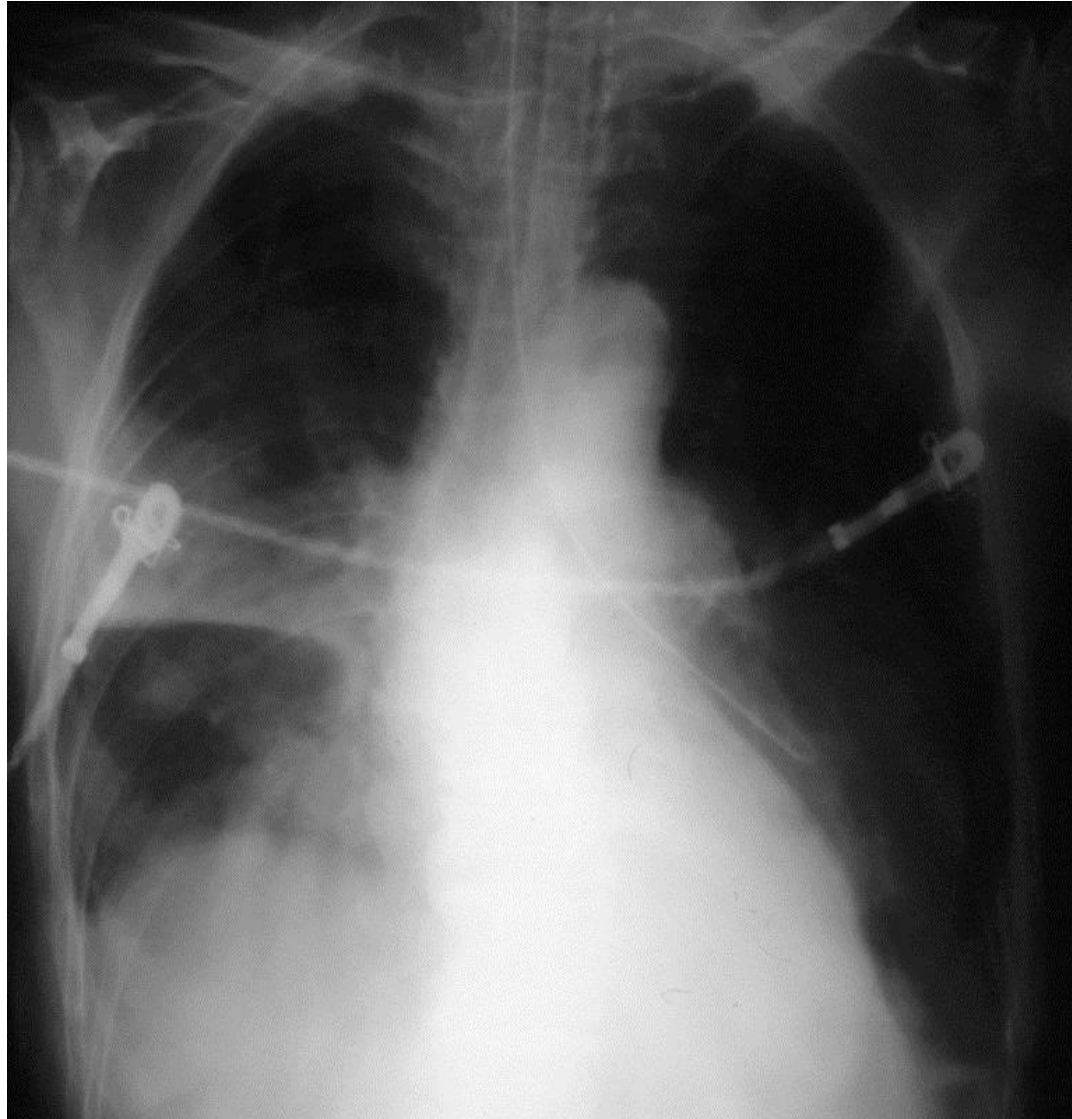
21/01/2016

Sonde nasogastrique



01/03/2016

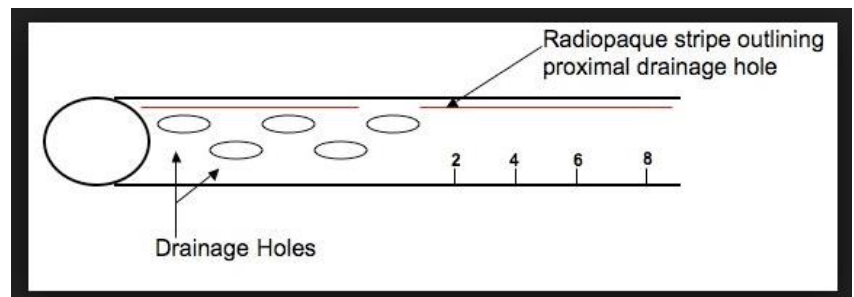

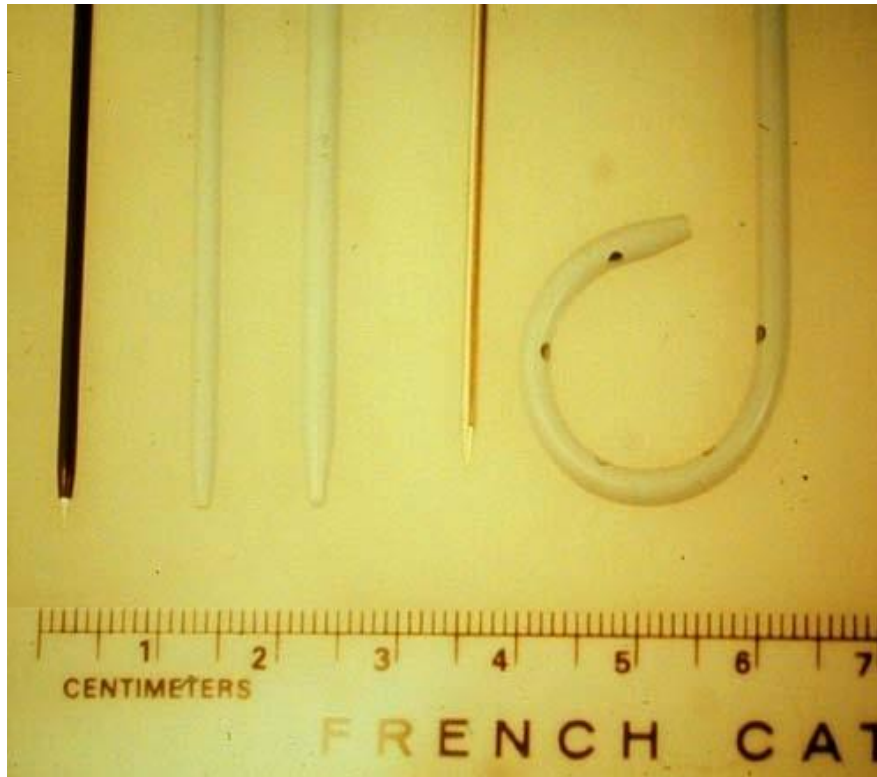
Sonde nasogastrique



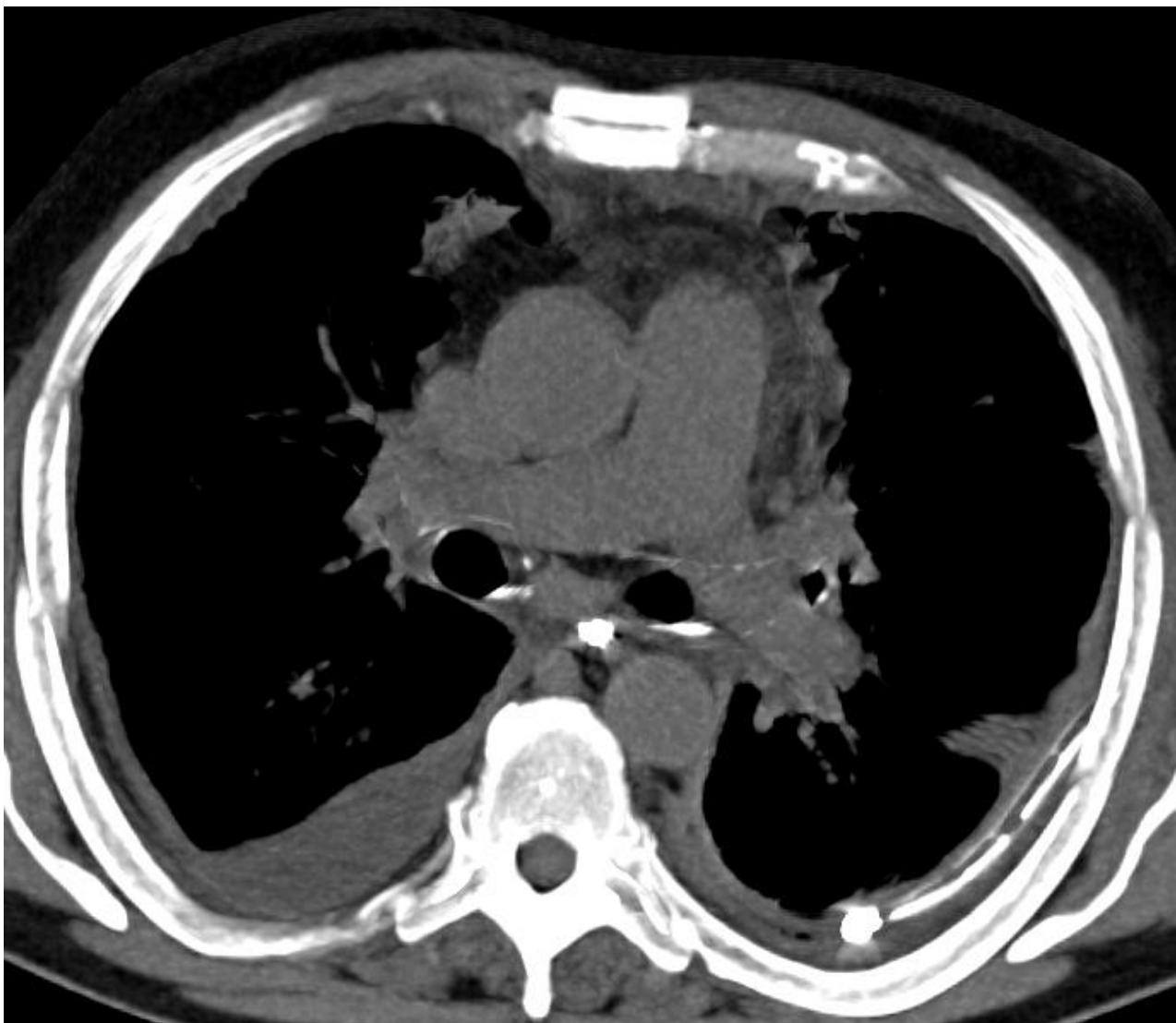
Drains pleuraux

- Position du tube difficile à évaluer sur un cliché de face seul
(pfs vues de profil ou oblique, CT)
- Complications :
 - Hémorragie alvéolaire au pourtour du tube = intra-pulmonaire
 - Infarctus pulmonaire
 - Lacération d'organe sous-phrénique
 - Abscess de paroi
 - Syndrome de Claude-Bernard-Horner

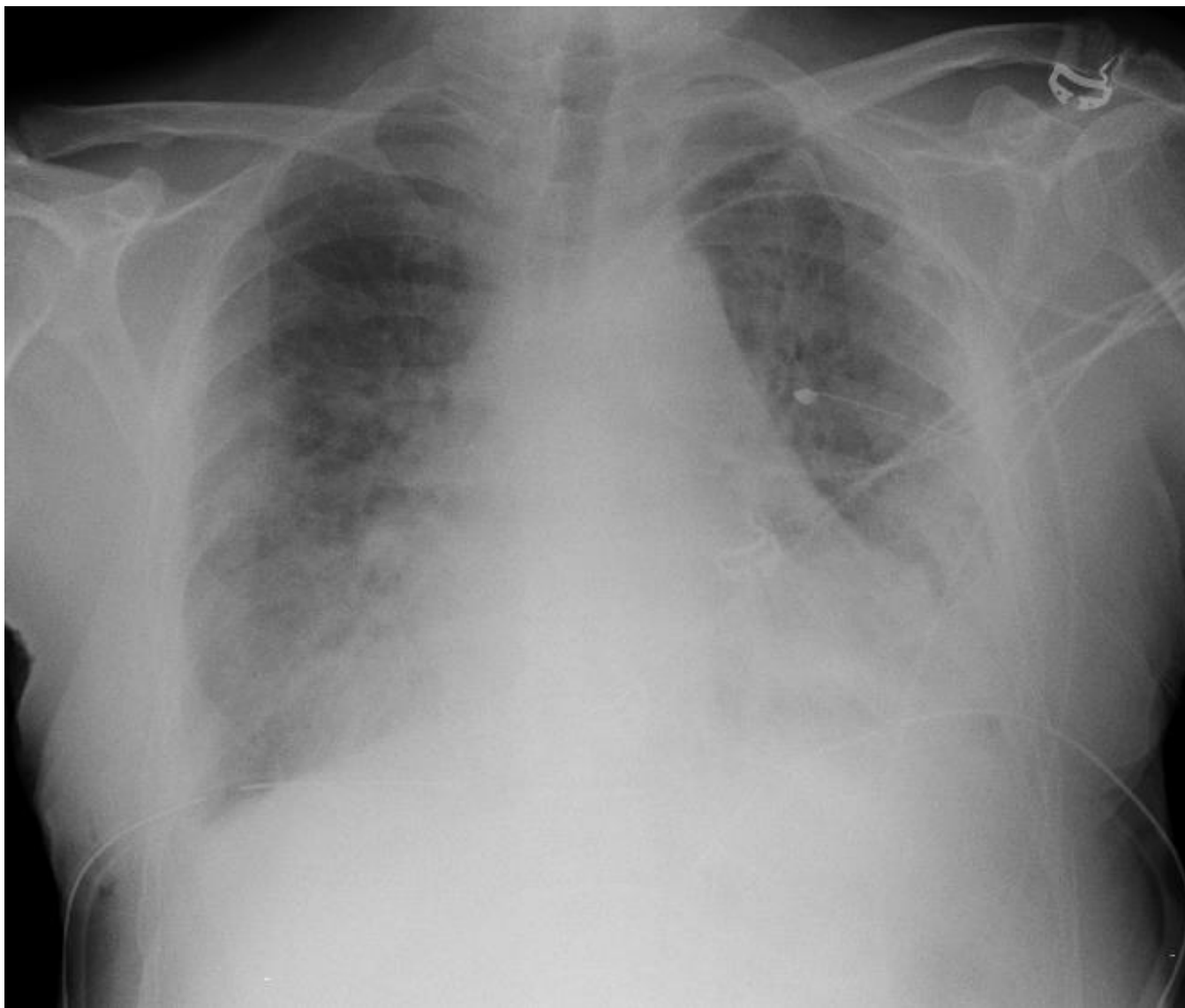
Drains pleuraux



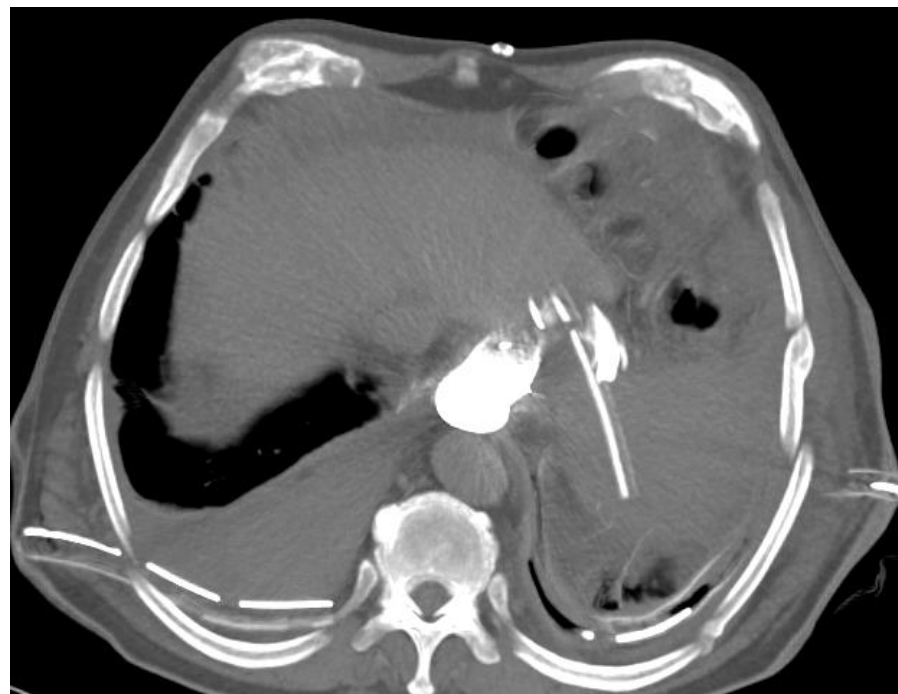
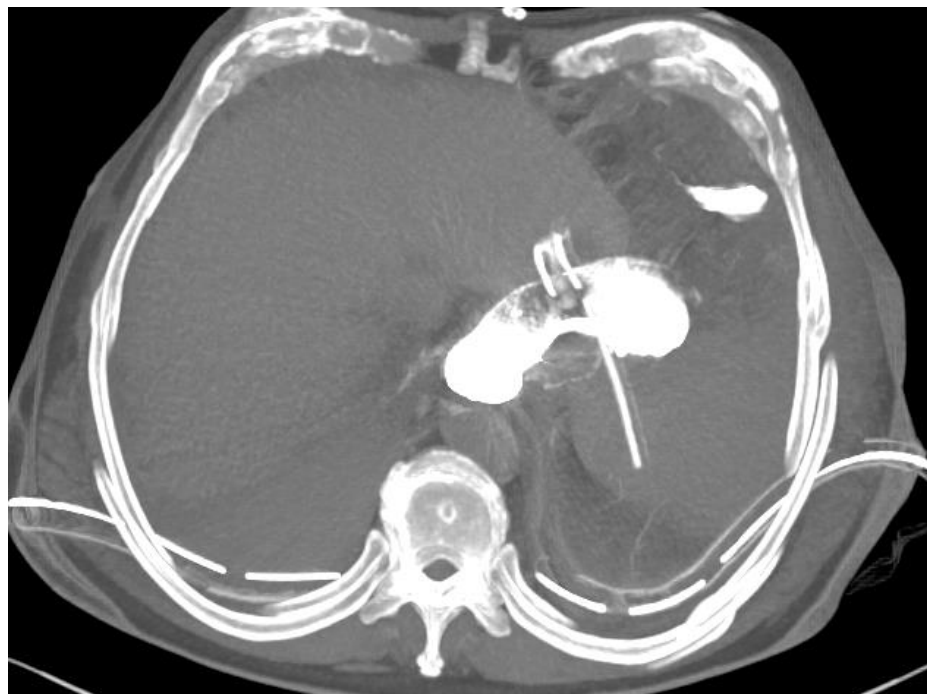
Drains pleuraux



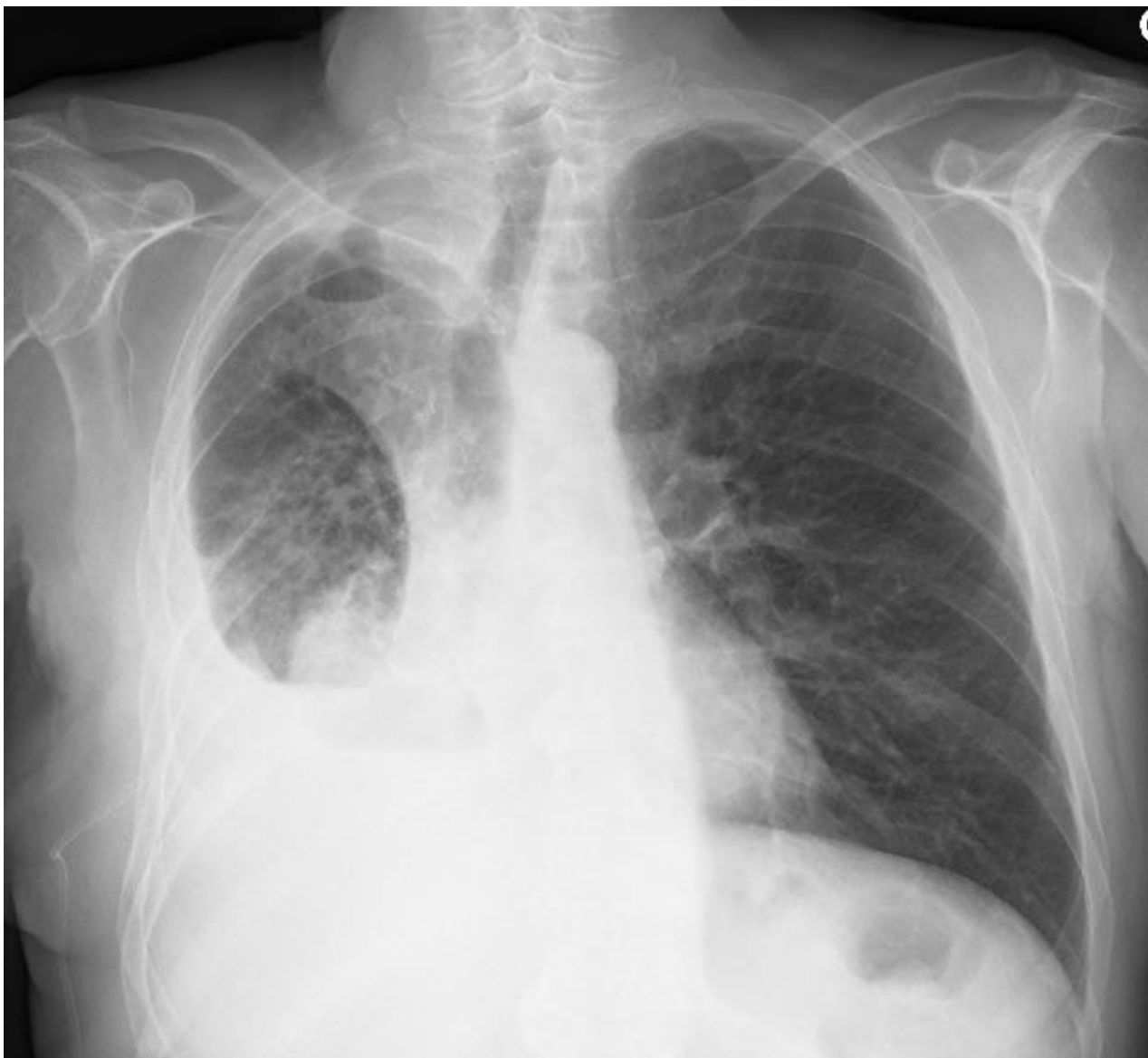Drains pleuraux



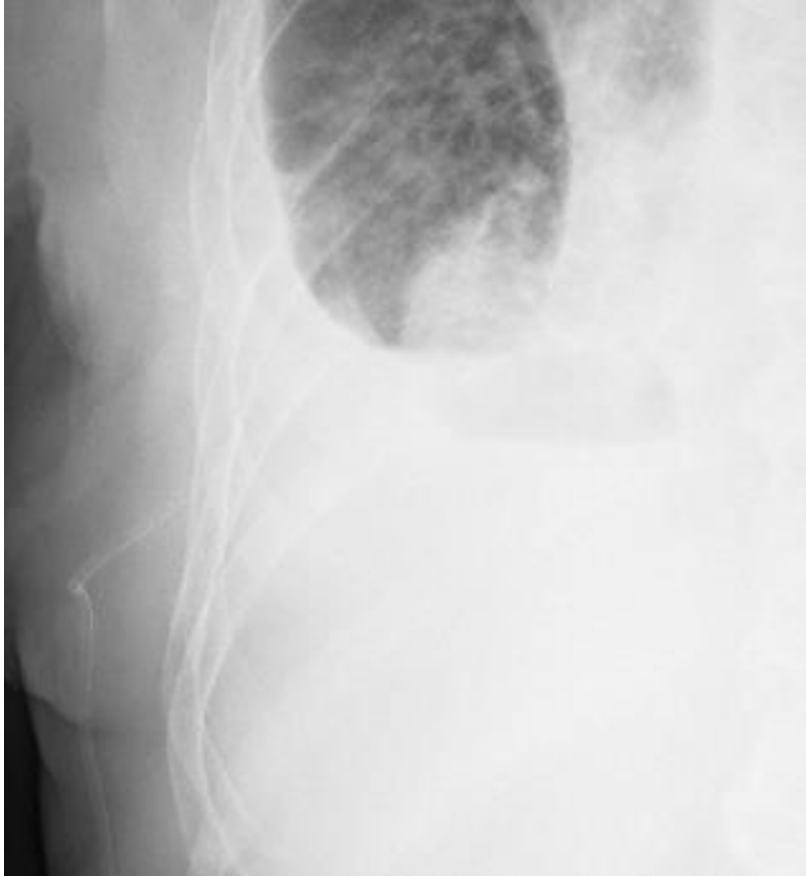Drains pleuraux



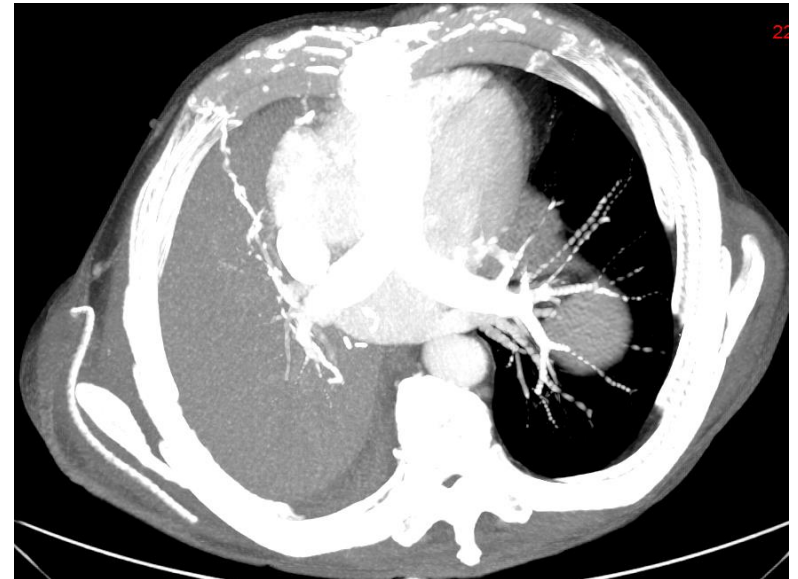
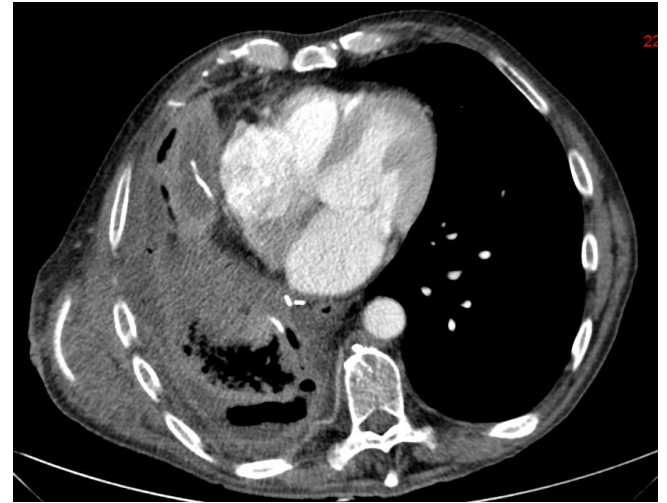Drains pleuraux



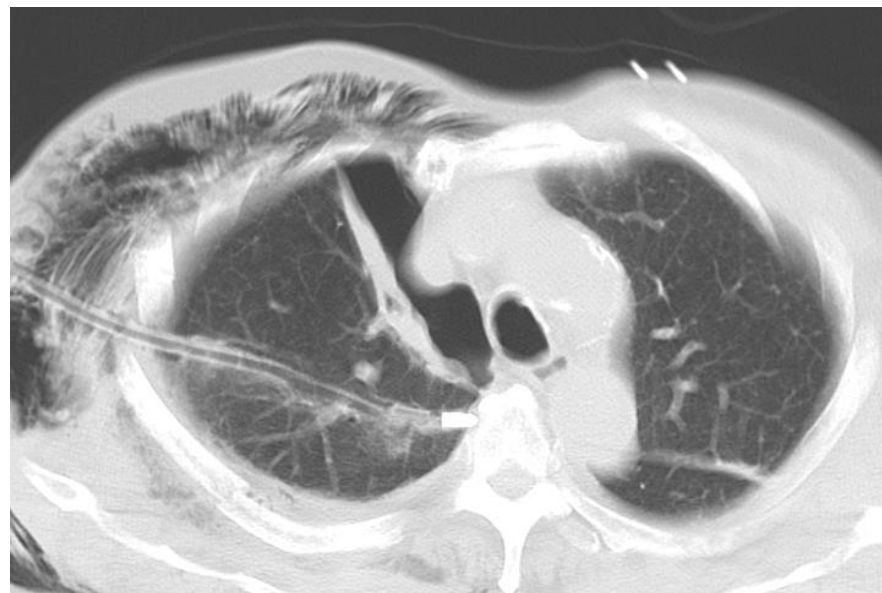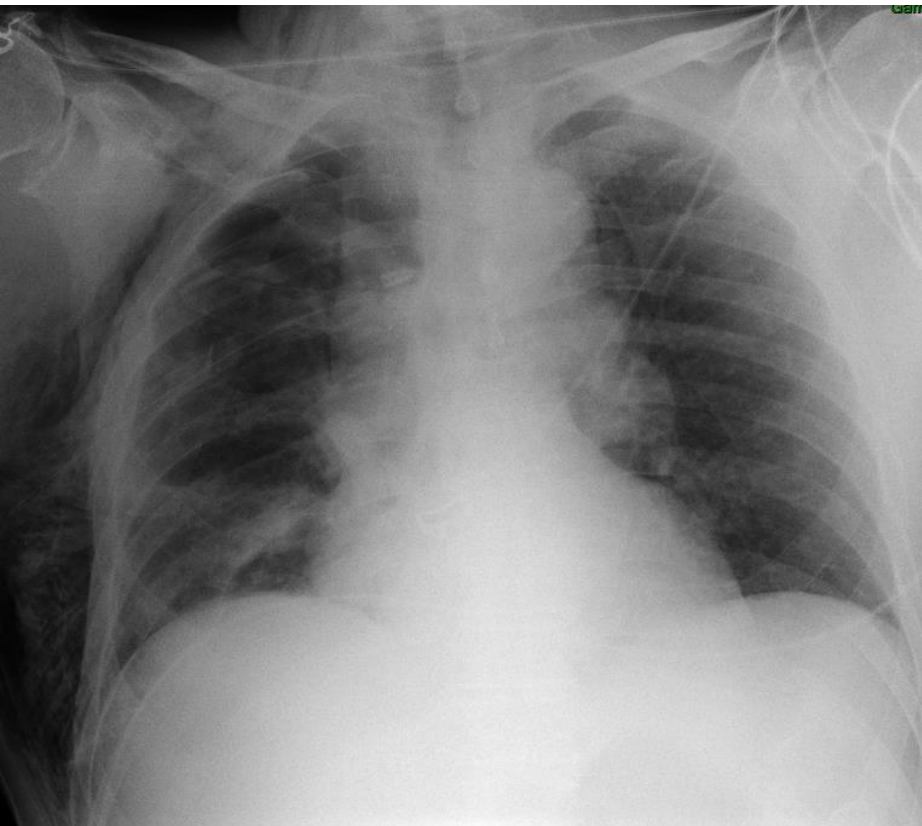
Drains pleuraux



Drain intrapariétal

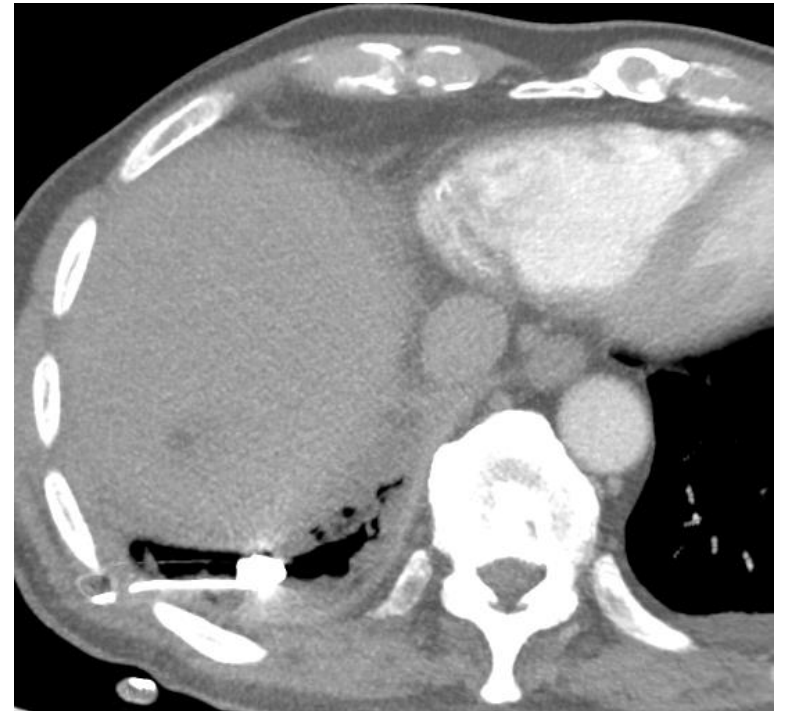
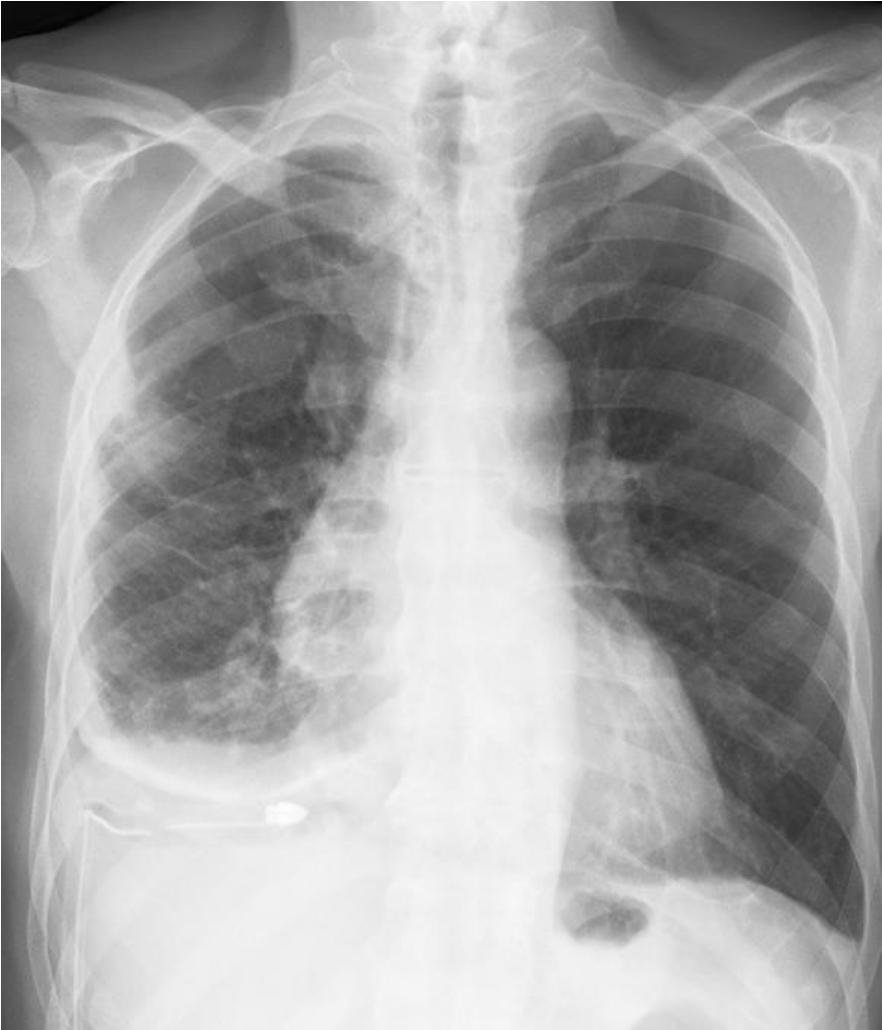

Drains pleuraux



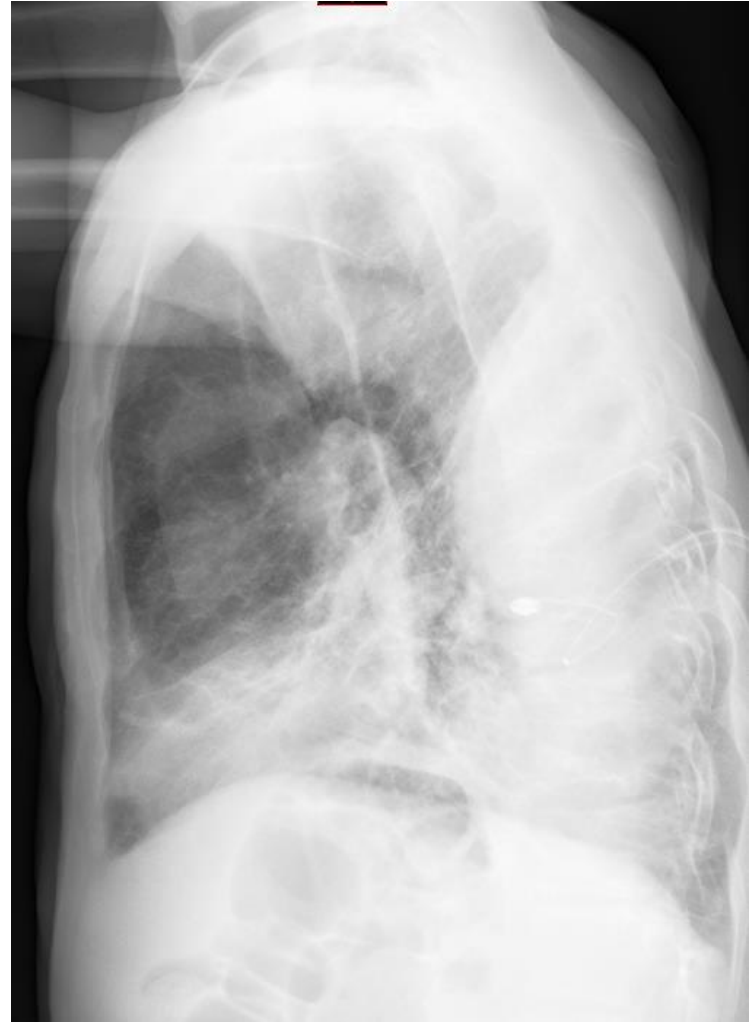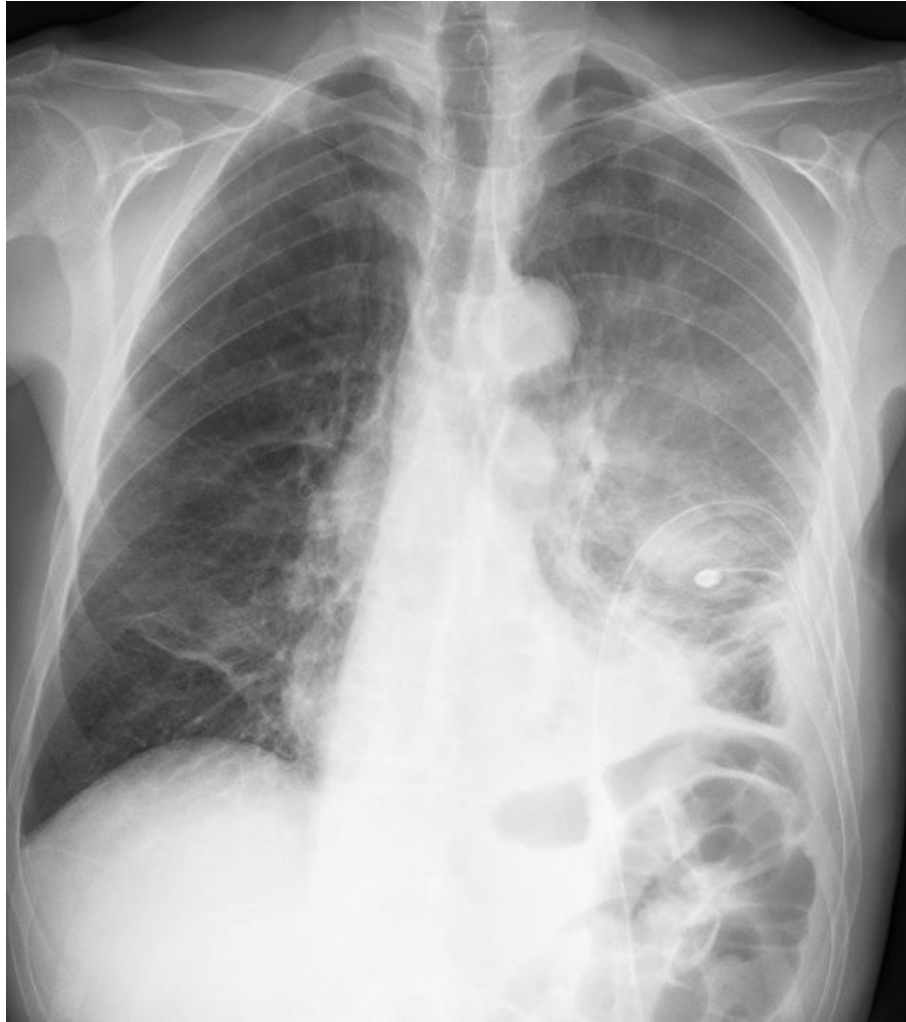Drain intraparenchymateux

Drains pleuraux

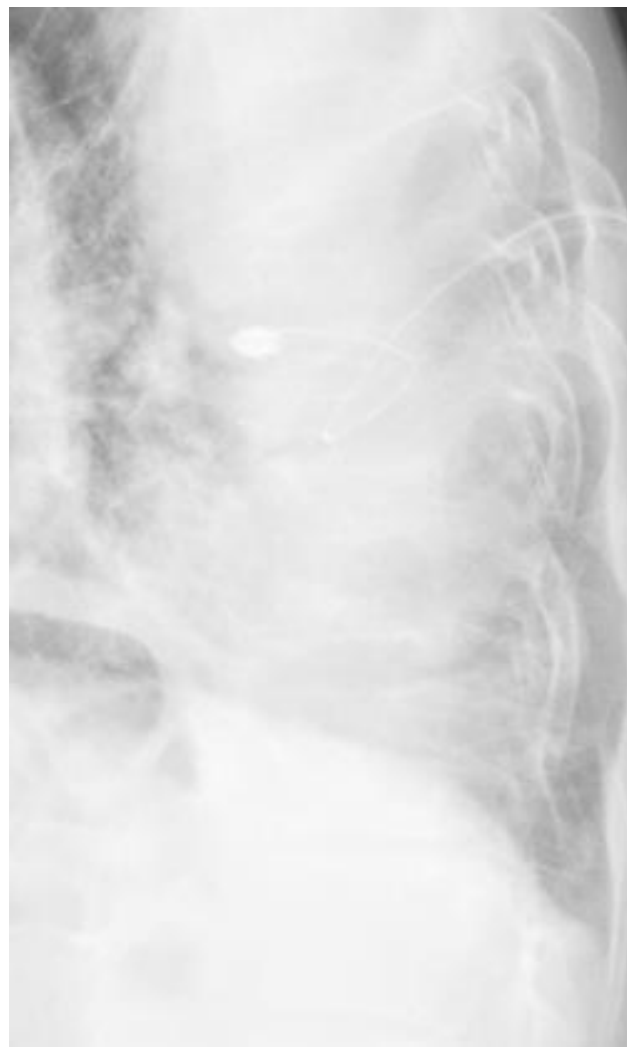
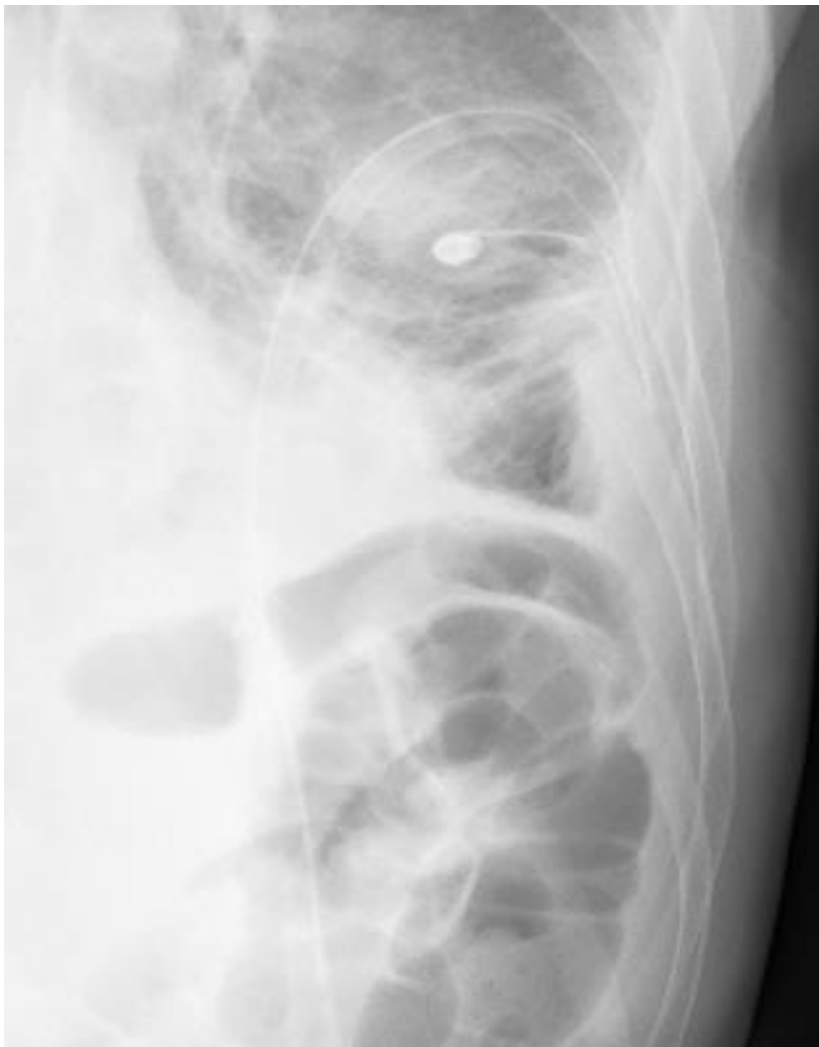
Trou proximal dans la paroi

Drains pleuraux



Drains pleuraux



Plicature